

# Four Human Cases of *Diphyllobothrium latum* Infection

Hee-Jung Choi<sup>1</sup>, Junghye Lee<sup>2</sup> and Hyun-Jong Yang<sup>2,\*</sup>

<sup>1</sup>Department of Internal Medicine, <sup>2</sup>Department of Parasitology and Ewha Medical Research Institute, Ewha Womans University School of Medicine, Seoul 158-710, Korea

**Abstract:** *Diphyllobothrium latum* infections in 4 young Korean men detected from 2008 to 2012 are presented. Three were diagnosed based on spontaneously discharged strobila of the adult worm in their feces, and 1 case was diagnosed by finding the worm at colonoscopy examination in a local clinic. The morphologic characteristics of the gravid proglottid and eggs were consistent with *D. latum*. All patients were treated with praziquantel 15 mg/kg, and follow-up stool examinations were done at 2 months after the medication. The main clinical complaints were intermittent gastrointestinal troubles such as indigestion, abdominal distension, and spontaneous discharge of tapeworm's segments in their feces. The most probable source of infection was the flesh of salmon or trout according to a patient's past history. These are the 45th to 48th recorded cases diagnosed by the adult worm in the Republic of Korea since 1971.

**Key words:** *Diphyllobothrium latum*, human case, praziquantel, salmon, trout

## INTRODUCTION

*Diphyllobothrium latum* is one of the longest intestinal tapeworms in humans and has numerous reservoir hosts, such as dogs, cats, foxes, and other wild canines [1]. In the past, the first case of *D. latum* infection was reported in 1919 by the recovery of eggs in 2 patient's feces living in Jinju, a southern area of Korea [2]. *D. latum* infection diagnosed by adult tapeworm recovery was reported for the first time in 1971 [3]. The rapid change of life quality the Republic of Korea with the increased consumption of expensive raw fish is suggested to be a factor for an increase in *D. latum* infections in young ages. A total of 41 cases have been diagnosed by the adult worm from 1971 to 2007 [4], and additional 3 cases diagnosed by colonoscopy were reported from 2007 to 2011 [5-7]. Herein, we report 4 cases of *D. latum* infection as 45th to 48th case in the Republic of Korea.

## CASE RECORD

Three (Cases 1-3 in Table 1) of the 4 men visited our hospi-

tal with a whitish segment of a tapeworm (Fig. 1A) that were recovered in the feces in the morning. In their past history, they were living healthy in Seoul, without any recent travel history to a foreign country. They reported infrequent consumptions of salmon and trout in raw side dishes. They have intermittent abdominal discomforts, including indigestion and abdominal distension, and experienced discharge of a 30 cm to 3.0 m whitish living tapeworm proglottids (Table 1). The eggs (Fig. 1B) from the proglottids and the rosette form uterine tubules (Fig. 1C) seen in the proglottids were morphologically consistent with *D. latum*. Blood biochemical analysis and serological analysis were not done.

The remaining 1 (Case 4 in Table 1) man visited a local clinic with a lower abdominal discomfort and underwent a colonoscopy to rule out lower intestinal lesions. The physician found some movable whitish living segments of a tapeworm in the sigmoid colon and took out the worm by a forcep (Fig. 1D). After cutting some length of the strobila, it was seen that the remaining part of the worm entered deeply to the upper part of the colon. The length of the specimen obtained was around 40, and the patient needed a light sedation due to the nervousness of seeing a long tapeworm collected from his body. He was living in Bundang-gu, near Seoul and had no health problems and no travel history to a foreign country within the past several months. One of his favorite foods was the trout and salmon in raw dishes with drinking liquor. Blood biochemical analysis and serological analysis were not done.

•Received 27 February 2012, revised 28 March 2012, accepted 29 March 2012.

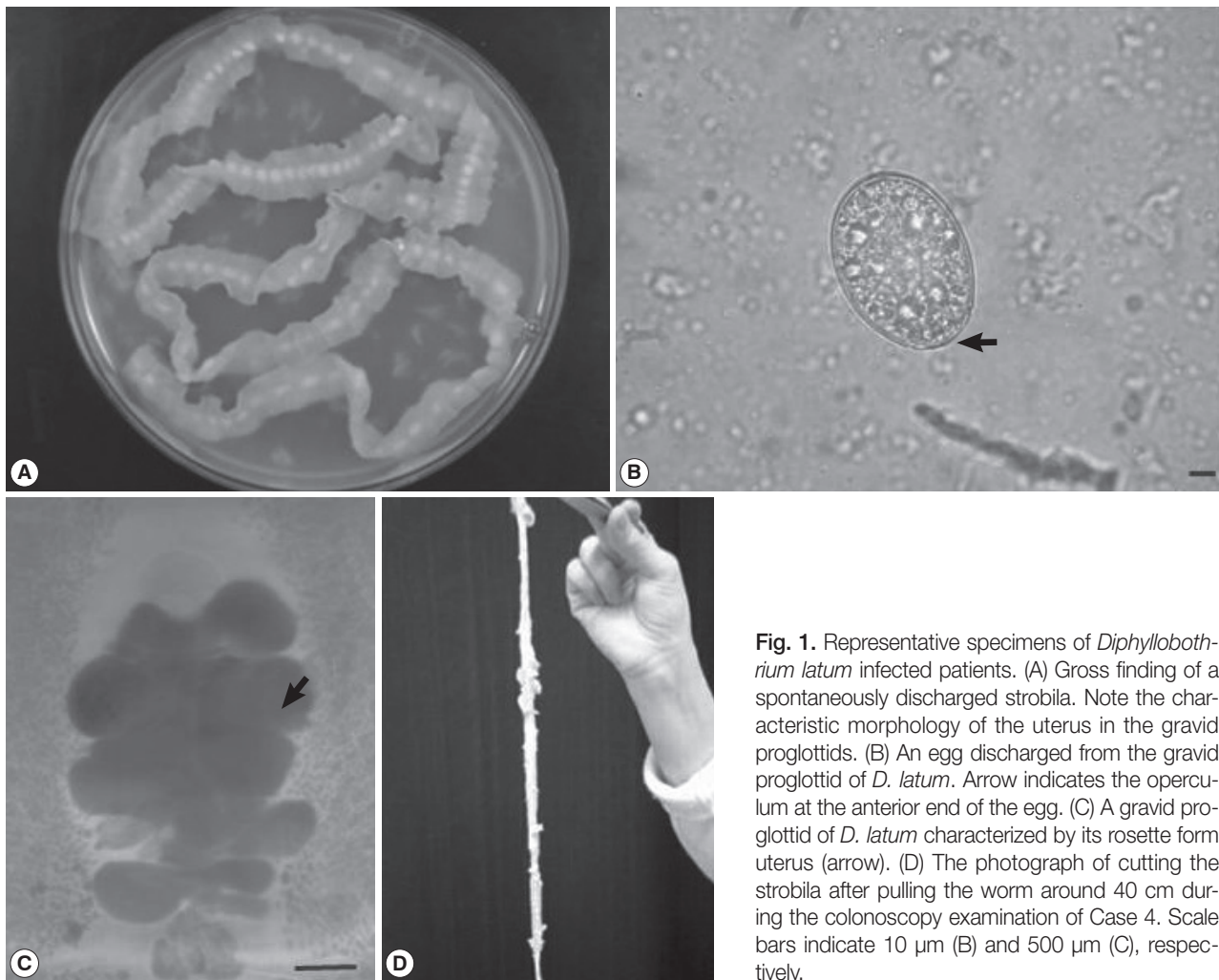
\*Corresponding author (parayang@ewha.ac.kr)

© 2012, Korean Society for Parasitology

This is an Open Access article distributed under the terms of the Creative Commons Attribution Non-Commercial License (<http://creativecommons.org/licenses/by-nc/3.0>) which permits unrestricted non-commercial use, distribution, and reproduction in any medium, provided the original work is properly cited.

**Table 1.** Summary of 4 *D. latum* cases in this report (2008-2012)

Case No.	Admission date	Sex	Age	Worm collection	Worm number/size	Suspected source of infection
1	Mar-08	Male	17	Passaged proglottids	Single/≥3 m	Salmon
2	May-08	Male	22	Passaged proglottids	Single/≥30 cm	Salmon, trout
3	Dec-08	Male	18	Passaged proglottids	Single/≥30 cm	Salmon
4	Feb-12	Male	35	Colonoscopy	Single/≥50 cm	Salmon, trout



**Fig. 1.** Representative specimens of *Diphyllobothrium latum* infected patients. (A) Gross finding of a spontaneously discharged strobila. Note the characteristic morphology of the uterus in the gravid proglottid of *D. latum*. (B) An egg discharged from the gravid proglottid of *D. latum*. Arrow indicates the operculum at the anterior end of the egg. (C) A gravid proglottid of *D. latum* characterized by its rosette form uterus (arrow). (D) The photograph of cutting the strobila after pulling the worm around 40 cm during the colonoscopy examination of Case 4. Scale bars indicate 10 μm (B) and 500 μm (C), respectively.

The specimens from the patients were brought to our laboratory and identified as *D. latum* according to the rosette-shaped uterus with 4-5 times piled-up uterine loops of the gravid proglottid (Fig. 1C) and also by its characteristic eggs (Fig. 1B). The worms were creamy-white without scolices. Some proglottids were fixed with 10% formalin under a pressure of a glass slide and stained with acetocarmine for morphological observations. The size of a proglottid averaged 8.3 × 3.1 mm in a fresh specimen. The eggs collected from the dissected proglottids were oval and brown in color with an operculum at the anterior end

(average 60 × 40 μm, Fig. 1B).

All patients were treated with praziquantel at a single oral dose of 15 mg/kg, and there was no evidence of recurrent *D. latum* infection during the following 2 months.

## DISCUSSION

The authors speculate that there were many cases of *D. latum* infection unreported in the Republic of Korea [8] since the first report of an adult *D. latum* infection in 1971 [3]. Lee et al.

[4] reviewed a total of 43 cases which included both cases of *D. latum* and *D. latum* parvum type infections [9], however, 3 of the 43 cases were not adult worm-proven cases.

In this study, the age and sex distribution of the patients revealed that all 4 cases were males aged 17-35 years, who were comparably somewhat younger than 30-49 years of all reported cases in the previous reports [4]. Korean men tend to drink alcoholic beverages with raw fish as a side dish more frequently than women, and this distinctive cultural trend seems to be attributable for the higher number of *D. latum* cases reported in Korean men. With regard to the residence of the cases, 3 patients were living in Seoul and 1 in the Seoul metropolitan area (Bundang-gu) (data not shown).

Although severe abdominal pain may have occurred [8], the major symptoms of all *D. latum* cases in our study were minor gastrointestinal troubles such as abdominal pain and abdominal distension. Although previously a 3-worm infected case was reported in the Republic of Korea [10], all 4 cases in this study had a single worm infection (Table 1). Case 2 had the longest discharged worm around 3.0 m (Table 1). The eggs were 60 × 40 μm in their average size. In the diagnosis of *D. latum* infection, stool examinations for eggs or strobilae are useful; however, colonoscopy has become one of the recently available and useful methods in some cases [5-7,11]. As shown in Case 4 of this study, colonoscopy was a useful diagnostic tool for detecting *D. latum* infection, and possibly the incidental detection rate of *D. latum* infection may increase because nowadays colonoscopy became a common and routine health check-up procedure for the Korean people.

In our *D. latum* cases, praziquantel was used in a single oral dose of 15 mg/kg. Since 1971, several medications such as atabrine [3], niclosamide, and bithionol [12] were used for *D. latum* infection. However, nowadays, praziquantel is used as the drug of choice, and there had been no treatment failure cases among the 43 cases reported in Korea [4]. In this study, no further sign of infection has been shown during the following 2 months after the chemotherapy. Human *D. latum* infection is known to be contracted by eating raw or uncooked fish [13]. Regarding the kinds of the fish hosts, freshwater species such as the pikes, burbot, trouts, salmons, and perches have been reported [1]. In Korea, human-infecting salmonid fish such as salmons, mullets, and trouts seem to be commonly consumed by the people [4].

Molecular speciation was not tried on the 4 worms in this study. It is of note that most pseudophyllidean tapeworms

found in the Korean patients would be *Diphyllobothrium nihonkaiense* based on their nucleotide sequences [14]. However, this point should be further investigated, and adoption of the name *D. nihonkaiense* is deferred until sufficient data are published.

Recently, Korean people frequently came into contact with mass media advertisement on the introduction of raw fish restaurants and raw fish festivals organized by the local governments. Furthermore, younger generations tend to visit these places more actively and to have more chance to be infected with *D. latum* just like the cases presented in this study. This factor may contribute to an increase in the incidence of *D. latum* infections in Korea.

## ACKNOWLEDGMENTS

The authors thank Dr. Dong-Ha Shin of Samsung Surgical Clinic in Bundang-gu for his kind transfer of the specimens and also thank Mr. Je-Young Ryu for his technical assistances.

## REFERENCES

1. Beaver PC, Jung RC, Cupp EW. Clinical Parasitology. 9th ed. Philadelphia, USA. Lea & Febiger. 1984, p 544-547.
2. Kojima R, Ko T. Researches on intestinal parasites of Koreans in South Keisho-Do. Especially on the distribution of liver flukes. J Chosen Med Ass 1919; 26: 42-86 (in Japanese).
3. Cho SY, Seo BS, Ahn JH. One case report of *Diphyllobothrium latum* infection in Korea. Seoul J Med 1971; 12: 157-163.
4. Lee EB, Song JH, Park NS, Kang BK, Lee HS, Han YJ, Kim HJ, Shin EH, Chai JY. A case of *Diphyllobothrium latum* infection with a brief review of diphyllobothriasis in the Republic of Korea. Korean J Parasitol 2007; 45: 219-223.
5. Byun TJ, Han DS, Ahn SB, Cho HS, Eun CS, Ryu JS, Oh YH. Multiple colonic aphthoid ulcers caused by *Diphyllobothrium latum* infection. Endoscopy 2009; 41: E181-E182.
6. Kim JH, Lee JH. Images in clinical medicine. *Diphyllobothrium latum* during colonoscopy. N Engl J Med 2010; 362: e40.
7. Park SC, Keum B, Jeon YT, Chun HJ. *Diphyllobothrium latum* accidentally detected by colonoscopy. Dig Liver Dis 2011; 43: 664.
8. Kim TH, Kim HK, Lee YS, Choi DH, Kang SH, Jeong SJ, Park TI, Kim IT. A case of *Diphyllobothrium latum* infection in a patient with abdominal pain. Korean J Gastroenterol 2007; 50: 384-387 (in Korean).
9. Lee SH, Chai JY, Seo M, Kook J, Huh S, Ryang YS, Ahn YK. Two rare cases of *Diphyllobothrium latum* parvum type infection in Korea. Korean J Parasitol 1994; 32: 117-120.
10. Lee SH, Chai JY, Hong ST, Sohn WM, Huh S, Cheong EH, Kang SB. Seven cases of *Diphyllobothrium latum* infection. Korean J Par-

- asitol 1989; 27: 213-216.
11. Iizuka H, Kakizaki S, Onozato Y. Diagnostic value of colonoscopy in intestinal *Diphyllobothrium latum* infection. Clin Gastroenterol Hepatol 2009; 7: e62-e63.
  12. Lee SH, Seo BS, Chai JY, Hong ST, Hong SJ, Cho SY. Five cases of *Diphyllobothrium latum* infection. Korean J Parasitol 1983; 21: 150-156.
  13. Salminen K. The effect of household smoking on the infectiveness of *Diphyllobothrium latum* from fish to man. Acta Vet Scand 1970; 11: 228-235.
  14. Jeon HK, Kim KH, Huh S, Chai JY, Min DY, Rim HJ, Eom KS. Morphologic and genetic identification of *Diphyllobothrium nihonkaiense* in Korea. Korean J Parasitol 2009; 47: 369-375.