

## Spinal Cord Stimulation for Refractory Angina Pectoris -A Case Report-

Department of Anesthesiology and Pain Medicine, Chonnam National University Medical School, Gwangju, Korea

Seong Heon Lee, MD, Hye Jin Jeong, MD, Sin Ho Jeong, MD, Hyung Gon Lee, MD,  
Jeong Il Choi, MD, Myung Ha Yoon, MD, and Woong Mo Kim, MD

Refractory angina pectoris is defined as angina refractory to optimal medical treatment and standard coronary revascularization procedures. Despite recent therapeutic advances, patients with refractory angina pectoris are not adequately treated. Spinal cord stimulation is a minimally invasive and reversible technique which utilizes electrical neuromodulation by means of an electrode implanted in the epidural space. It has been reported to be an effective and safe treatment for refractory angina pectoris. We report a case of spinal cord stimulation which has effectively relieved chest pain due to coronary artery disease in a 40-year-old man. This is the first report of spinal cord stimulation for treatment of refractory angina pectoris in South Korea. (Korean J Pain 2012; 25: 121-125)

### Key Words:

chest pain, coronary artery disease, refractory angina pectoris, spinal cord stimulation.

As the development of coronary revascularization and medication management have led to an improved survival rate following coronary events in the last few decades, it seems likely that the number of patients who remain severely disabled due to refractory angina will increase.

Refractory angina pectoris is a chronic condition characterized by the presence of severe chest pain, caused by coronary artery disease (CAD), which cannot be relieved by coronary intervention, coronary artery bypass grafting, and optimal medical treatment [1]. This limits the physical activity of patients and leads to more frequent hospital admissions. Spinal cord stimulation (SCS) is an electrical neuromodulation therapy, and it appears to be an effective

and safe treatment option for this specific group of patients [2-7].

This is the first report of spinal cord stimulation used to treat angina pectoris in South Korea.

### CASE REPORT

A 40-year-old man was admitted to the emergency department due to severe chest pain. He complained of persistent tightness in the left anterior chest. An emergent coronary angiogram (CAG) revealed total occlusion of the proximal left anterior descending coronary artery (LAD). Percutaneous coronary intervention with stent implantation

Received November 9, 2011. Revised December 5, 2011. Accepted December 6, 2011.

Correspondence to: Woong Mo Kim, MD

Department of Anesthesiology and Pain Medicine, Chonnam National University Medical School, 5, Hak-dong, Dong-gu, Gwangju 501-757, Korea  
Tel: +82-62-220-6893, Fax: +82-62-232-6294, E-mail: kimwm@jnu.ac.kr

© This is an open-access article distributed under the terms of the Creative Commons Attribution Non-Commercial License (<http://creativecommons.org/licenses/by-nc/3.0/>), which permits unrestricted non-commercial use, distribution, and reproduction in any medium, provided the original work is properly cited.

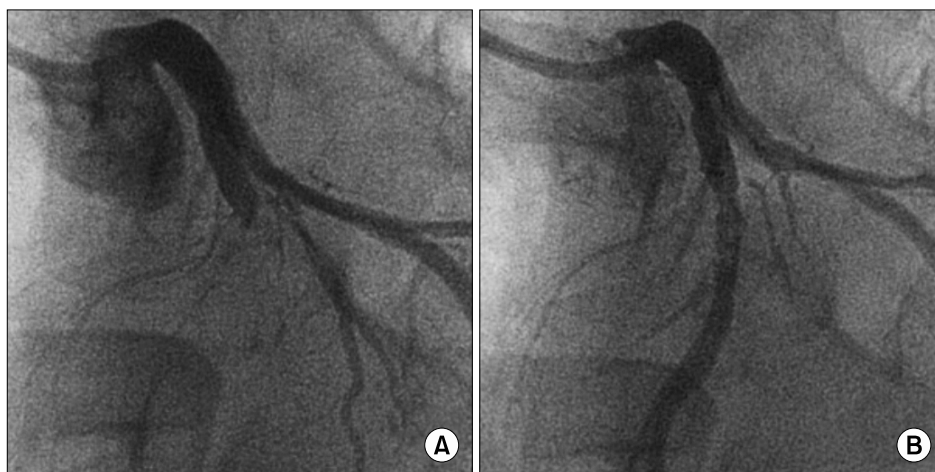Copyright © The Korean Pain Society, 2012

in the LAD successfully restored coronary blood flow and completely relieved his chest pain (Fig. 1). Five days later, the patient began to complain of left anterior chest discomfort, which gradually worsened over the next two weeks. Although the cardiologists again performed a detailed evaluation of cardiac function, there were no changes in the electrocardiogram and cardiac enzymes and no in-stent restenosis or *de novo* lesions seen on the CAG. Over the next year, the patient visited the emergency department and admitted several times due to his relentless chest pain, thus the total days of hospitalization was about half a year. Multiple cardiac evaluations were performed to elucidate the cause of the angina. Another stent was implanted in the obtuse marginal branch of the left circumflex artery for intermediate stenosis. Ergonovine-induced spasm in the right coronary artery was detected on another angiography, and the cardiologists added a calcium channel blocker to the patient's medications. However, these additional interventions did not improve his symptoms. Adequate results could not be obtained on an exercise electrocardiogram, due to the patient's poor exercise tolerance. Echocardiography showed persistent ischemic cardiomyopathy with moderate left ventricular dysfunction. A follow-up coronary angiogram showed patent previously stented arteries and no significant stenosis in other arteries.

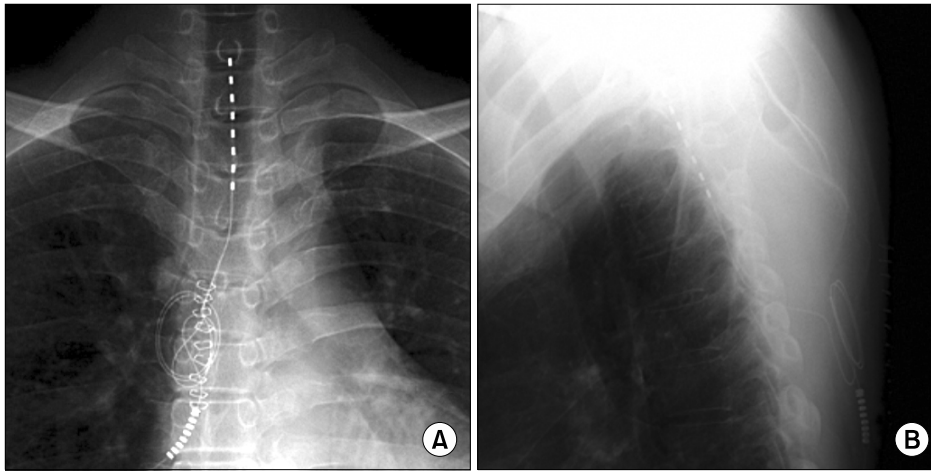
When the patient was referred to the pain clinic, he was experiencing paroxysmal deep anterior chest pain 2 or 3 times a day. The pain was of a squeezing and pressing nature, 7 to 8 on a numeric rating scale (NRS, 0 = no pain, 10 = maximum pain), and was not relieved by sublingual nitroglycerine. For several months, while the patient was

prescribed oral morphine 90 mg, gabapentin 1,800 mg, and nortriptyline 20 mg per day, we tried various procedures to control his pain, such as stellate ganglion block, percutaneous thoracic sympathetic neurotomy using thermal radiofrequency, epidural morphine injection, and intravenous ketamine infusion. These techniques all had only temporary efficacy. Finally, despite a continuous epidural infusion of morphine, his paroxysmal angina was worsening, rising to 8 to 9 on the NRS.

After careful discussion with the patient and his family, they agreed to a trial of SCS. The patient was taken to the operating room, monitored, and placed in the prone position. Anesthesia was accomplished by local anesthetic infiltration. A 15-gauge Tuohy needle was inserted in the T4-5 interlaminar space under fluoroscopic guidance. The epidural space was identified using a loss-of-resistance technique. An Octad lead 3778 (Medtronic Inc., Minneapolis, Minnesota, USA) was inserted through the needle and advanced under fluoroscopic guidance until the tip lay at the C7-T1 intervertebral disc level (Fig. 2). The stimulation parameters were pulse width of 270  $\mu$ s, amplitude of 2.0 mA, and frequency of 50 Hz. During the 10 days of trial stimulation, the intensity and frequency of the patient's chest pain was reduced by 60-70% without epidural infusion of morphine. Therefore, a permanent pulse generator (RestoreUltra™, Medtronic Inc., Minneapolis, Minnesota, USA) was implanted into the subcutaneous space of the right lower quadrant of the abdomen. The patient's chest pain decreased to 2 to 3 on the NRS, and he was satisfied with a treatment regimen of SCS and oral morphine 90 mg, gabapentin 1,800 mg, and nortriptyline 20 mg per day.



**Fig. 1.** Coronary angiogram (CAG) before and after percutaneous coronary intervention (PCI). (A) CAG shows total occlusion of the proximal left anterior descending coronary artery. (B) After the PCI, successful reperfusion was obtained.



**Fig. 2.** Chest radiographs showing an octad electrode. The tip of the electrode is located in the C7-T1 epidural space, slightly left of the center. (A) Anteroposterior view. (B) Lateral view.

Although the doses of medication did not decrease, the improvement in the patient's clinical symptoms persisted at the follow-up evaluation performed 1 year after surgery.

## DISCUSSION

Nowadays, most CAD patients can be adequately treated with revascularization and anti-anginal medications. However, some patients are still refractory to these treatments, or are poor candidates for percutaneous intervention, surgical revascularization, or additional procedures [1]. A few patients with significant intermittent angina demonstrate normal coronaries on angiography. The latter condition is referred to as "microvascular angina" or "cardiac syndrome X," and is characterized by typical exercise-triggered chest pain with ST-segment depression on exercise electrocardiogram [8]. Patients with refractory angina pose treatment dilemmas for the cardiac treatment team, and are not adequately treated. Treatment options that have emerged for refractory angina pectoris include thoracic epidural injection, stellate ganglion blockade, enhanced external counterpulsation, percutaneous myocardial laser revascularization, transcutaneous electric nerve stimulation, and SCS [1,9].

Neuromodulation, such as SCS, can be defined as electrical or chemical modification of the nervous system that changes the actual or perceived neurotransmission and response to a stimulus or condition. SCS is a minimally invasive technique in which electrodes are implanted in the epidural space to stimulate the dorsal columns of the spinal cord by passing an electric current. Since the late 1960s

[10], SCS has been increasingly used in a variety of chronic neurogenic pain conditions, as understanding of the mechanisms of SCS has increased and its techniques and equipment have been refined [11-13].

Since the first report of SCS as a treatment for angina was published in 1987, a large number of subsequent clinical trials and systematic reviews have demonstrated the clinical efficacy of SCS in angina pectoris in producing an anti-ischemic effect, symptomatic relief, and improvements in functional status and quality of life [4-6,14]. A recent meta-analysis revealed similar outcomes and lower healthcare costs with SCS as compared to coronary artery bypass grafting and percutaneous myocardial laser revascularization for the treatment of refractory angina [7]. Thus, SCS has been recommended by American College of Cardiology and American Heart Association guidelines (class IIb) [15], and the European Society of Cardiology Joint Study Group on the treatment of refractory angina (therapeutic alternative 1) [1].

The basic background of SCS was the gate control theory that stimulation of A-beta fibers modulates the dorsal horn gate and therefore reduces the nociceptive input from the periphery [16]. However, further research suggests that other mechanisms may play a more significant role. Potential explanations for the anti-anginal and anti-ischemic effects of SCS include direct pain blocking, reduced oxygen consumption, decreased sympathetic tone, redistribution of myocardial blood flow from non-ischemic to ischemic areas, possible improved coronary microcirculatory blood flow, possible increase in beta-endorphin levels, and modulation of intracardiac neurons [14,17,18].

ST segment monitoring has demonstrated a reduction in the total number and duration of ischemic episodes in SCS patients [19]. Nevertheless, SCS remains underused, possibly due to its only partially understood mechanism of action, as well as the rapid development of transluminal revascularization procedures. The reluctance to employ SCS for refractory angina may also result from the fear that this technique would only treat pain without affecting ischemia, thus concealing acute myocardial infarction. However, it has been reported that SCS does not mask the pain of myocardial ischemia as a warning signal for infarction [19,20].

In the case discussed here, although the patient had normal coronary arteries on CAG after revascularization, his angina was persistent and aggravated. Cardiologists decided that additional coronary intervention was not necessary for reducing his angina. After the patient's referral to the pain clinic, we tried various treatment options for refractory angina pectoris. However, none of the methods we tried prevented the progression of his pain. Finally, we recommended SCS to the patient. SCS did not completely eliminate his angina, but it successfully reduced his pain and medication requirements.

In conclusion, patients with refractory angina pectoris suffer from severe symptoms and impaired activities of daily living. Spinal cord stimulation could allow them to have reduced pain and improved quality of life. This case might provide the impetus for increased consideration of SCS as a therapeutic modality in this patient group in Korea.

## REFERENCES

- Mannheimer C, Camici P, Chester MR, Collins A, DeJongste M, Eliasson T, et al. The problem of chronic refractory angina; report from the ESC Joint Study Group on the Treatment of Refractory Angina. *Eur Heart J* 2002; 23: 355–70.
- André P, Yu W, Gersbach P, Gillberg L, Pehrsson K, Hardy I, et al. Long-term effects of spinal cord stimulation on angina symptoms and quality of life in patients with refractory angina pectoris—results from the European Angina Registry Link Study (EARL). *Heart* 2010; 96: 1132–6.
- Yu W, Maru F, Edner M, Hellström K, Kahan T, Persson H. Spinal cord stimulation for refractory angina pectoris: a retrospective analysis of efficacy and cost-benefit. *Coron Artery Dis* 2004; 15: 31–7.
- de Jongste MJ, Hautvast RW, Hillege HL, Lie KI. Efficacy of spinal cord stimulation as adjuvant therapy for intractable angina pectoris: a prospective, randomized clinical study. Working Group on Neurocardiology. *J Am Coll Cardiol* 1994; 23: 1592–7.
- Eddicks S, Maier-Hauff K, Schenk M, Müller A, Baumann G, Theres H. Thoracic spinal cord stimulation improves functional status and relieves symptoms in patients with refractory angina pectoris: the first placebo-controlled randomised study. *Heart* 2007; 93: 585–90.
- Börjesson M, André P, Lundberg D, Mannheimer C. Spinal cord stimulation in severe angina pectoris—a systematic review based on the Swedish Council on Technology assessment in health care report on long-standing pain. *Pain* 2008; 140: 501–8.
- Taylor RS, De Vries J, Buchser E, Dejongste MJ. Spinal cord stimulation in the treatment of refractory angina: systematic review and meta-analysis of randomised controlled trials. *BMC Cardiovasc Disord* 2009; 9: 13.
- Lanza GA. Cardiac syndrome X: a critical overview and future perspectives. *Heart* 2007; 93: 159–66.
- Svorkdal N. Treatment of inoperable coronary disease and refractory angina: spinal stimulators, epidurals, gene therapy, transmymocardial laser, and counterpulsation. *Semin Cardiothorac Vasc Anesth* 2004; 8: 43–58.
- Shealy CN, Mortimer JT, Reswick JB. Electrical inhibition of pain by stimulation of the dorsal columns: preliminary clinical report. *Anesth Analg* 1967; 46: 489–91.
- Ubbink DT, Vermeulen H. Spinal cord stimulation for critical leg ischemia: a review of effectiveness and optimal patient selection. *J Pain Symptom Manage* 2006; 31: S30–5.
- Kemler MA, Barendse GA, van Kleef M, de Vet HC, Rijks CP, Furnée CA, et al. Spinal cord stimulation in patients with chronic reflex sympathetic dystrophy. *N Engl J Med* 2000; 343: 618–24.
- Kumar K, Taylor RS, Jacques L, Eldabe S, Meglio M, Molet J, et al. Spinal cord stimulation versus conventional medical management for neuropathic pain: a multicentre randomised controlled trial in patients with failed back surgery syndrome. *Pain* 2007; 132: 179–88.
- Mannheimer C, Eliasson T, Andersson B, Bergh CH, Augustinsson LE, Emanuelsson H, et al. Effects of spinal cord stimulation in angina pectoris induced by pacing and possible mechanisms of action. *BMJ* 1993; 307: 477–80.
- Gibbons RJ, Abrams J, Chatterjee K, Daley J, Deedwania PC, Douglas JS, et al. ACC/AHA 2002 guideline update for the management of patients with chronic stable angina—summary article: a report of the American College of Cardiology/American Heart Association Task Force on Practice Guidelines (Committee on the Management of Patients With Chronic Stable Angina). *Circulation* 2003; 107: 149–58.
- Melzack R, Wall PD. Pain mechanisms: a new theory.

- Science 1965; 150: 971–9.
17. Diedrichs H, Zobel C, Theissen P, Weber M, Koulousakis A, Schicha H, et al. Symptomatic relief precedes improvement of myocardial blood flow in patients under spinal cord stimulation. *Curr Control Trials Cardiovasc Med* 2005; 6: 7.
  18. Foreman RD, Linderoth B, Ardell JL, Barron KW, Chandler MJ, Hull SS Jr, et al. Modulation of intrinsic cardiac neurons by spinal cord stimulation: implications for its therapeutic use in angina pectoris. *Cardiovasc Res* 2000; 47: 367–75.
  19. Sanderson JE, Ibrahim B, Waterhouse D, Palmer RB. Spinal electrical stimulation for intractable angina—long-term clinical outcome and safety. *Eur Heart J* 1994; 15: 810–4.
  20. Andersen C, Hole P, Oxhøj H. Does pain relief with spinal cord stimulation for angina conceal myocardial infarction? *Br Heart J* 1994; 71: 419–21.