

## Clinical Article

# Unruptured Supraclinoid Internal Carotid Artery Aneurysm Surgery : Superciliary Keyhole Approach versus Pterional Approach

Donguk Shin, M.D., Jaechan Park, M.D.

Department of Neurosurgery, Cardiocerebrovascular Center, Kyungpook National University, Daegu, Korea

**Objective :** A superciliary keyhole approach is an attractive, minimally invasive surgical technique, yet the procedure is limited due to a small cranial opening. Nonetheless, an unruptured supraclinoid internal carotid artery (ICA) aneurysm can be an optimal surgical target of a superciliary approach as it is located in the center of the surgical view and field. Therefore, this study evaluated the feasibility and surgical outcomes of a superciliary keyhole approach for unruptured ICA aneurysms.

**Methods :** The authors report on a consecutive series of patients who underwent a superciliary approach for clipping unruptured ICA aneurysms between January 2007 and February 2012. The data were compared with a historical control group who underwent a pterional approach between January 2003 and December 2006.

**Results :** In the superciliary group, a total of 71 aneurysms were successfully clipped without a residual sac in 70 patients with a mean age of 57 years (range, 37-75 years). The maximum diameter of the aneurysms ranged from 4 mm to 14 mm (mean±standard deviation, 6.6±2.3 mm). No direct mortality or permanent morbidity was related to the surgery. The superciliary approach demonstrated statistically significant advantages over the pterional approach, including a shorter operative duration (mean, 100 min), no intraoperative blood transfusions, and no postoperative epidural hemorrhages.

**Conclusion :** A superciliary keyhole approach provides a sufficient surgical corridor to clip most unruptured supraclinoid ICA aneurysms in a minimally invasive manner.

**Key Words :** Cerebral aneurysm · Internal carotid artery · Minimal surgical procedure · Treatment outcome.

## INTRODUCTION

The advent of endovascular treatment for intracranial aneurysms has led to a sharp decline in surgical treatment due to the less invasive nature of endovascular procedures despite their low durability. Meanwhile, this has also provoked neurovascular surgeons to develop minimally invasive surgical techniques<sup>2-4,13,16,23,24,26,27,29,30,32</sup>.

A superciliary keyhole approach is an attractive, minimally invasive surgical technique for managing unruptured aneurysms, however, the limitations include narrow viewing angles and coaxial control of the surgical microinstruments through a small cranial opening. In particular, such limitations have an increased impact for complex aneurysms in hidden corners of the surgical

field, as in the case of anterior communicating artery (ACoA) and middle cerebral artery (MCA) aneurysms. Notwithstanding, an unruptured supraclinoid internal carotid artery (ICA) aneurysm is an optimal surgical target for a superciliary approach as it is located in the center of the surgical view and field<sup>26</sup>.

Accordingly, the present authors applied a superciliary keyhole approach, instead of a pterional approach, for consecutive unruptured supraclinoid ICA aneurysms, and evaluated its feasibility and the surgical outcomes.

## MATERIALS AND METHODS

### Patients

For unruptured supraclinoid ICA aneurysms, the authors ap-

• Received : April 7, 2012 • Revised : September 7, 2012 • Accepted : October 4, 2012

• Address for reprints : Jaechan Park, M.D.

Department of Neurosurgery, Kyungpook National University Hospital, 130 Dongdeok-ro, Jung-gu, Daegu 700-721, Korea  
Tel : +82-53-420-5656, Fax : +82-53-423-0504, E-mail : jparkmd@hotmail.com

• This is an Open Access article distributed under the terms of the Creative Commons Attribution Non-Commercial License (<http://creativecommons.org/licenses/by-nc/3.0>) which permits unrestricted non-commercial use, distribution, and reproduction in any medium, provided the original work is properly cited.

plied a pterional approach as the standard surgical technique until 2006, and then used a superciliary keyhole approach for consecutive patients from 2007. Information was obtained retrospectively for such patients between January 2003 and February 2012.

Medical records and operative reports were reviewed to obtain relevant clinical information, and radiological data accessed using an electronic picture archiving and communication system. The operative duration, intraoperative blood transfusion, adequacy of the aneurysm clip placement, postoperative morbidity and mortality, and occurrence of a postoperative epidural hemorrhage (EDH) and cerebral infarction were all assessed and compared between the superciliary and pterional groups. Plus, the adequacy of the aneurysm clip placement was verified using postoperative three-dimensional CT angiography (3DCTA).

### Operative technique of superciliary approach

The patient is placed in a supine position with the head rotated contralaterally 20-30 degrees and slightly extended. A superciliary incision is made in the upper half of the eyebrow, starting from the midpupillary line to behind the frontal process of the zygomatic bone, approximately 3.5 cm in length. In the lateral part of the incision, the temporalis muscle is cut 1 cm, exposing a site for a frontobasal lateral burrhole posterior to the temporal line. A small (2 cm by 2.5 cm) craniotomy is performed above the orbital ridge using a high-speed drill with a footplate attachment after making a single frontobasal lateral burrhole posterior to the temporal line (Fig. 1A). The inner edge of the craniotomy above the orbital rim is drilled and beveled, while the frontal floor prominences are flattened. The dura is then opened in a curved fashion with its base toward the orbital rim, providing a 2 to 2.5-cm opening (Fig. 1B). With the

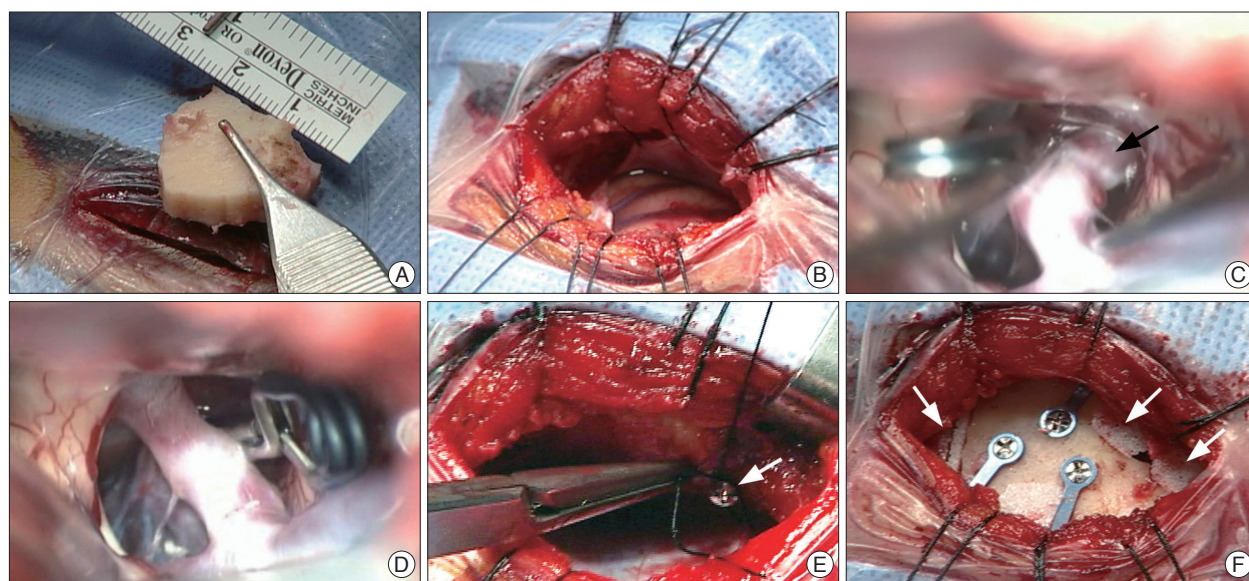
use of an operating microscope, a narrow brain spatula is slid over the frontal lobe along the sphenoid ridge trajectory until the optic nerve and carotid cisterns are encountered, at which point the cisterns are opened to achieve brain relaxation and frontal lobe retraction. Limited opening of the sylvian fissure medially facilitates more frontal lobe retraction without temporal lobe traction, allowing visualization up to the carotid bifurcation. The carotid cistern is opened along the superior aspect of the ICA, and the distal posterior communicating artery (PCoA) is identified in the opticocarotid triangle. The arachnoid adherent to the ICA is rolled laterally to expose the aneurysm base and the origins of the PCoA and anterior choroidal artery (AChA). A temporary clip is applied to the proximal ICA.

For a PCoA aneurysm, once the proximal and distal aspects of the aneurysm neck are defined, a permanent clip is advanced between the PCoA and the AChA (Fig. 1C). A straight or gently curved clip is invariably used for a PCoA aneurysm.

For an AChA aneurysm, determining the exact origin of the AChA is crucial and can only be confirmed by rigorous visual scrutiny under high microscopic magnification. A straight clip is then applied across the base of the aneurysm perpendicular to the axis of the ICA, while tilting laterally away from the origin of the AChA (Fig. 1D). The clip blades are then inspected to ensure that the aneurysm is completely occluded, the PCoA and AChA are not compromised, and the oculomotor nerve is free.

To improve the safety and efficacy of the surgery, several intraoperative techniques can also be used, including intraoperative microvascular doppler, intraoperative angiography, indocyanine green angiography, and neurophysiological monitoring using a motor-evoked potential.

After completing the intracranial procedure, the dural incision is sutured watertight and any epidural bleeding meticu-



**Fig. 1.** Intraoperative photographs showing superciliary keyhole approach for supraclinoid internal carotid artery aneurysms. A : Supraorbital mini-craniotomy. B : 2.5-cm dural opening. C : Posterior communicating artery aneurysm (arrow). D : Clipped posterior communicating artery aneurysm. E : Anchor screw (arrow) for dural tenting sutures. F : Porous high-density polyethylene implants (arrows) filling burrhole and bone gaps.

lously controlled. An anchor screw technique is frequently used for placing the dural tenting sutures (Fig. 1E)<sup>25</sup>, and no suction drain is routinely used in the operative wound.

The bone flap is fixed in place using low profile, titanium plates and screws. Thereafter, the bone defects, including the burrhole and bone gaps around the bone flap, are filled with porous high-density polyethylene implants (Fig. 1F)<sup>6</sup>. The pericranium, temporalis and frontalis muscles, and subcutaneous layer are then closed layer by layer. Finally, the skin is closed using a subdermal resorbable suture and reinforced with sterile tape.

### Statistical analysis

The statistical analyses were performed with the aid of an SPSS package (version 14 for Windows; SPSS, Inc., Chicago, IL, USA). To compare the superciliary and pterional groups, a t-test was used for the numerical data, such as the patient age, maximum diameter of the aneurysms, and operative duration, whereas a  $\chi^2$ -test was used for the categorical data, such as the occurrence of a postoperative EDH, an intraoperative blood transfusion, and significant postoperative morbidity. The results were considered significant for probability values less than 0.05.

## RESULTS

### Patient population

For an unruptured supraclinoid ICA aneurysm, a pterional approach was applied to 21 patients with an age ranging from 37 to 75 years (mean±standard deviation, 56.8±10.7 yr), while a superciliary keyhole approach was applied to 70 patients with an age ranging from 33 to 65 years (mean±standard deviation, 49.7±9.2 yr).

**Table 1.** Angiographic characteristics of unruptured supraclinoid internal carotid artery aneurysms that were clipped via superciliary and pterional approaches

Characteristics	Superciliary approach (n=71)	Pterional approach (n=23)
Aneurysm location, no. (%)		
PCoA	45 (63.4)	16 (69.6)
AChA	17 (23.9)	4 (17.4)
ICA bifurcation	5 (7.0)	3 (13.0)
Dorsal wall	4 (5.6)	0 (0)
Maximum aneurysm diameter		
Mean±SD, mm	6.6±2.3	6.1±2.2
Range, mm	4-14	4-12
<5 mm, no. (%)	17 (23.9)	6 (26.1)
5-10 mm, no. (%)	44 (62.0)	15 (65.2)
>10 mm, no. (%)	10 (14.1)	2 (8.7)
Maximum diameter of aneurysm neck		
Mean±SD, mm	4.1±1.1	3.7±0.6
Range, mm	2-8	3-5
>4 mm, no. (%)	34 (47.9)	8 (34.8)

AChA : anterior choroidal artery, ICA : internal carotid artery, PCoA : posterior communicating artery, SD : standard deviation

### Angiographic characteristics

The angiographic characteristics of the supraclinoid ICA aneurysms are summarized in Table 1. Seventy patients in the superciliary group underwent surgical clipping for 71 supraclinoid ICA aneurysms, while 21 patients in the pterional group underwent clipping for 23 ICA aneurysms. In both groups, the location order of incidence for the aneurysms was the PCoA origin, AChA origin, ICA bifurcation, and dorsal wall of the ICA.

The maximum diameter of the aneurysms (n=71) in the superciliary group ranged from 4 mm to 14 mm (mean±standard deviation, 6.6±2.3 mm), which was comparable to that in the pterional group (n=107, range, 4-12 mm; mean±standard deviation, 6.1±2.2 mm). Meanwhile, the maximum diameter of the aneurysm neck in the superciliary group (4.1±1.1 mm; range, 2-8 mm) was also comparable to that of the pterional group (3.7±0.6 mm; range, 3-5 mm).

### Technical feasibility

The surgical goal of applying a clip to the aneurysm neck was achieved for all the patients in both groups. Also, in both groups, the surgical procedures were performed under microscopic view without endoscopic assistance.

The state of the clip placement, assessed using postoperative 3DCTA, was complete without a residual sac for all the patients in both groups. Repeated 3DCTA conducted 1 year after surgery revealed no aneurysm recurrence.

In the superciliary group, usage of proper microsurgical instruments including rigid or flexible tubular aneurysm clip appliers that are useful through a narrow space and most common locations of supraclinoid ICA aneurysms, lateral or posterolateral aspect of the ICA, enabled aneurysm clipping to be performed adequately.

A rare posterior location, large size, and complex configuration of the aneurysms require large cranial opening using a pterional approach rather than a small keyhole approach, although endoscopic assistance can extend indications of the keyhole approach.

### Operative duration and intraoperative blood transfusion

For the superciliary group (n=70), the mean±standard deviation operative duration from the skin incision to the skin closure was 99.9 min±17.7 min (range, 70-160 min). In contrast, the operative duration for the pterional group (n=21) was significantly longer at 166.7 min±29.4 min (range, 120-240 min) (p=0.000).

Furthermore, the operative duration for the superciliary group during the learning curve between 2006 and 2007

(n=15) was slightly longer at 124.7 min±21.0 min (range, 100-160 min). Whereas, beyond the learning curve between 2008 and 2012 (n=55), the operative duration was reduced to 93.1 min±7.9 min (range, 70-110 min).

No blood transfusion was required intraoperatively for the superciliary group. However, 4 (19.0%) patients in the pterional group received a transfusion of 1-2 units of red blood cells during surgery to achieve a hemoglobin level of 10 g/dL and hematocrit level of 30%. As such, a statistically significant between-group difference was observed ( $p=0.000$ ).

No cerebrospinal fluid leakage or wound infections were observed in either group.

### Postoperative mortality and morbidity

Neither the superciliary group nor the pterional group experienced any direct mortality or permanent morbidity resulting from the surgery. However, one patient in the superciliary group suffered from postoperative transient AChA syndrome.

A 63-year-old woman with an incidental AChA aneurysm who underwent surgical clipping via a superciliary approach awoke from surgery with contralateral hemiplegia. An immediate re-operation and clip repositioning enabled the patient to recover completely in 6 hours. The duration of the AChA occlusion (from the initial clip placement to the clip repositioning) was only 70 minutes.

For the superciliary group, the postoperative CT scans revealed no EDHs larger than 10 mL. However, for the pterional group, 4 (19.0%) of the 21 patients developed postoperative EDHs >10 mL, representing a statistically significant higher incidence ( $p=0.000$ ). The volume of the EDHs in the 4 patients ranged from 15 mL to 50 mL (mean±standard deviation, 23.8±17.5 mL), where a patient with the 50-mL EDH was symptomatic and required reoperation to remove the EDH.

### Aneurysms presenting with oculomotor nerve palsy

Fifteen patients in the superciliary group and three patients in the pterional group presented with complete or incomplete oculomotor nerve palsy (ONP). All patients except one in the superciliary group showed complete resolution of the ONP within 6 months. Plus, since the patient with incomplete resolution revealed a large thrombotic aneurysm compressing and adherent to the oculomotor nerve, the superciliary keyhole approach was not considered the cause of the incomplete resolution of the ONP. The cases of 13 patients with ONP from the current superciliary group have already been described in detail in a previous report by the authors<sup>26</sup>.

## DISCUSSION

The present study verified excellent surgical outcomes when using a superciliary approach for unruptured supraclinoid ICA aneurysms with a maximum diameter up to 12 mm in patients aged 37 to 75 years. Successful aneurysm clipping was achieved

in all patients with minimal surgical morbidity and less invasiveness than a pterional approach.

While the keyhole concept of a superciliary approach is already used for tumorous and vascular lesions of the anterior cranial fossa and parasellar region<sup>27,30</sup>, it is still not a popular neurosurgical practice due to certain significant shortcomings. As the size of the cranial opening is small, this reduces the intraoperative light and sight, and limits the maneuverability of the surgical microinstruments, necessitating almost coaxial control of the microinstruments. Also, the supraorbital location of the mini-craniotomy only allows a subfrontal approach, whereas a pterional craniotomy with modifications allows pterional, subfrontal, and multidirectional approaches.

Yet, despite such shortcomings, this study highlighted the usefulness of a superciliary approach for unruptured ICA aneurysms. In the case of supraclinoid ICA aneurysms, they are located in the center of the small and deep surgical field, however, ACoA and MCA aneurysms are situated in the corner of the surgical field, which requires more technical development and a longer learning period. Moreover, most ICA aneurysms can be clipped using a subfrontal unidirectional perspective. Thus, a 90-minute simple and straightforward procedure can provide satisfactory treatment of the aneurysms.

When considering the meta-analysis by Raaymakers et al.<sup>28</sup>, which reported 0.8% mortality and 1.9% permanent major morbidity related to the surgical clipping of non-giant anterior circulation aneurysms, the zero-percent major complication rate in the current series underscores the safety of the superciliary approach for unruptured ICA aneurysms.

When comparing the less invasive superciliary approach with a pterional approach, the present study found statistically significant advantages to the superciliary approach in terms of a shorter operative duration, no intraoperative blood transfusion, and no occurrence of postoperative EDHs. Le Roux et al.<sup>14</sup> previously reported a 13.2% incidence of blood transfusions during conventional surgery for unruptured aneurysms. Plus, postoperative EDHs after conventional craniotomies are not uncommon and can be a serious complication. In a report by Fukamachi et al.<sup>5</sup>, EDHs occurred in 46.8% of patients after conventional aneurysm surgery, where 2.1% required reoperation to remove the hemorrhage.

Avoiding damage to the temporalis muscle is another advantage of a superciliary approach, whereas a pterional craniotomy causes temporalis atrophy and varying degrees of pseudoankylosis of the temporomandibular joint<sup>7,9,22</sup>. Kawaguchi et al.<sup>10</sup> reported limited mouth opening in 20% of patients 1 month after a pterional craniotomy. Conversely, palsy of the frontalis muscle is a potential problem with a superciliary approach. Although, in a previous report by the current authors, only 5.9% of patients were found to experience long-lasting palsy for more than 6 months following a superciliary procedure<sup>27</sup>.

Thus, this minimally invasive superciliary approach offers many convincing benefits over a conventional pterional craniot-

omy, including a smaller incision without scalp shaving, much smaller craniotomy reducing the risk of a postoperative EDH, reduced trauma to the body reducing the postoperative pain, shorter operative duration, reduced blood loss, reduced risk of infection in the operative field, faster postoperative recovery, and earlier return to normal life.

Furthermore, the reduced patient repulsion to surgical treatment due to the minimally invasive nature of the superciliary surgical procedure also has a positive effect on the decision of treatment modality, surgical or endovascular. Surgical treatment can invariably be an easier option for cases that are technically challenging or not amenable to endovascular therapy, for example, cases involving difficult navigation of the microcatheter due to acute angles or the morphology of the aneurysm, very small aneurysms (defined as <3 mm in diameter), wide-necked aneurysms necessitating stent-assisted or balloon-assisted technology, and aneurysms with an arterial branch incorporated into the sac<sup>1,8,11,12,15,17-21</sup>.

The selection of an appropriate surgical approach, superciliary keyhole approach versus pterional approach, depends on the surgeon's discretion and experience. Aneurysm complexities difficult to handle via a superciliary keyhole approach may include large size, previous coiling, adherence of the AChA, and atherosclerotic calcification<sup>31</sup>.

Although the current study is limited based on a retrospective review of a case series from a single institution, it is the first large case series highlighting unruptured supraclinoid ICA aneurysms as an optimal application for a superciliary approach. The current case series covers various aneurysms arising in the supraclinoid ICA, including PCoA origin, AChA origin, ICA bifurcation, and the dorsal wall of the ICA, although aneurysms originating from the ventral wall of the ICA have not been included due to their rarity.

## CONCLUSION

A superciliary keyhole approach provides a sufficient surgical corridor to clip most unruptured supraclinoid ICA aneurysms with advantages of a short operative duration, small operative wound without blood transfusion, and no postoperative epidural hemorrhages.

### • Acknowledgements

This study was supported by a grant from the Korea Healthcare Technology R & D Project, Ministry of Health & Welfare, Republic of Korea (A100870).

### References

1. Birknes JK, Hwang SK, Pandey AS, Cockroft K, Dyer AM, Benitez RP, et al. : Feasibility and limitations of endovascular coil embolization of anterior communicating artery aneurysms : morphological considerations. *Neurosurgery* 59 : 43-52; discussion 43-52, 2006
2. Brydon HL, Akil H, Ushewokunze S, Dhir JS, Taha A, Ahmed A : Supraorbital microcraniotomy for acute aneurysmal subarachnoid haemorrhage : results of first 50 cases. *Br J Neurosurg* 22 : 40-45, 2008

3. Chen L, Tian X, Zhang J, Huang Y, Chen E, Lan Q : Is eyebrow approach suitable for ruptured anterior circulation aneurysms on early stage : a prospective study at a single institute. *Acta Neurochir (Wien)* 151 : 781-784; discussion 784, 2009
4. Czirják S, Szeifert GT : Surgical experience with frontolateral keyhole craniotomy through a superciliary skin incision. *Neurosurgery* 48 : 145-149; discussion 149-150, 2001
5. Fukamachi A, Koizumi H, Nagaseki Y, Nukui H : Postoperative extradural hematomas : computed tomographic survey of 1105 intracranial operations. *Neurosurgery* 19 : 589-593, 1986
6. Goh DH, Kim GJ, Park J : Medpor craniotomy gap wedge designed to fill small bone defects along cranial bone flap. *J Korean Neurosurg Soc* 46 : 195-198, 2009
7. Hendler BH, Kreger TM, Goldman HW : Fibrous ankylosis of the mandible following frontotemporal craniotomy. Case report. *J Neurosurg* 55 : 836-837, 1981
8. Ioannidis I, Lalloo S, Corkill R, Kuker W, Byrne JV : Endovascular treatment of very small intracranial aneurysms. *J Neurosurg* 112 : 551-556, 2010
9. Kang DH, Park JC, Kim SO, Hamm IS : Intubation difficulty in patients with pseudoankylosis of temporo-mandibular joint after pterional craniotomy. *J Korean Neurosurg Soc* 36 : 166-167, 2004
10. Kawaguchi M, Sakamoto T, Furuya H, Ohnishi H, Karasawa J : Pseudo-ankylosis of the mandible after supratentorial craniotomy. *Anesth Analg* 83 : 731-734, 1996
11. Kim BM, Park SI, Kim DJ, Kim DI, Suh SH, Kwon TH, et al. : Endovascular coil embolization of aneurysms with a branch incorporated into the sac. *AJNR Am J Neuroradiol* 31 : 145-151, 2010
12. Koebbe CJ, Veznedaroglu E, Jabbour P, Rosenwasser RH : Endovascular management of intracranial aneurysms : current experience and future advances. *Neurosurgery* 59 : S93-S102; discussion S3-S13, 2006
13. Lan Q, Gong Z, Kang D, Zhang H, Qian Z, Chen J, et al. : Microsurgical experience with keyhole operations on intracranial aneurysms. *Surg Neurol* 66 Suppl 1 : S2-S9, 2006
14. Le Roux PD, Elliott JB, Winn HR : Blood transfusion during aneurysm surgery. *Neurosurgery* 49 : 1068-1074; discussion 1074-1075, 2001
15. Lubicz B, Lefranc F, Levivier M, Dewitte O, Pirotte B, Brotchi J, et al. : Endovascular treatment of intracranial aneurysms with a branch arising from the sac. *AJNR Am J Neuroradiol* 27 : 142-147, 2006
16. Mitchell P, Vindlacheruvu RR, Mahmood K, Ashpole RD, Grivas A, Mendelow AD : Supraorbital eyebrow minicraniotomy for anterior circulation aneurysms. *Surg Neurol* 63 : 47-51; discussion 51, 2005
17. Molyneux A, Kerr R, Stratton I, Sandercock P, Clarke M, Shrimpton J, et al. : International Subarachnoid Aneurysm Trial (ISAT) of neurosurgical clipping versus endovascular coiling in 2143 patients with ruptured intracranial aneurysms : a randomised trial. *Lancet* 360 : 1267-1274, 2002
18. Molyneux AJ, Kerr RS, Yu LM, Clarke M, Sneade M, Yarnold JA, et al. : International subarachnoid aneurysm trial (ISAT) of neurosurgical clipping versus endovascular coiling in 2143 patients with ruptured intracranial aneurysms : a randomised comparison of effects on survival, dependency, seizures, rebleeding, subgroups, and aneurysm occlusion. *Lancet* 366 : 809-817, 2005
19. Moret J, Pierot L, Boulin A, Castaings L, Rey A : Endovascular treatment of anterior communicating artery aneurysms using Guglielmi detachable coils. *Neuroradiology* 38 : 800-805, 1996
20. Murayama Y, Nien YL, Duckwiler G, Gobin YP, Jahan R, Frazee J, et al. : Guglielmi detachable coil embolization of cerebral aneurysms : 11 years' experience. *J Neurosurg* 98 : 959-966, 2003
21. Nelson PK, Sahlein D, Shapiro M, Becske T, Fitzsimmons BF, Huang P, et al. : Recent steps toward a reconstructive endovascular solution for the orphaned, complex-neck aneurysm. *Neurosurgery* 59 : S77-S92;

- discussion S3-S13, 2006
22. Nitzan DW, Azaz B, Constantini S : Severe limitation in mouth opening following transtemporal neurosurgical procedures : diagnosis, treatment, and prevention. *J Neurosurg* 76 : 623-625, 1992
  23. Paladino J, Mrak G, Miklič P, Jednacak H, Mihaljević D : The keyhole concept in aneurysm surgery--a comparative study : keyhole versus standard craniotomy. *Minim Invasive Neurosurg* 48 : 251-258, 2005
  24. Paladino J, Pirker N, Stimac D, Stern-Padovan R : Eyebrow keyhole approach in vascular neurosurgery. *Minim Invas Neurosurg* 41 : 200-203, 1998
  25. Park J : Self-drilling anchor screws for dural tenting sutures : technical note. *Surg Neurol* 72 : 175-176, 2009
  26. Park J, Kang DH, Chun BY : Superciliary keyhole surgery for unruptured posterior communicating artery aneurysms with oculomotor nerve palsy : maximizing symptomatic resolution and minimizing surgical invasiveness. *J Neurosurg* 115 : 700-706, 2011
  27. Park J, Woo H, Kang DH, Sung JK, Kim Y : Superciliary keyhole approach for small unruptured aneurysms in anterior cerebral circulation. *Neurosurgery* 68 : 300-309; discussion 309, 2011
  28. Raaymakers TW, Rinkel GJ, Limburg M, Algra A : Mortality and morbidity of surgery for unruptured intracranial aneurysms : a meta-analysis. *Stroke* 29 : 1531-1538, 1998
  29. Ramos-Zúñiga R, Velázquez H, Barajas MA, López R, Sánchez E, Trejo S : Trans-supraorbital approach to supratentorial aneurysms. *Neurosurgery* 51 : 125-130; discussion 130-131, 2002
  30. Reisch R, Perneczky A : Ten-year experience with the supraorbital subfrontal approach through an eyebrow skin incision. *Neurosurgery* 57 : 242-255; discussion 242-255, 2005
  31. Sanai N, Caldwell N, Englot DJ, Lawton MT : Advanced technical skills are required for microsurgical clipping of posterior communicating artery aneurysms in the endovascular era. *Neurosurgery* 71 : 285-294; discussion 294-295, 2012
  32. van Lindert E, Perneczky A, Fries G, Pierangeli E : The supraorbital keyhole approach to supratentorial aneurysms : concept and technique. *Surg Neurol* 49 : 481-489; discussion 489-490, 1998