

Case Report

Treatment with Epidural Blood Patch for Iatrogenic Intracranial Hypotension after Spine Surgery

Jaekook Kim, M.D., Sunyeul Lee, M.D., Youngkwon Ko, M.D., Ph.D., Wonhyung Lee, M.D., Ph.D.

Department of Anesthesia and Pain Medicine, Chungnam National University Hospital, Daejeon, Korea

Intracranial hypotension syndrome typically occurs spontaneously or iatrogenically. It can be associated with headache, drowsy mentality and intracranial hemorrhage. Iatrogenic intracranial hypotension can occur due to dural puncture, trauma and spine surgery. Treatment may include conservative therapy and operation. We report a case of a 54-year-old man who was successfully treated with epidural blood patches for intracranial hypotension due to cerebrospinal fluid (CSF) leakage into the lumbosacral area after spine surgery.

Key Words : Intracranial hypotension · Secondary · Epidural blood patch · Spine · Complication · Therapy.

INTRODUCTION

Intracranial hypotension syndrome (IHS) is characterized by a postural headache that is aggravated in the erect or sitting position and relieved in the supine position. It is often associated with one or more of the following symptoms : nausea, vomiting, dizziness, diplopia, photophobia, hearing impairment, neck stiffness, and blurred vision⁶⁾.

Acquired or secondary intracranial hypotension is less common but has been reported after spinal procedures such as lumbar discectomy and dural puncture for myelogram, spinal anesthesia. Incidental durotomy is a frequent complication of lumbar spinal surgery. Treatment options range from conservative therapy to surgical correction.

We report a case of a 54-year-old man who was successfully treated with epidural blood patches for intracranial hypotension due to CSF leakage into the lumbosacral area after L4-5 discectomy.

CASE REPORT

A 54-year-old male admitted to the ER complaining of headache from 13 days ago. It did not occur when lying down but became intensely squeezing around the occipital area within 10 seconds after being seated or standing. Symptoms were accom-

panied by nausea and vomiting. Visual analog score (VAS) was 8 at standing. Past medical history was insignificant other than undergoing L4-5 laminectomy and discectomy at a local hospital 15 days ago. Physical examination did not display any neurologic findings such as neck stiffness and laboratory results as well as brain MRI findings were not remarkable. Under the strong impression of intracranial hypotension, he admitted to neurology department and underwent conservative therapy including absolute bed rest (ABR) and hydration. A MR myelogram was performed, showing a pseudomeningocele accompanied by large CSF leakage in the lumbosacral area (Fig. 1).

Because resolution of symptoms was unsatisfactory, an epidural blood patch was placed on the sixth admission day. After placing the patient in a prone position, a 22 gage Touhy needle was inserted through the L5-S1 epidural space through a paraspinous method. After confirming the epidural space by the loss-of-resistance technique, a dye was injected to confirm the epidural space with the C-Arm. Then the epidural patch was placed with 12ml of autologous blood.

VAS one day after intervention was reduced from 6 to 2. After three days of ABR following the procedure, the patient practiced changing positions by sitting. Symptoms were not aggravated when standing up. Five days after the procedure, the patient did not complain of any symptoms (VAS 0). Follow up MR myelogram showed decreased pseudomeningocele size caused by CSF

• Received : May 2, 2012 • Revised : July 25, 2012 • Accepted : August 29, 2012

• Address for reprints : Youngkwon Ko, M.D., Ph.D.

Department of Anesthesia and Pain Medicine, Chungnam National University Hospital, 282 Munhwa-ro, Jung-gu, Daejeon 301-721, Korea
Tel : +82-42-280-7841, Fax : +82-42-280-7841, E-mail : annn8432@gmail.com

• This is an Open Access article distributed under the terms of the Creative Commons Attribution Non-Commercial License (<http://creativecommons.org/licenses/by-nc/3.0/>) which permits unrestricted non-commercial use, distribution, and reproduction in any medium, provided the original work is properly cited.

leakage (Fig. 2).

We decided to perform one more procedure of epidural patch placement because of the residual CSF leakage 6 days after the first intervention. A total of 10 mL autologous blood was injected, and the patient was discharged the next day. Follow up for six months confirmed no recurrence of symptoms (Fig. 3).

DISCUSSION

Intracranial hypotension syndrome can occur spontaneously. Acquired or secondary intracranial hypotension is less common but has been reported after spinal procedures. Guerin P et al. reported that the incidence of incidental durotomy during spine surgery was 3.84% in patients who underwent spinal surgery at a single spine unit⁵. In one study looking into medicolegal aspects of spine surgery, 146 malpractice cases were reviewed and incidental durotomy was second most frequent complication in such cases⁴. The study has shown that potentially serious problems such as pseudomeningocele, CSF fistula formation, meningitis and arachnoiditis with subsequent chronic pain are all related to dural tears and CSF leakage after spinal surgery.

Dural tears that occur during surgery can be treated with primary repair when recognized. Good long-term clinical results were noted in all patients with durotomy repaired at identification and are comparable to long-term results of patients undergoing similar surgical procedures but without durotomy. However, Cammisa et al.¹ reported the incidence of clinically significant durotomy occurred during surgery but not identified at the time was 0.28%, and patients had subsequent surgical repair of dural defects because of failure of conservative therapy. In one study which investigated incidental durotomy during spine surgery and its treatment, in addition to primary repair, drain, bed rest, hydration, antibiotics had been used for treatment by spine surgeon⁷. However to our knowledge, there have been no previous studies which compared the effects of epidural blood patch for the treatment of incidental durotomy with other treatments.

Epidural blood patch has been employed over the last five decades in the treatment of postdural puncture headache (PDPH) and has proven to be beneficial. The mechanism by which an epidural blood patch (EBP) relieves PDPH is not known. The “plug” theory for symptom resolution proposes that the blood injected during EBP forms a gelatinous plug, sealing the dural hole and preventing further CSF leak into the epidural space. In the absence of continued loss, regeneration of CSF restores CSF pressure and alleviates the headache³. The “pressure patch” hypothesis emphasizes the impact of injected blood or other fluid (crystalloid or colloid) on the pressure dynamics of the CNS. The injected fluid increases epidural pressure which, in turn, elevates subarachnoid CSF pressure by compressing the dura⁸.

The optimal volume of blood that must be injected is controversial but recommended volumes have increased over time. Crawford's initial experience using 6-15 mL produced a 30%

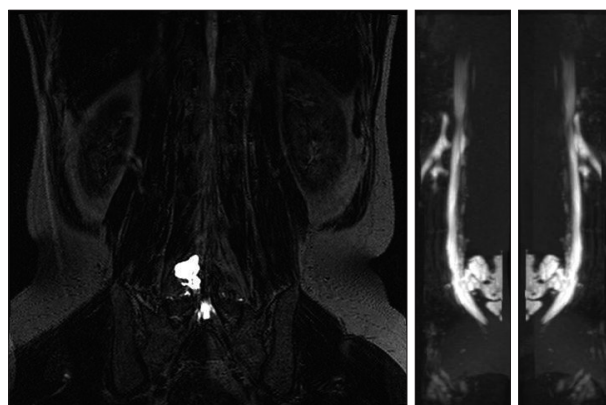


Fig. 1. Initial magnetic resonance myelogram shows the leakage of cerebrospinal fluid into right posterolateral spinal canal & paraspinal area from thecal sac in lumbosacral spine.

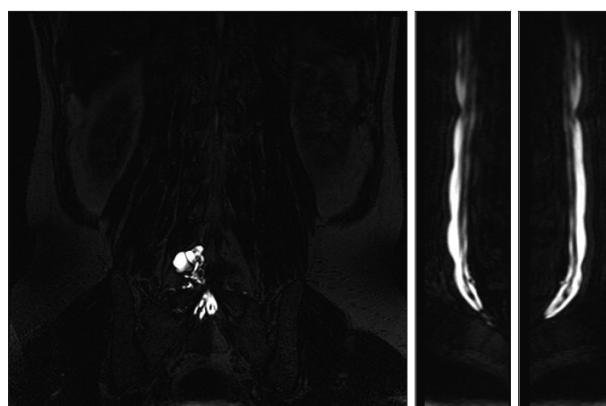


Fig. 2. Magnetic resonance myelogram after the first epidural blood patch showing markedly decreased size of pseudomeningocele.

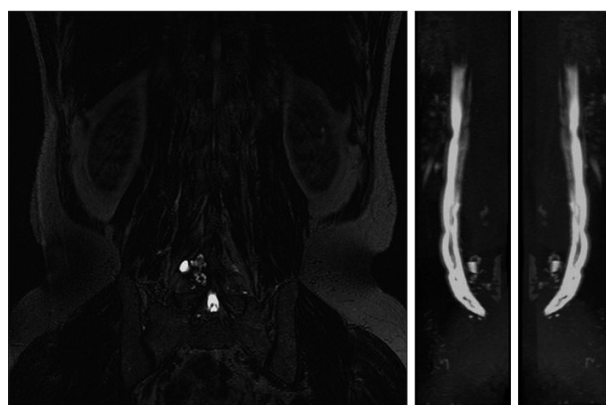


Fig. 3. Final follow-up magnetic resonance myelogram after two procedures of epidural blood patch.

failure rate while later experience with 20 mL produced a 96% success rate, so 20 mL became the recommended volume and has since become commonly cited as a “target volume” to enhance patch efficacy³. However, the effects of EBP in intracranial hypotension are mostly focused on post-dural puncture during CSF tapping or spontaneous intracranial hypotension. There are only few reports on EBP after incidental dural tear during spine surgery.

EBP has been shown to be effective in patients with spontaneous dural tear. Even patients with rather large amount of CSF leakage and patients with severe complications such as intracranial hematomas have been effectively treated with EBP, so we considered EPB for postoperative incidental durotomy due to such evidence. Two trials of EBP that relieved symptoms and improvement were also shown in cisternography. The effects of EBP in postoperative intracranial hypotension cannot be discussed after one successful clinical trial, but additional trials and studies can provide the basis of EPB treatment in such cases.

When incidental durotomy was recognized postoperatively, conservative therapy or surgical correction has been the therapeutic choice. Surgical correction can be considered when there is no response to conservative therapy. EBP is as less invasive therapeutic alternative. However, because there has been no report on indication for EBP according to the degree of dural injury or the size of pseudomeningocele, additional research is needed.

In our case, the patient underwent L4-5 spine surgery at a local orthopedic, but dural injury was not recognized at that time. After admitting to our hospital, he was diagnosed with intracranial hypotension caused by incidental durotomy during surgery. There was no significant resolution of symptoms after conservative therapy including the five days of bed rest and hydration. After two procedures of epidural blood patch, the patients became asymptomatic.

CONCLUSION

Epidural blood patch can be used as an effective treatment modality for CSF leakage after lumbar spine surgery.

References

1. Cammisa FP Jr, Girardi FP, Sangani PK, Parvataneni HK, Cadag S, Sandhu HS : Incidental durotomy in spine surgery. *Spine (Phila Pa 1976)* 25 : 2663-2667, 2000
2. Crawford JS : Experiences with epidural blood patch. *Anesthesia* 35 : 513-515, 1980
3. DiGiovanni AJ, Galbert MW, Wahle WM : Epidural injection of autologous blood for postlumbar-puncture headache. II. Additional clinical experiences and laboratory investigation. *Anesth Analg* 51 : 226-232, 1972
4. Goodkin R, Laska LL : Unintended "incidental" durotomy during surgery of the lumbar spine : medicolegal implications. *Surg Neurol* 43 : 4-12, 1995
5. Guerin P, El Fegoun AB, Obeid I, Gille O, Lelong L, Luc S, et al. : Incidental durotomy during spine surgery : incidence, management and complications. A retrospective review. *Injury* 43 : 397-401, 2012
6. Mokri B : Headaches caused by decreased intracranial pressure: diagnosis and management. *Curr Opin Neurol* 16 : 319-326, 2003
7. Tafazal SI, Sell PJ : Incidental durotomy in lumbar spine surgery : incidence and management. *Eur Spine J* 14 : 287-290, 2005
8. Usubiaga JE, Usubiaga LE, Brea LM, Goyena R : Effect of saline injections on epidural and subarachnoid space pressures and relation to postspinal anesthesia headache. *Anesth Analg* 46 : 293-296, 1967