

Measurements of simulated periodontal bone defects in inverted digital image and film-based radiograph: an in vitro study

Rafael Scaf de Molon, Juliana Aparecida Najarro Dearo Morais-Camillo, Celso Eduardo Sakakura*, Mauricio Goncalves Ferreira, Leonor Castro Monteiro Loffredo**, Gulnara Scaf

Department of Diagnosis and Surgery, Araraquara Dental School, Universidade Estadual Paulista, Sao Paulo, Brazil

*Barretos Dental School, Barretos Educational Foundation, Sao Paulo, Brazil

**Department of Social Dentistry, Araraquara Dental School, Universidade Estadual Paulista, Sao Paulo, Brazil

ABSTRACT

Purpose: This study was performed to compare the inverted digital images and film-based images of dry pig mandibles to measure the periodontal bone defect depth.

Materials and Methods: Forty 2-wall bone defects were made in the proximal region of the premolar in the dry pig mandibles. The digital and conventional radiographs were taken using a Schick sensor and Kodak F-speed intraoral film. Image manipulation (inversion) was performed using Adobe Photoshop 7.0 software. Four trained examiners made all of the radiographic measurements in millimeters a total of three times from the cemento-enamel junction to the most apical extension of the bone loss with both types of images: inverted digital and film. The measurements were also made in dry mandibles using a periodontal probe and digital caliper. The Student's t-test was used to compare the depth measurements obtained from the two types of images and direct visual measurement in the dry mandibles. A significance level of 0.05 for a 95% confidence interval was used for each comparison.

Results: There was a significant difference between depth measurements in the inverted digital images and direct visual measurements ($p > |t| = 0.0039$), with means of 6.29 mm (IC_{95%}:6.04-6.54) and 6.79 mm (IC_{95%}:6.45-7.11), respectively. There was a non-significant difference between the film-based radiographs and direct visual measurements ($p > |t| = 0.4950$), with means of 6.64 mm (IC_{95%}:6.40-6.89) and 6.79 mm (IC_{95%}:6.45-7.11), respectively.

Conclusion: The periodontal bone defect measurements in the inverted digital images were inferior to film-based radiographs, underestimating the amount of bone loss. (*Imaging Sci Dent* 2012; 42 : 243-7)

KEY WORDS: Digital Radiography, Dental; Radiographic Image Enhancement; Alveolar Bone Loss

Introduction

The use of digital radiography in dentistry is increasing, and it is an alternative to film-based images. Because radiographic images can be manipulated using inversion, brightness and contrast control, zooming, and embossed tools, digital radiography also offers the possibility in radiographic interpretation of improving the detection of lesions

as periodontal bone loss.¹⁻⁴

There have been studies that have evaluated periodontal bone loss using digital images and film-based radiographs, and there has been agreement among the results.⁵⁻⁸ However, two studies have found differences between direct digital images and film-based radiographs in relationship to bone-defect measurements, and the results have shown the superiority of the digital images over the film-based radiographs.^{5,6}

Of the types of manipulations performed on digital radiographic images, the most commonly used are brightness and contrast adjustments,⁹ and the examiners can adjust the images according to their preferences using dedicated

Received July 28, 2012; Revised August 28, 2012; Accepted September 11, 2012

Correspondence to : Dr. Rafael Scaf de Molon

Department of Diagnosis and Surgery, Araraquara Dental School, Universidade Estadual Paulista-UNESP; Rua Humaita, 1680; Araraquara, Sao Paulo 14801-903, Brazil

Tel) 55-16-31141247, Fax) 55-16-33016300, E-mail) molon.foar@yahoo.com.br

Copyright © 2012 by Korean Academy of Oral and Maxillofacial Radiology

This is an Open Access article distributed under the terms of the Creative Commons Attribution Non-Commercial License (<http://creativecommons.org/licenses/by-nc/3.0>) which permits unrestricted non-commercial use, distribution, and reproduction in any medium, provided the original work is properly cited.

Imaging Science in Dentistry • pISSN 2233-7822 eISSN 2233-7830

and non-dedicated programs.² Moreover, inverted digital images have been used for different dentistry procedures such as periodontal bone loss measurements³ and detection of the mandibular canal and mental foramen.² However, there has been a lack of studies that deal with periodontal bone defects measurements using inverted digital images and software for general applications such as Adobe Photoshop.

The aim of this study was to compare periodontal bone defect depth measurement by inverted digital images and film-based images in dry pig mandibles.

Materials and Methods

Forty 2-wall bone defects were created in 40 hemi-mandibles from domestic pigs (*Sus scrofa*) using slow-speed #4 round diamond burs (KG Sorensen, Agerskov, Denmark). The depth of the bone defect was randomly determined, and the bone defect width was created based on the diameter size of the bur. The defect was created on the mesial side of the first premolar in the apical direction. Part of the mesial wall and the buccal wall were removed; the lingual and distal walls were left intact. A chisel was used to refine the borders of the defects. A tiny mark was made at the cemento-enamel junction with a double-faced diamond disk to establish the upper border of the bone defect, and it was used as a reference point when taking the measurements.⁴

Image acquisition

Two periapical radiographs were taken of each defect using a direct digital system (CMOS Schick sensor, Schick Technologies Inc., Long Island, NY, USA) and F-speed film (Insight, Eastman-Kodak Co., Rochester, NY, USA). The characteristics of the original digital images were as follows: 40 µm pixel size, 900 × 641 pixels, 8 bits, and saved in tagged image file format (TIFF). There were a total of 80 images: 40 inverted direct digital images and 40 film-based images.

The radiographs were taken with the vertical long axis of the hemi-mandible fixed perpendicularly to the central ray and parallel to the sensor and film at a 40-cm focal spot-to-object distance. The geometric alignment between the sensor or film and the hemi-mandible was standardized using a fixing device. The dental X-ray unit (GE1000, General Electric Company, Wisconsin, USA) operated at 70 kVp and 10 mA. The exposure time for the digital images was 12 impulses and for the F-speed films it was 15

impulses. A 2-cm-thick wooden block was placed in front of the mandible in order to simulate the soft tissue.² The film-based radiographs were processed with a Dentix 9000 (Dentix, Elmsford, NY, USA). The digital images were saved and stored as TIFF files without compression (8 bits, with a resolution of 600 dpi, and a file size of about 700 KB) using computer software (CDR DICOM for Windows v. 3.5, Schick Technologies Inc., Long Island, NY, USA), and then the images were transferred to an image processing software (Adobe Photoshop 7.0, Adobe System Incorporated, San Jose, CA, USA). The Adobe Photoshop software was used to create the inverted digital images. The levels of brightness and contrast were adjusted according to the examiners' individual preferences.¹⁰

Bone-defect measurement

The depth measurements of the defects were performed by four examiners as previously described:⁴ one experienced radiologist, two graduate students, and one undergraduate student on two types of images as well as on the dry mandibles. Inter-examiner agreement was obtained using consensus during the measurements of the defects, which were carried out in three consecutive sessions.

The digital inverted images were displayed on a 17-inch extended graphics array (WXGA) color monitor with a resolution of 1440 × 900 lines from a laptop computer (Satellite P-25-S507, Toshiba, Taiwan). The bone-defect depth was measured as the distance in millimeters from the deepest part of the defect to the cemento-enamel junction; a tiny mark was used to facilitate the detection of the upper border of the bone defect using the ruler tool in Adobe Photoshop 7.0. Before measuring the defect depths in the digital images, all of the images were standardized according to a known length from the step wedge and the ruler tool in Adobe Photoshop 7.0 (Figs. 1A and B).

The digital and film-based images were interpreted under subdued lighting. A standard light box was used when reading the radiographs, and all extraneous light from the light box was blocked using black cardboard. The measurements in the film-based images were made using a digital caliper (Ultra-Call Mark III, Fowler, Geneva, Switzerland) from the reference point in the cemento-enamel junction to the base of the defect. Direct visual measurements of all of the vertical osseous defects in the dry pig mandibles were made using a periodontal probe (Williams Probe, Hu-Friedy, Chicago, IL, USA), as described in a previous paper.^{2,4} This measurement was considered the standard depth (Fig. 2).

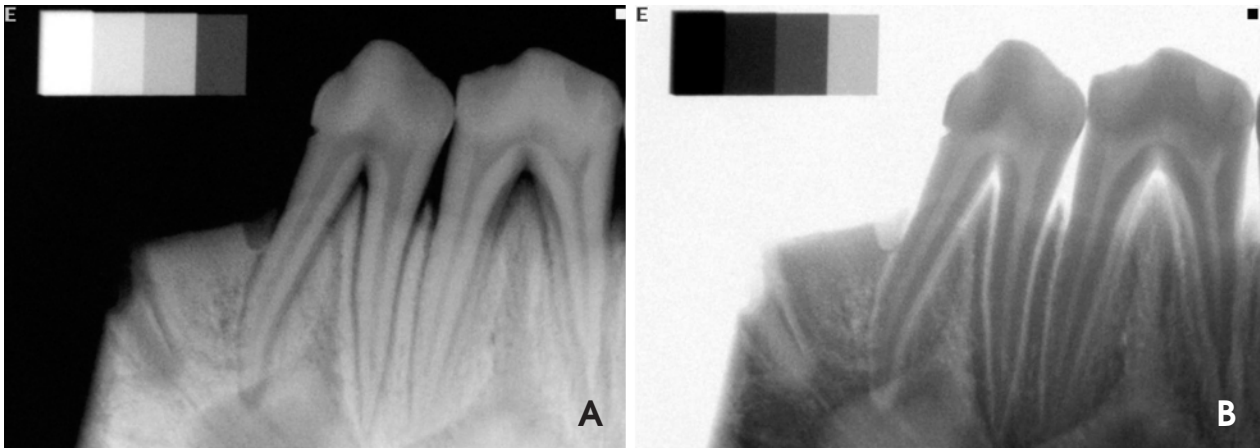


Fig. 1. A. Film-based image shows the distance from the cemento-enamel junction to the deepest region of the defect. B. Inverted digital image shows the distance from the cemento-enamel junction to the deepest region of the defect.

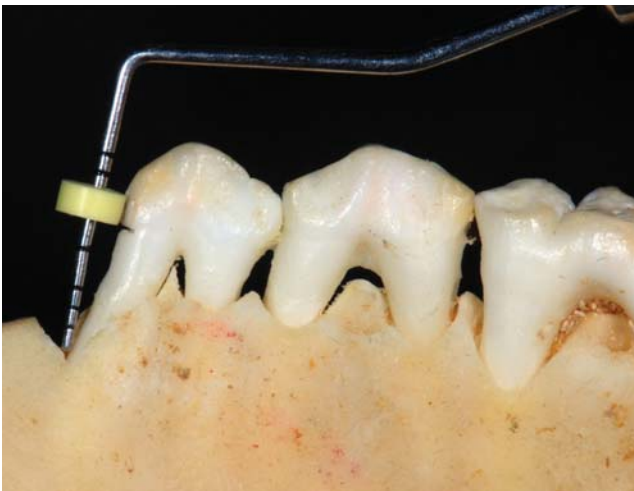


Fig. 2. Direct bone-defect measurement in a dry pig mandible.

Statistical analysis

Student t test was used to compare the depth measurements obtained from the three methods, using the direct visual measurement as the standard for comparison with the other two as follows: the inverted digital images and direct visual measurement in the dry mandibles and film-based images and direct visual measurement in the dry mandibles. A significance level of 0.05 for a 95% confidence interval was used for each comparison.

Results

The results of the linear measurements of the two-wall bone defects using inverted digital images, film-based images, and direct visual measurements in the dry pig

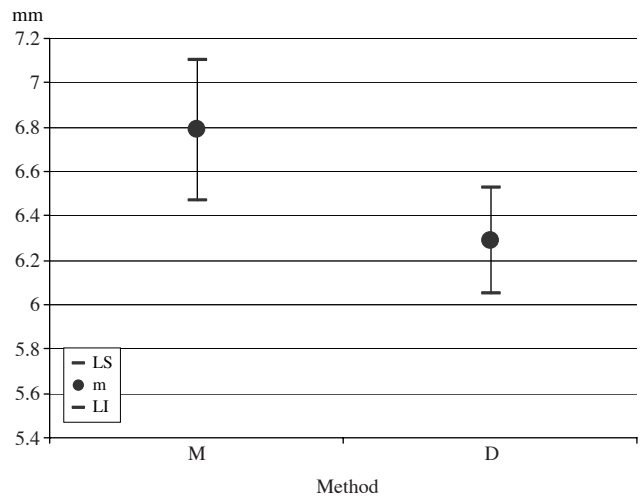


Fig. 3. Mean (m) and 95% confidence limits (LS: upper limit; LI: lower limit) of the bone defect depth (in mm) according to the method (M: direct visual measurements; D: inverted digital image).

mandibles are shown in Figures 3 and 4.

There was a significant difference between the inverted digital images and direct visual measurements ($p > |t| = 0.0039$). The means of the depth measurements on the inverted digital images and direct visual measurements were 6.29 mm (IC_{95%}:6.04-6.54) and 6.79 mm (IC_{95%}:6.45-7.11), respectively (Fig. 3).

There was no significant difference between the film-based images and direct visual measurements ($p > |t| = 0.4950$). The means of the depth measurements on the film-based images and direct visual measurements were 6.64 mm (IC_{95%}:6.40-6.89) and 6.79 mm (IC_{95%}:6.45-7.11), respectively (Fig. 4).

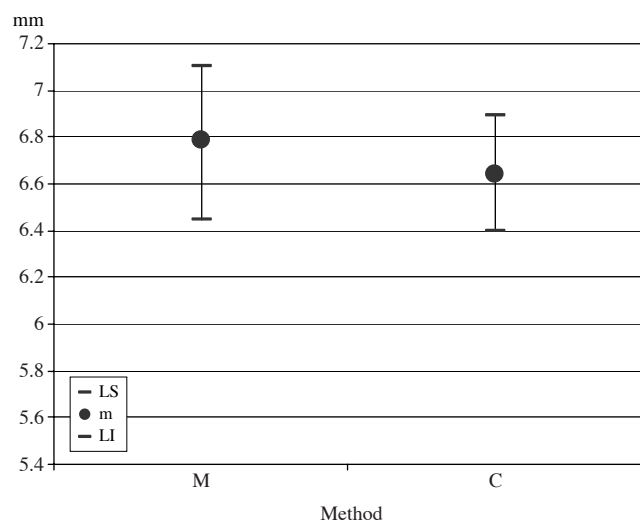


Fig. 4. Mean (m) and 95% confidence limits (LS: upper limit; LI: lower limit) of the bone defect depth (in mm) according to the method (M: direct visual measurements; C: film-based image).

Discussion

There was a significant difference between the measurements of the periodontal defect depth based on the two modalities of the images: the film-based image and inverted digital image. The results showed that there was a significant difference between the inverted digital image and direct visual measurements in the dry pig mandibles. However, the measurements on the film-based radiographs showed no statistical difference when compared with the direct visual measurements. Moreover, the linear measurements of the periodontal bone defects using an inverted digital image underestimated the amount of bone loss. Therefore, inverted digital images were found to be inferior to film-based images in the detection of periodontal bone loss.

Our results were in agreement with a previous study, in which the authors had performed embossed image manipulation.⁴ Although image manipulation in their study was different from that in our study, this agreement could be explained based on the fact that the radiographic interpretation tasks were the same, such as performing linear measurements using the same software (Adobe Photoshop) by the trained examiners. However, Tihanyi et al's study³ using inverted and unprocessed digitized images for periodontal bone loss measurements showed inconsistent results compared with ours. These inconsistent results could be explained by the adopted methodology such as the use of digitized radiographic images, and mainly because in the Tihanyi study there was no method used as standard for

comparison with the imaging methods, such as the direct visual measurements in the dry mandibles that we used.

The most common digital image manipulations are contrast and brightness adjustments of the monitor¹¹ during radiographic interpretation, creating a better image quality for the examiners based on their individual preferences.¹⁰ Some previously studies^{4,6,12-14} have compared manipulated and non-manipulated images in relationship to periodontal measurements and have not found any improvement in the diagnostic accuracy between these two types of image. Our study had the same results, in that the digital inverted images, such as the fact that the manipulated images, did not have better results than the film-based images.

The use of Adobe Photoshop for periodontal bone-defect depth measurements on the digital radiographic images was based on a previously published study,² using four software systems: Schick dedicated software and non-dedicated software systems including VixWin 2000, Adobe Photoshop 7.0, and Image Tool 3.0. The results of that study showed that there was no significant difference in the detection of periodontal bone-defect measurements using four different software programs. Besides the ability to use a specific computer software program for periodontal bone loss measurements, the use of digital images is advantageous due to the possibility of performing other bone loss analyses because digital images are easily obtained and can be used for radiographic interpretation.

Although a review of the literature shows that digital radiographic images of bone loss give an underestimation of measurements compared with the standard criterion,^{6,12,15,16} our results showed that digital radiographic images had the same results as the film-based images and direct visual measurement. According to a previously study,⁴ this result could be explained by the methodology used in our experiment: placing the periodontal probe accurately in the bone defect and following the root inclination with respect to the lower limit of the bone defect. The defects were created on the mesial side of the first pre-molar in the apical direction. This region was chosen because it was the area that offered the best access and provided a sufficient width to create a periodontal bone defect. One suggestion for further studies is to apply the same methodology in a clinical study.

In conclusion, periodontal bone defect measurements on an inverted digital image were inferior to film-based radiography and underestimated the amount of bone loss.

Acknowledgements

The authors would like to thank CAPES for the scholar-

ship to the graduate students and for the grant from State of São Paulo Research Foundation (FAPESP) Process no. 02/13328-0.

References

1. Scaf G, Morihisa O, Loffredo Lde C. Comparison between inverted and unprocessed digitized radiographic imaging in periodontal bone loss measurements. *J Appl Oral Sci* 2007; 15 : 492-4.
2. Scaf G, Sakakura CE, Kalil PF, Dearo de Morais JA, Loffredo LC, Wenzel A. Comparison of simulated periodontal bone defect depth measured in digital radiographs in dedicated and non-dedicated software systems. *Dentomaxillofac Radiol* 2006; 35 : 422-5.
3. Tihanyi D, Gera I, Eickholz P. Influence of individual brightness and contrast adjustment on accuracy of radiographic measurements of infrabony defects. *Dentomaxillofac Radiol* 2011; 40 : 177-83.
4. de Molon RS, Sakakura CE, Morais-Camillo JA, de Almeida Junior PC, de Castro Monteiro Loffredo L, Scaf G. Comparison between embossed digital imaging and unprocessed film-based radiography in detecting periodontal bone defects: an in vitro study. *Oral Radiol* 2012; 28 : 95-100.
5. Borg E, Gröndahl K, Gröndahl HG. Marginal bone level buccal to mandibular molars in digital radiographs from charge-coupled device and storage phosphor systems. An in vitro study. *J Clin Periodontol* 1997; 24 : 306-12.
6. Eickholz P, Hausmann E. Accuracy of radiographic assessment of interproximal bone loss in intrabony defects using linear measurements. *Eur J Oral Sci* 2000; 108 : 70-3.
7. de Morais JA, Sakakura CE, Loffredo LC, Scaf G. Accuracy of zoomed digital image in the detection of periodontal bone defect: in vitro study. *Dentomaxillofac Radiol* 2006; 35 : 139-42.
8. Sakakura CE, Loffredo Lde C, Scaf G. Diagnostic agreement of conventional and inverted scanned panoramic radiographs in the detection of the mandibular canal and the mental foramen. *J Oral Implantol* 2004; 30 : 2-6.
9. Tyndall DA, Ludlow JB, Platin E, Nair M. A comparison of Kodak Ektaspeed Plus film and the Siemens Sidexis digital imaging system for caries detection using receiver operating characteristic analysis. *Oral Surg Oral Med Oral Pathol Oral Radiol Endod* 1998; 85 : 113-8.
10. Isidor S, Faaborg-Andersen M, Hintze H, Kirkevang LL, Frydenberg M, Haiter-Neto F, et al. Effect of monitor display on detection of approximal caries lesions in digital radiographs. *Dentomaxillofac Radiol* 2009; 38 : 537-41.
11. Hellén-Halme K, Petersson A, Warfvinge G, Nilsson M. Effect of ambient light and monitor brightness and contrast settings on the detection of approximal caries in digital radiographs: an in vitro study. *Dentomaxillofac Radiol* 2008; 37 : 380-4.
12. Eickholz P, Riess T, Lenhard M, Hassfeld S, Staehle HJ. Digital radiography of interproximal bone loss; validity of different filters. *J Clin Periodontol* 1999; 26 : 294-300.
13. Nair MK, Ludlow JB, Tyndall DA, Platin E, Denton G. Periodontitis detection efficacy of film and digital images. *Oral Surg Oral Med Oral Pathol Oral Radiol Endod* 1998; 85 : 608-12.
14. Wolf B, Von Bethlenfalvy E, Hassfeld S, Staehle HJ, Eickholz P. Reliability of assessing interproximal bone loss by digital radiography: intrabony defects. *J Clin Periodontol* 2001; 28 : 869-78.
15. Eickholz P, Kim TS, Benn DK, Staehle HJ. Validity of radiographic measurement of interproximal bone loss. *Oral Surg Oral Med Oral Pathol Oral Radiol Endod* 1998; 85 : 99-106.
16. Furkart AJ, Dove SB, McDavid WD, Nummikoski P, Matteson S. Direct digital radiography for the detection of periodontal bone lesions. *Oral Surg Oral Med Oral Pathol* 1992; 74 : 652-60.