

Invasive cervical resorption: treatment challenges

Yookyung Kim, Chan-Young Lee, Euseong Kim, Byoung-Duck Roh*

Department of Conservative Dentistry,
Yonsei University College of Dentistry,
Seoul, Korea

Invasive cervical resorption is a relatively uncommon form of external root resorption. It is characterized by invasion of cervical region of the root by fibrovascular tissue derived from the periodontal ligament. This case presents an invasive cervical resorption occurring in maxillary lateral incisor, following damage in cervical cementum from avulsion and intracoronary bleaching procedure. Flap reflection, debridement and restoration with glass ionomer cement were performed in an attempt to repair the defect. But after 2 mon, more resorption extended apically. Considering root stability and recurrence potential, we decided to extract the tooth. Invasive cervical resorption in advanced stages may present great challenges for clinicians. Therefore, prevention and early detection must be stressed when dealing with patients presenting history of potential predisposing factors. (*Restor Dent Endod* 2012;37(4):228-231)

Key words: Dental trauma; External cervical resorption; Intracoronary bleaching; Invasive cervical resorption; Root resorption

Introduction

Invasive cervical resorption (ICR) is a type of external root resorption which is characterized by invasion of root dentin by fibrovascular tissue derived from the periodontal ligament.¹ ICR usually starts from cervical cement-enamel junction (CEJ) where the epithelial attachment is located, and purely inflammatory, irrelevant to bacterial infections until secondary invasion from gingival sulcus occurs. Furthermore, it exhibits very aggressive behavior compared with typical external root resorptions.¹⁻³ Therefore when dealing with this specific kind of resorption, different approaches are needed, aiming complete removal of the resorptive tissue and definite seal of the affected dentinal tubules.⁴

Heithersay classified ICRs into 4 categories according to the extent of the resorption.⁵ As would be expected, smaller lesions (Classes 1 and 2) offer favorable outcomes. But in the advanced stages (Class 4), success rate drastically fall down to 12.5%. The most common reason of failure was ongoing resorption and root fracture. This low success rate raises the question of the desirability of attempting a treatment. It is very difficult to eliminate the resorptive tissues without harming the root stability, and as far as blood supply from the periodontium remains, the resorption may continue.

Received June 12, 2012;
Revised July 30, 2012;
Accepted August 23, 2012.

Kim Y; Lee CY; Kim ES; Roh BD,
Department of Conservative
Dentistry, Yonsei University College
of Dentistry, Seoul, Korea

*Correspondence to

Byoung-Duck Roh, DDS, MSD, PhD.
Professor, Department of
Conservative Dentistry, Yonsei
University College of Dentistry, 50
Yonsei-Ro, Seodaemun-gu, Seoul,
Korea 120-752
TEL, +82-2-2228-8701; FAX, +82-
2-313-7575; E-mail, operatys16@
yuhs.ac

Case reports

Following a car accident, a 24-year-old woman was presented to the emergency department in Yonsei University College of Dentistry, Seoul, Korea. Three of maxillary anterior teeth, both maxillary central incisors and right lateral incisor were totally avulsed and stored dry for 1 hour. Saline irrigation of the contaminated root surfaces, replant and resin-wire splint was performed. After 1 week, she was referred to Department of Conservative Dentistry and routine nonsurgical root canal treatment was conducted. The teeth were stable on the 12 months recall visit and presented no unusual changes other than minor surface resorption. At the 15 months recall, the patient complained about brownish discoloration of the crown, so right central and lateral incisors were bleached for 1 week with sodium perborate and distilled water. Two weeks later, access cavity was restored with composite resin. Afterwards, the patient did not show up for another 15 months due to personal affairs.

Thirty months after the trauma, the patient came to our department again for regular checkups. The patient was still free of symptoms, but there was a sinus tract formed on labial mucosa of right maxillary lateral incisor. Periapical radiograph was taken with gutta-percha tracing to confirm the origin. Surprisingly on the distal root surface of right lateral incisor, a noticeable cervical defect was revealed. The resorptive lesion was provisionally diagnosed as invasive cervical resorption and surgical repair was attempted (Figure 1).

All procedures were performed under operating microscope (OPMI, PICO, Carl Zeiss, Gottingen, Germany). After local anesthesia (2% lidocaine with 1:100,000 adrenaline), full-thickness periosteal flap was elevated. Soft tissue curettage and initial debridement with low-speed round bur disclosed the characteristic resorptive lesion involving labial and distal surfaces of the root (Figure 2). First, numerous small bleeding points (referred to as 'penetration points' by Schwartz) were observed.⁶ These indicate that the lesion possesses active resorptive potentials carrying blood supply from the periodontium into deeper parts. The base containing these points was solid on probing. This is a feature of advanced ICR lesions with fibro-osseous tissue replacing resorbed dentin. Failure to differentiate this ectopic calcified material from dentin can lead to failure in treatment, because resorption will continue beneath the apparently sound cavity base.⁵ Tooth preparation was carried out and intact dentin base was confirmed under high magnification (X16 - 20). The cavity was restored with reinforced glass ionomer (GC Fuji II LC, GC Corporation, Tokyo, Japan) and light cured. Further refinement was achieved with a fine tapered diamond bur. Flap was repositioned and sutured interproximally with 4-0 mersilk (Mersilk, Ethicon, Edinburgh, UK).

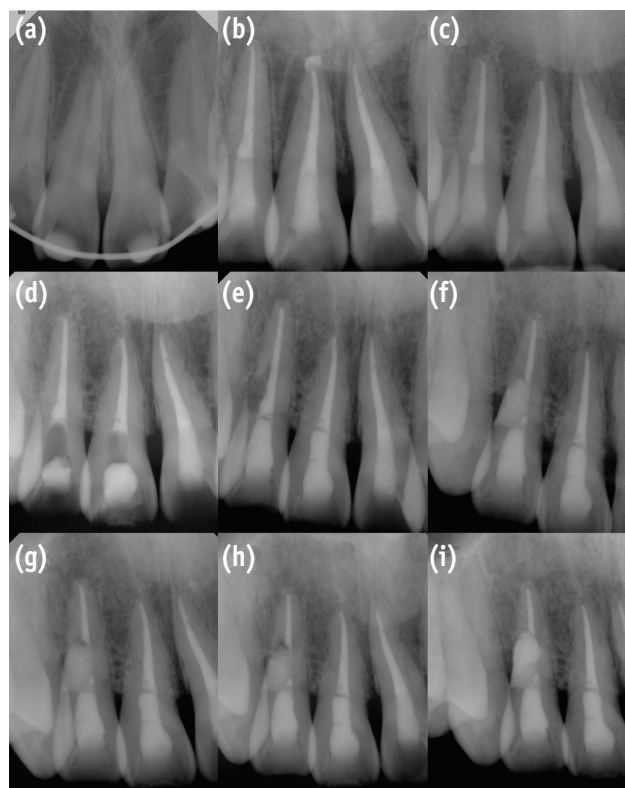


Figure 1. Serial periapical radiographs. (a) Initial visit, after replantation; (b) After root canal treatment; (c) 12 months follow-up; (d) 15 months follow-up. Walking bleaching performed; (e) 30 months follow-up. ICR developed on distal surface of #12; (f) After surgical repair; (g) 1 month after the surgery; (h) 2 months after the surgery; (i) After the second surgery. Afterwards the tooth was extracted.

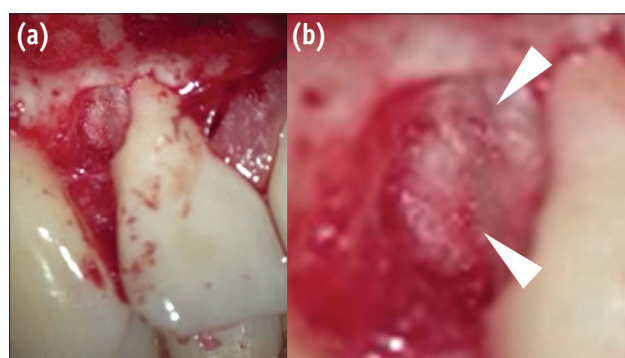


Figure 2. Microscopic view during surgical repair. Arrowheads indicate penetration points. Note the fibro-osseous tissue resembling dentin on the surface. (a) X6; (b) X16 magnification.

One month recall showed satisfactory gingival healing and the patient was free of symptoms. However on the radiograph, suspicious radiolucent spot was observed under the glass ionomer filling, and after another month, sinus tract recurred. Periapical radiograph with gutta-percha tracing definitely shows apically advanced radiolucent lesion under the glass ionomer filling (Figure 3). Treatment options were discussed with the patient and decided to go on a re-surgery. Full-thickness periosteal flap was once more elevated. As predicted, the progressed resorption site was clearly seen under the buccal side of glass ionomer filling. After initial debridement, penetration points in the cavity were visible, again suggesting that there are tissues with active resorption potential left inside. Additional tooth preparation of the remaining resorptive tissue and glass-ionomer filling was done, but considering root stability and associated periradicular pathosis, we decided to extract the tooth (Figure 1).

Discussion

This case report illustrates a characteristic invasive cervical resorption which developed and progressed rapidly, and eventually ended on extraction of the tooth. Until today, the exact cause of ICR has not been fully understood, but it is broadly accepted that damage to or

deficiency of cementum below the epithelial attachment is somehow related.² Without protective cementum layer, the root dentin is directly exposed to the periodontal ligament cells which can differentiate into cells capable of laying down fibrous or calcified tissue. Heithersay investigated 257 teeth displaying ICR to assess these factors and concluded that orthodontic treatment, trauma, intracoronary bleaching, and surgery had strong association between development of ICR.⁷ In this case, trauma, specifically avulsion, and intracoronary bleaching was associated.

It is generally believed that application of heat, 30% hydrogen peroxide, and lack of cervical barrier are related to root resorptions from intracoronary bleaching procedures.^{8,9} In this case, walking bleaching using sodium perborate and distilled water was performed, but unfortunately cervical base was omitted. In normal situations, walking bleaching has been known relatively safe.¹⁰ But sodium perborate mixed with water actually generates low levels of H_2O_2 , and in this case, unfortunately there were previous surface resorption caused by avulsion. A quantitative study has demonstrated that artificial defects in cementum cause increase in H_2O_2 penetration up to 82% of total amount, and avulsed tooth resembles this situation *in vivo*.¹¹ Unimpeded passage of H_2O_2 could be expected through denuded cementum into the periodontal ligament, resulting in simulation of resorption process.^{12,13}

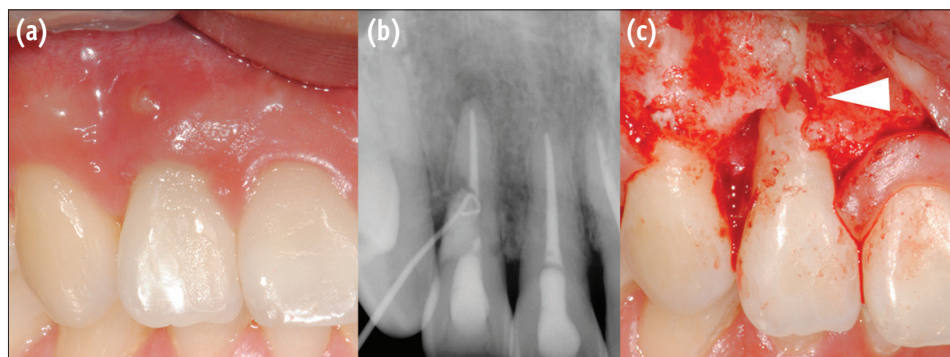


Figure 3. (a) Recurred sinus tract 2 months after the surgery; (b) Periapical radiograph with gutta-percha tracing reveals the origin; (c) After opening the flap once more, advanced resorption below the glass ionomer filling was clearly seen (Arrowhead).

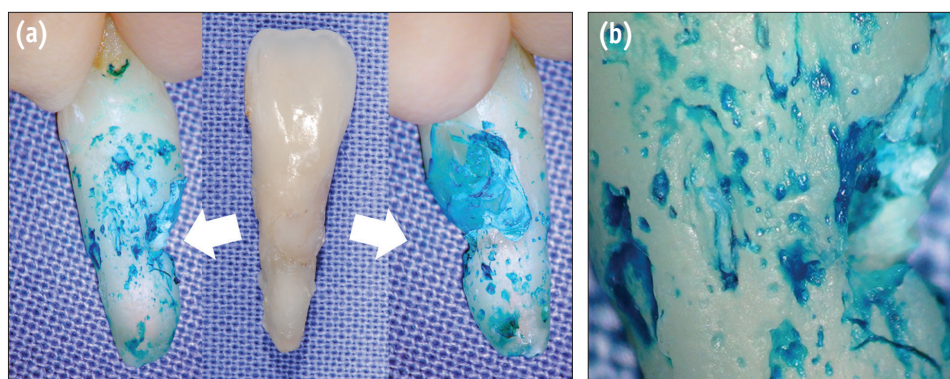


Figure 4. (a) Methylene blue staining after extraction of the tooth, mesial and distal side; (b) X20 magnification.

But we should note that this is only a possible assumption and the true mechanism can be hidden. Actually, not every tooth in similar condition develops ICR and this area still remains to be explained.

Before the first surgical repair, we classified the case as Heithersay class 3 according to the radiographic extent. However, considering the fact that an apical lesion developed which was not seen before, the total root canal space must have been invaded with microorganisms. If so, then maybe the lesion was already class 4 at the time. Resorptions of this magnitude usually have a complicated structure comprised of not only fibrovascular tissues, but of ectopic calcifications deposited on the resorbed dentin surface. These features were seen from the first surgical intervention (Figure 2). Furthermore, a series of channels containing resorptive tissue are present, and they usually have connections further apically with the periodontal ligament. These channels can involve serious problems. No matter how thoroughly the tissue of the main lesion is removed, as long as the apical channels remain and deliver blood supply from the periodontium, the possibility of recurrence will always exist.

After extracting the tooth in this case, methylene blue staining of the root surface was performed. Interestingly, there were defects all over the root surface (Figure 4). We do not know how many of these defects are actually linked to the main lesion as a 'channel', but there are studies presenting histological sections and after clearing images which demonstrate definite connections to a certain extent in similar extracted ICR teeth, and the same might be said of this case.^{1,6} Consequently, resorption control by tooth preparation is almost impossible to reach into these areas, and even if it was possible, it would result in excessive weakening of the root. So, according to Heithersay, no treatment or alternative therapy is indicated for class 4 lesions, in which resorption has extended beyond one third of the root length.⁵

Therefore till now, prevention and early detection is essential for successful management of ICR, since advanced lesions can present great challenges for clinicians. When dealing with patients with a history of one or more potential predisposing factors, we must be careful when adding more factors, and should monitor very closely for initial signs of ICR, because smaller lesions offer the most favorable outcome.

Conclusions

This case presents an invasive cervical resorption that finally resulted in extraction of the tooth. It may have been caused by damage in cervical cementum, physically from avulsion and chemically from intracoronal bleaching procedure. Invasive cervical resorption in advanced stages may present great challenges for clinicians. Therefore,

prevention and early detection must be stressed when dealing with patients presenting history of potential predisposing factors.

Conflict of Interest: No potential conflict of interest relevant to this article was reported.

References

1. Heithersay GS. Clinical, radiologic, and histopathologic features of invasive cervical resorption. *Quintessence Int* 1999;30:27-37.
2. Patel S, Kanagasingam S, Pitt Ford T. External cervical resorption: a review. *J Endod* 2009;35:616-625.
3. Frank AL, Torabinejad M. Diagnosis and treatment of extracanal invasive resorption. *J Endod* 1998;24:500-504.
4. Kçiku L, Ebeleseder KA, Glockner K. Treatment of invasive cervical resorption with sandwich technique using mineral trioxide aggregate: a case report. *Oper Dent* 2012;37:98-106.
5. Heithersay GS. Treatment of invasive cervical resorption: an analysis of results using topical application of trichloroacetic acid, curettage, and restoration. *Quintessence Int* 1999;30:96-110.
6. Schwartz RS, Robbins JW, Rindler E. Management of invasive cervical resorption: observations from three private practices and a report of three cases. *J Endod* 2010;36:1721-1730.
7. Heithersay GS. Invasive cervical resorption: an analysis of potential predisposing factors. *Quintessence Int* 1999; 30:83-95.
8. Attin T, Paqué F, Ajam F, Lennon AM. Review of the current status of tooth whitening with the walking bleach technique. *Int Endod J* 2003;36:313-329.
9. Dahl JE, Pallesen U. Tooth bleaching-a critical review of the biological aspects. *Crit Rev Oral Biol Med* 2003; 14:292-304.
10. Madison S, Walton R. Cervical root resorption following bleaching of endodontically treated teeth. *J Endod* 1990;16:570-574.
11. Rotstein I. *In vitro* determination and quantification of 30% hydrogen peroxide penetration through dentin and cementum during bleaching. *Oral Surg Oral Med Oral Pathol* 1991;72:602-606.
12. Andreasen JO, Hjorting-Hansen E. Replantation of teeth. II. Histological study of 22 replanted anterior teeth in humans. *Acta Odontol Scand* 1966;24:287-306.
13. Plotino G, Buono L, Grande NM, Pameijer CH, Somma F. Nonvital tooth bleaching: a review of the literature and clinical procedures. *J Endod* 2008;34:394-407.