

# A Case of Therapy of Aerosolized Ribavirin in a Leukemia Infant with RSV Infection

Hyo Jin Kwon, M.D., Myung Jin Oh, M.D.\*, Jae Wook Lee, M.D.\*, Nak Gyun Chung, M.D.\*, Bin Cho, M.D.\*, Hack Ki Kim, M.D.\*, and Jin Han Kang, M.D.\*

Department of Pediatrics, College of Medicine, Korea University, Seoul, Korea

Department of Pediatrics\*, College of Medicine, The Catholic University of Korea, Seoul, Korea

Respiratory syncytial virus (RSV) is the major cause of lower respiratory tract infection in infants. Life-threatening RSV infection is often reported in young children and immunocompromised hosts. Since there is no report on ribavirin therapy for RSV pneumonia in pediatric cancer patients in Korea, we report one case of RSV pneumonia that developed in an infant with acute lymphoblastic leukemia (ALL). Despite administration of oral ribavirin and intravenous immunoglobulin, the patient's respiratory distress worsened and admission to an intensive care unit was necessary. Chest x-ray showed multifocal consolidation, pneumothorax, and pneumomediastinum. Treatment with aerosolized ribavirin led to significant clinical improvement. The role of aerosolized ribavirin is still controversial, but it might have a therapeutic potential for severe RSV pneumonia in children with leukemia. (**Korean J Pediatr Infect Dis 2012;19:162-167**)

**Key Words :** RSV infection, Leukemia, Child, Ribavirin

## Introduction

Respiratory syncytial virus (RSV) is a single-stranded, enveloped RNV virus, which represents the primary respiratory pathogen in infants and young children worldwide<sup>1)</sup>. Although most infections are self-limited, RSV can be associated with severe and life-threatening clinical conditions, particularly among high-risk patients such as those with prematurity, congenital heart disease, chronic lung disease, and immunocompromised individuals<sup>2, 3)</sup>. At present, the most effective therapy of RSV infection remains supportive care. Inhaled ribavirin (Virazole

®, Valeant Pharmaceuticals International, Aliso Viejo, California, USA) is the only licensed antiviral agent approved for the treatment of RSV lower respiratory tract infection (LRTI) in hospitalized infants and young children, although its use is now restricted to high-risk infants. However, there are some limitations of clinical practice, and aerosolized ribavirin is extremely expensive, is difficult to use, and not supported by controlled clinical trials. In Korea, little has been reported about the treatment with aerosolized ribavirin of pediatric patients with cancer. Herein, we present the case of an infant with leukemia and severe RSV pneumonia who was successfully treated with aerosolized ribavirin.

## Case Report

An 8-month-old infant with acute lymphoblastic leukemia (ALL) was transferred to our institution

Received : 19 April 2012, Revised : 6 June 2012

Accepted : 11 June 2012

Correspondence : Jin Han Kang, M.D.

Department of Pediatrics, Seoul St. Mary's Hospital, The Catholic University of Korea, Seoul, Korea

Tel : +82-2-2258-2828, Fax : +82-2-537-4544

E-mail : kjhan@catholic.ac.kr

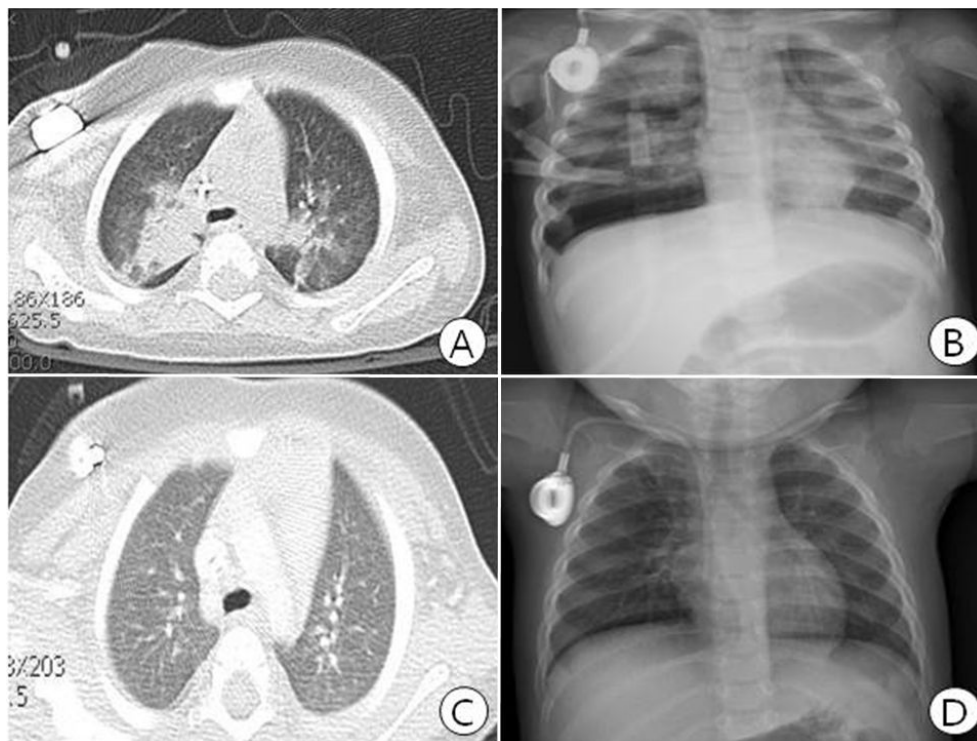
for chemotherapy. She was born by normal vaginal delivery at 38 weeks of gestation with a birth weight of 3.15 kg. There was no previous history of illness, and the familial history was unremarkable. At the time of transfer, the patient had respiratory symptoms of coughing and runny nose. She had no fever. Physical examination did not reveal any significant findings. She began remission–induction chemotherapy on the second day of hospitalization.

On hospital day 8, she developed fever (maximum temperature, 38.9°C) with worsened cough, but exhibited no signs or symptoms of respiratory distress. On physical examination, crackle and wheezing were heard. The chest computed tomography (CT) showed multifocal air–space consolidation in both lungs (Fig. 1A). The fever persisted despite the administration of empiric antibiotics (teicoplanin and meropenem). Multiplex polymerase chain reaction (PCR)/RT–PCROP (Cosmo Genetech, Seoul, South Korea) assay of a panel of respiratory viruses performed on a nasopharyngeal specimen (obtained hospital day 8) revealed a positive result for RSV on hospital day 11. Treatment with intravenous immunoglobulin (IVIG, 400 mg/kg/day, 5 days) and oral ribavirin (15 mg/kg/day) was initiated. By day 5 of IVIG therapy, the high–grade fever disappeared, but the patient’s clinical condition was deteriorating. She presented with tachypnea, irritability, and chest wall retraction. The chest x–ray on follow–up revealed pneumothorax and pneumomediastinum, and a chest tube was inserted (Fig. 1B). Laboratory findings were as follows: hemoglobin of 10.7 g/dL; white blood cell (WBC) count of 1,100/mm<sup>3</sup> (neutrophil 24%, lymphocyte 74%, monocyte 2%); and a platelet count of 68,000/mm<sup>3</sup>. C–reactive protein (CRP) was 0.1 mg/dL (normal range, 0.0–0.5). Although

supplementary oxygen 2L was administered, the percutaneous oxygen saturation (SpO<sub>2</sub>) decreased to 85–87%, and the patient was transferred to the pediatric intensive care unit (PICU).

On PICU day 1 (hospital day 16), the pneumothorax and respiratory status of the patient were worsening, so we decided to administer aerosolized ribavirin. According to the manufacturer’s recommendation, a daily dose of 6 g was diluted with sterile water to a volume of 300 mL to achieve a concentration of 20 mg/mL. The aerosolized ribavirin was delivered by the Small Particle Aerosol Generator (SPAG 2, ICN Pharmaceuticals, Inc., California, USA) via a face mask. Ribavirin was administered over 18 hours every 24 hours for 3 days. Cardiopulmonary monitoring including electrocardiogram and pulse oximetry was provided for the patient. During the course of therapy with ribavirin, the patient tolerated the medication, without specific side–effects such as bronchospasm and hemolytic anemia. Later she showed marked clinical improvement on hospital day 20.

However, she again developed fever (up to 39.2°C), hypotension, and pulmonary hemorrhage on hospital day 22. There was a new infiltrate on chest radiograph. Laboratory findings revealed hemoglobin of 10.1 g/dL, WBC count of 22,000/mm<sup>3</sup> (neutrophil 81%, lymphocyte 11%, monocyte 7.2%), platelet count of 113,000/mm<sup>3</sup>, and CRP was 0.1 mg/dL. Culture was negative for bacteria, *Mycobacterium* species, and fungi. The PCR analysis for *Pneumocystis jirovecii* and cytomegalovirus were all negative. The galactomannan assay from serum and bronchoalveolar lavage fluid was 0.8 and 0.5, respectively. She was diagnosed with probable invasive pulmonary aspergillosis (IPA) and treated with voriconazole<sup>4</sup>.



**Fig. 1.** Computed tomography of chest revealed multifocal air-space consolidation in both lungs (A), and chest radiography showed pneumothorax and pneumomediastinum in right side (B). After aerosolized ribavirin treatment, follow-up computed tomography (C) and chest radiography (D) showed improvement of patchy consolidations and pneumothorax.

On the third day of the voriconazole treatment, the patient became afebrile and the chest tube was removed. Upon resolution of her symptoms, the patient's clinical condition and chest x-ray improved, and antibiotics was discontinued on hospital day 33 (Fig. 1D). Her repeated multiplex PCR assessment, done weekly, was negative for RSV on hospital day 37. She was discharged with oral voriconazole 38 days after admission. After six months, the chest CT revealed significant regression of lung lesions (Fig. 1C). At present, she is followed in the outpatient clinic regularly for maintenance chemotherapy and is doing well.

## Discussion

RSV is one of the most common causes of pediatric bronchiolitis and pneumonia worldwide<sup>1)</sup>. Although most infections are self-limited, RSV infection can be associated with significant morbidity and mortality in premature patients and infants with chronic lung disease or hemodynamically significant congenital heart disease<sup>2, 3)</sup>. Furthermore, RSV has been now recognized as an important cause of LRTI and death in patients with hematologic malignancy and recipients of transplants<sup>5-7)</sup>. In this case, severe RSV pneumonia developed in an ALL infant undergoing remission-induction chemotherapy. Among immunocompromised children, severe RSV infection has

been reported, especially in children undergoing chemotherapy for cancer and those with immunodeficiency disease<sup>7</sup>). Several factors have been identified that increase the risk for progression of severe RSV disease, such as the loss of integrity in the mucosa, low production of serum antibodies, deficient cytotoxic T-cell function, lymphopenia, following chemotherapy or transplants<sup>8, 9</sup>).

However, current treatment options are primarily supportive care, including maintenance of an airway, providing adequate hydration, and preventing hypoxemia or hypercarbia. The data regarding treatment of severe RSV infection in leukemic children is sparse in Korea. Ribavirin, a nucleotide analogue, is the only antiviral drug approved in the United States by the Federal Drug Administration (FDA) for the therapy of severe RSV disease. Although several randomized trials suggested that ribavirin was efficacious for RSV infection<sup>10, 11</sup>, its use remains under debate because of questions about the efficacy, concerns about substantial safety issues, difficulty of use, and its high cost<sup>12</sup>). In addition, there are several treatment regimens based on the different methods of ribavirin administration, and comparative study for each is lacking. Anak et al.<sup>13</sup> suggested that oral ribavirin with IVIG can be a safe and practical regimen in the treatment of RSV infection among pediatric patients with oncologic diseases and/or bone marrow transplantation (BMT). Intravenous ribavirin therapy has shown favorable results in a few cases, but there are no established data to support this<sup>14, 15</sup>). The patient reported here continued to deteriorate clinically despite the use of oral ribavirin and IVIG, therefore aerosolized ribavirin was subsequently administered. The therapy was relatively well tolerated, and improvement occurred

only after initiation of aerosolized ribavirin. However, therapy was available only for the minimum duration of three days because of the burden of high cost. Clinical deterioration with pulmonary hemorrhage and hypotension was again seen on hospital day 22, but this was likely because our patient developed IPA with a positive galactomannan assay. It has been known that immunocompetent patients can develop IPA immediately after or during respiratory virus-related LRTI<sup>16, 17</sup>). In addition, recent studies reported that respiratory virus infections increase the risk of IPA after allogeneic hematopoietic stem cell transplantation (HSCT)<sup>18, 19</sup>).

Persistence of RSV infection beyond usual time periods (RSV shedding may exceed 100 days versus 21 days for immunocompetent children) among immunocompromised patients is often observed, and is associated with high morbidity and mortality rates<sup>7</sup>). In our patient, RSV PCR was performed each week, and RSV positivity was shown for 37 days. Further studies about the association between the treatment of ribavirin and the duration of viral shedding will be needed.

In summary, this is the first report of RSV pneumonia in an immunocompromised infant who underwent chemotherapy and was successfully treated with aerosolized ribavirin in Korea. Our case suggests the use of aerosolized ribavirin as a treatment option in cases of severe RSV pneumonia in pediatric leukemia patients.

## Declaration of Interest

The authors state no conflict of interest and have received no payment in preparation of this manuscript.

## 한 글 요약

### 항암치료 중 RSV에 감염된 백혈병 영아에서의 리바비린 흡입치료 1례

고려대학교 의과대학 소아과학교실  
가톨릭대학교 의과대학 소아과학교실\*

권효진 · 오명진\* · 이재욱\* · 정낙균\* · 조 빈\* · 김학기\*  
강진한\*

RSV는 2세 미만의 소아에서 급성 하기도 감염으로 인한 입원의 주원인이다. 특히 미숙아, 선천성 심폐질환, 면역결핍이 동반된 경우 주요 위험군으로 알려져 있다. 고위험군의 소아에서 종종 RSV 감염의 경우 리바비린 흡입 요법이 허가가 되어 있으나 고비용, 안전성 등의 문제로 국내 임상에서의 사용은 매우 제한적인 실정이다. 저자들은 8개월 여환이 급성 림프구성 백혈병으로 관해유도요법 항암치료 중 발생한 RSV 폐렴으로 기흉, 기종격동, 호흡부전이 동반된 중증 감염을 경험하였다. 정맥용 면역글로블린, 경구 리바비린 투여에 반응이 없어 리바비린 흡입 치료를 시행하였고, 이후 임상적 호전을 경험하였기에 보고하는 바이다.

## References

- 1) Wright M, Piedimonte G. Respiratory syncytial virus prevention and therapy: past, present, and future. *Pediatr Pulmonol* 2011;46:324-47.
- 2) Law BJ, Carbonell-Estrany X, Simoes EA. An update on respiratory syncytial virus epidemiology: a developed country perspective. *Respir Med* 2002;96 Suppl B:S1-7.
- 3) Welliver RC. Review of epidemiology and clinical risk factors for severe respiratory syncytial virus (RSV) infection. *J Pediatr* 2003;143:S112-7.
- 4) De Pauw B, Walsh TJ, Donnelly JP, Stevens DA, Edwards JE, Calandra T, et al. Revised definitions of invasive fungal disease from the European Organization for Research and Treatment of Cancer/Invasive Fungal Infections Cooperative Group and the National Institute of Allergy and Infectious Diseases Mycoses Study Group (EORTC/MSG) Consensus Group. *Clin Infect Dis* 2008;46:1813-21.
- 5) Harrington RD, Hooton TM, Hackman RC, Storch GA, Osborne B, Gleaves CA, et al. An outbreak of respiratory syncytial virus in a bone marrow transplant center. *J Infect Dis* 1992;165:987-93.
- 6) Torres HA, Aguilera EA, Mattiuzzi GN, Cabanillas ME, Rohatgi N, Sepulveda CA, et al. Characteristics and outcome of respiratory syncytial virus infection in patients with leukemia. *Haematologica* 2007;92:1216-23.
- 7) Hall CB, Powell KR, MacDonald NE, Gala CL, Menegus ME, Suffin SC, et al. Respiratory syncytial viral infection in children with compromised immune function. *N Engl J Med* 1986;315:77-81.
- 8) El Saleeby CM, Somes GW, DeVincenzo JP, Gaur AH. Risk factors for severe respiratory syncytial virus disease in children with cancer: the importance of lymphopenia and young age. *Pediatrics* 2008;121:235-43.
- 9) Raboni SM, Nogueira MB, Tsuchiya LR, Takahashi GA, Pereira LA, Pasquini R, et al. Respiratory tract viral infections in bone marrow transplant patients. *Transplantation* 2003;76:142-6.
- 10) Groothuis JR, Woodin KA, Katz R, Robertson AD, McBride JT, Hall CB, et al. Early ribavirin treatment of respiratory syncytial viral infection in high-risk children. *J Pediatr* 1990;117:792-8.
- 11) Hall CB, McBride JT, Walsh EE, Bell DM, Gala CL, Hildreth S, et al. Aerosolized ribavirin treatment of infants with respiratory syncytial viral infection. A randomized double-blind study. *N Engl J Med* 1983;308:1443-7.
- 12) Shults RA, Baron S, Decker J, Deitchman SD, Connor JD. Health care worker exposure to aerosolized ribavirin: biological and air monitoring. *J Occup Environ Med* 1996;38:257-63.
- 13) Anak S, Atay D, Unuvar A, Garipardic M, Agaoglu L, Ozturk G, et al. Respiratory syncytial virus infection outbreak among pediatric patients with oncologic diseases and/or BMT. *Pediatr Pulmonol* 2010;45:307-11.
- 14) Raza K, Ismailjee SB, Crespo M, Studer SM, Sanghavi S, Paterson DL, et al. Successful outcome of human metapneumovirus (hMPV) pneumonia in a lung transplant recipient treated with intravenous ribavirin. *J Heart Lung Transplant* 2007;26:862-4.
- 15) Sparrelid E, Ljungman P, Ekelöf-Andström E, Aschan J, Ringdén O, Winiarski J, et al. Ribavirin therapy in bone marrow transplant recipients with viral respiratory tract infections. *Bone Marrow Transplant* 1997;19:905-8.

- 16) Hasejima N, Yamato K, Takezawa S, Kobayashi H, Kadoyama C. Invasive pulmonary aspergillosis associated with influenza B. *Respirology* 2005;10:116–9.
- 17) Alba D, Gomez–Cerezo J, Cobo J, Ripoll MM, Molina F, Vazquez JJ. Invasive pulmonary aspergillosis associated with influenza virus. *An Med Interna* 1996;13:34–6.
- 18) Marr KA, Carter RA, Boeckh M, Martin P, Corey L. Invasive aspergillosis in allogeneic stem cell transplant recipients: changes in epidemiology and risk factors. *Blood* 2002;100:4358–66.
- 19) Martino R, Piñana JL, Parody R, Valcarcel D, Sureda A, Brunet S, et al. Lower respiratory tract respiratory virus infections increase the risk of invasive aspergillosis after a reduced–intensity allogeneic hematopoietic SCT. *Bone Marrow Transplant* 2009;44:749–56.