

## RESEARCH ARTICLE

# Safety Assessment of Ovarian Cryopreservation and Transplantation in Nude Mice Bearing Human Epithelial Ovarian Cancer

Gen-Hai Zhu<sup>1\*</sup>, Sheng-Tan Wang<sup>1</sup>, Zhao-Xin Yang<sup>2</sup>, Jun-Hong Cai<sup>3</sup>, Chun-Ying Chen<sup>1</sup>, Mao-Zhong Yao<sup>2</sup>, Lan Hong<sup>1</sup>, Guo-Li He<sup>1</sup>, Shu-Ying Yang<sup>1</sup>

### Abstract

**Objective:** Nude mice with orthotopic transplantation of human ovarian epithelial cancer were used to investigate screening criteria for paraneoplastic normal ovarian tissue and the security of the freezing and thawing for ovarian tissue transplantation. **Methods:** Expression of CK-7, CA125, P53, survivin, MMP-2/TIMP-2 in paraneoplastic normal ovarian tissues were detected by RT-PCR as well as immunohistochemistry. The tissues of the groups with all negative indicators of RT-PCR, all negative indicators of immunohistochemistry, negative expression of CK-7, CA125 and survivin, positive expression of CK-7, CA125 and survivin, cancer tissues and normal ovarian tissues of nude mice were used for freezing and thawing transplantation, to analyze overt and occult carcinogenesis rates after transplantation. **Results:** When all indicators or the main indicators, CK-7, CA125 and survivin, were negative, tumorigenesis did not occur after transplantation. In addition the occult carcinogenesis rate was lower than in the group with positive expression of CK-7, CA125 and survivin ( $P < 0.01$ ). After subcutaneous and orthotopic transplantation of ovarian tissues, rates did not change ( $P > 0.05$ ). There was no statistical significance among rates after transplantation of ovarian tissues which were obtained under different severity conditions ( $P > 0.05$ ). **Conclusion:** Negative expression of CK-7, CA125 and survivin can be treated as screening criteria for security of ovarian tissues for transplantation. Immunohistochemical methods can be used as the primary detection approach. Both subcutaneous and orthotopic transplantation are safe. The initial severity does not affect the carcinogenesis rate after tissue transplantation. Freezing and thawing ovarian tissue transplantation in nude mice with human epithelial ovarian carcinoma is feasible and safe.

**Keywords:** Epithelial ovarian cancer - ovarian cryopreservation - transplantation - tumor-associated gene

*Asian Pacific J Cancer Prev*, 13 (9), 4669-4675

### Introduction

The treatments of ovarian cancer mainly include surgery and chemotherapy. After surgery, patients will lose ovarian function permanently. A considerable portion of patients with epithelial ovarian cancer are women of childbearing age. The loss of ovarian function will lead to a serial of clinical symptoms or metabolic syndrome (Michelsen et al., 2009). The patients' quality of life suffers severely (Finch and Narod., 2011). At present, the common approach is hormone replacement therapy (HRT). However, researches about the application of HRT to patients with epithelial ovarian cancer after surgery are rare. Its security has not been systematically certified by bulk of clinical researches. Clinical application is subject to certain restriction (MacLennan, 2011). Therefore, it is necessary to find a more safe and effective way to solve the problem that patients with epithelial ovarian cancer lose ovarian function after surgery.

In the early 1960s, it was reported that freezing and thawing ovary was autologously transplanted to rats and the rats became pregnant successfully. Since then, successes in sheep model were reported successively. In 1999, some scholars even autologously transplanted ovarian cortex to human body after cryopreservation and observed ovulation. In 2001, Radford, for the first time, transplanted freezing and thawing ovary to patients with Hodgkin lymphoma to recover ovulatory function (Radford et al., 2001). And it was the first time that freezing and thawing ovary transplantation was used to recover endocrine function of ovary for patients with malignant tumors. With the development of last decades, ovarian tissue freezing and thawing technology as well as transplantation technology has been very mature. Recent years, many scholars tried to transplant freezing and thawing ovaries to patients with leukemia, breast cancer, cervical cancer, Hodgkin's lymphoma, colon cancer and osteosarcoma, in order to recover ovarian function

<sup>1</sup>Department of Gynecology, <sup>2</sup>Research Center, Hainan Provincial People's Hospital, <sup>3</sup>Drug Safety Evaluation Center, Hainan Medical College, Haikou, Hainan, China \*For correspondence: genhai@163.com

(Georgescu et al., 2008; Donnez et al., 2011; Donnez and Dolmans, 2011). Although these studies have no long-term follow-up results and risk assessments, at least they can demonstrate that freezing and thawing ovarian tissue transplantation is an effective way to restore ovarian endocrine function of some patients with malignant tumors. So it is assumed that the freezing and thawing ovarian tissue transplantation can also be used to restore the ovarian function of patients with epithelial ovarian cancer after surgery. But reports about freezing and thawing ovarian transplantation to patients with epithelial ovarian cancer after surgery have not been seen yet. That may be caused by the particularity of epithelial ovarian cancer which is different from other malignancies. The autologous transplantation of ovarian tissue to patients with epithelial ovarian cancer has a high risk of reimplantation of cancer cells.

In order to solve the problem of reimplantation of cancer cells, some scholars use primordial follicle for cell culture. Though it is reported that some of them succeeded, success rate is low and this method is mainly used for in vitro fertilization rather than the recovery of ovarian endocrine function of patients with malignancies after surgery. Theoretically, cancer cells reimplantation can also be solved by using specific gene markers of ovarian cancer cells. However, ovarian cancer is regulated by polygenes. Unique ovarian cancer specific gene has not been discovered yet. Is there a relatively safe way to circumvent the reimplantation of residual tumor cells or cells with subclinical metastasis tendency? In order to avoid residual cancer cells reimplantation to the maximum extent, it is very important to screen and acquire safe normal ovarian tissue for transplantation. Recent studies confirmed that the reverse transcription polymerase chain reaction (RT-PCR) and immunohistochemistry technique are effective measures to screen residual cancer focus, micrometastasis and occult metastasis (Stranahan et al., 2009; Dolmans et al., 2010). Among numerous ovarian cancer related genes, which should be chosen as the indicators for detection? Meirow reported that expressions of CD30, T cell receptor and BCR-ABL gene were detected for examinations of residual micro focus of transplanted ovarian tissues in patients with Hodgkin's disease, lymphoma and leukemia respectively (Meirow et al., 2008). These disease-related genes play a relatively good role in monitoring. This research indicates that indicators can be screened among related genes which mediate erosion and metastasis of ovarian cancer. Cytokeratin-7(CK-7), CA125, matrix metalloproteinase-2/tissue inhibitor of metalloproteinase-2 (MMP2/TIMP-2), survivin and P53 are a series of genes, which are used commonly in clinical application and have relatively positive functions of mediating erosion and metastasis of cancers (Takami et al., 2012). And they are relatively ideal molecular indicators for screening residual cancer cells or predicting occult metastasis. On the basis of these difficulties and gaps in research, nude mice with orthotopic transplantation of human ovarian epithelial cancer were used to imitate clinical process of freezing and thawing ovary transplantation to patients with ovarian epithelial cancer after surgery. The feasibility and safety

was investigated. This provided an alternative safe and effective way to solve the problem that patients with epithelial ovarian cancer lost ovarian endocrine function after surgery.

## Materials and Methods

### Materials

Human epithelial ovarian cancer OVCAR3 cell line (American Type Culture Collection, ATCC) (Manassas, VA), fetal calf serum, RPMI-1640 culture solution (Invitrogen, CA).

Female BALB/c nude mice, bought from Experimental Animal Center of Guangdong Province, aged from 4 to 6 weeks, weight 15-17g, fed in SPF(special pathogen free) level barrier system, feed and bedding material were sterilized. All of people who entered the laboratory as well as the materials had to undergo a strict microbiological control.

P53: Rabbit anti-human P53 monoclonal antibody, No.: ZA-0501, Clone No.: EP95; survivin: Rabbit anti-human survivin monoclonal antibody, No.: ZA-0530, Clone No.: EP119; CK-7, Mouse anti-human CK-7 monoclonal antibody, No.: ZM-0071, Clone No.: OV-TL12/30; CA125: Mouse anti-human CA125 monoclonal antibody, No.: ZM-0019, Clone No.: OC125; MMP2: Mouse anti-human MMP2 monoclonal antibody, No.: ZM-0330, Clone No.: OC125; TIMP-2: Rabbit anti-human TIMP-2 monoclonal antibody, No.: H-140, Clone No.: ZS5539; Secondary antibody reagent: Immunohistochemical dyeing kit, Concentrated DAB kit. Primary antibodies and secondary antibodies above were all bought from Beijing Zhongshan Golden Bridge Biotechnology Co., Ltd..

Total RNA extraction kit (RNeasy Minikit) was bought from QIAGEN Co., RT-PCR kit, primer and internal control etc. were bought from Shanghai Sangon Biological Engineering Co., Ltd.

Preparation and related reagents of vitrification freezing solution and thawing solution: Dimethyl sulfoxide (DMSO), ethylene glycol(EG), Dulbecco's phosphate buffered saline(DPBS) and cane sugar were bought from Sigma Co., fetal calf serum (Invitrogen, CA). DPBS, containing 10% fetal bovine serum, was used as base solution; freezing pre-equilibrium solution: 10% EG+10% DMSO+base solution; freezing solution: 20% EG+20% DMSO+0.5 mol/Lcane sugar+base solution; thawing solution: a, b, c were 0.5 mol/L, 0.25 mol/L, 0.125 mol/L cane sugar respectively, d was base solution.

### Methods

**Cell culture:** After anabiosis, culture solution was added into cell line, which was centrifuged at low speed then. Supernate was removed. RPMI-1640 culture solution, containing 10% newborn calf serum, 200 u/ml penicillin and 200 u/ml streptomycin, was added. Then cell line was subcultured at 37 °C, in the condition of 5 % CO<sub>2</sub>.

Building and grouping of orthotopic transplantation tumor model of human epithelial ovarian cancer in nude mice (1) Tumor source: OVCAR3 cells in logarithmic growth phase were digested with 0.25% trypsin, then

culture solution, without fetal calf serum, was added to prepare cell suspension. After centrifugation, PBS was added to re-suspend cells.  $2 \times 10^6/0.1$  ml cell suspension was prepared. 0.2 ml suspension was subcutaneously inoculated to each nude mice on the back of neck near the armpit. A total of 10 nude mice were inoculated. Tumor formation rate was 90% in 4-8 weeks. Tumors were diagnosed by pathological biopsy. Subcutaneous tumor source was fetched and trimmed into 1mm×1mm×1mm tissue blocks under sterile condition. (2) Building of orthotopic transplantation tumor model: Mice were narcotized with 1% sodium pentobarbital at a dose of 45 mg/kg body weight. Small tumor blocks were inoculated in left ovarian capsule under the microscope. OB gel was dropped on the surface. When the gel solidified, ovarian capsule was put back into the abdominal cavity. The subcutaneous layer and skin were sutured with No.0 silk thread. A total of 45 nude mice were inoculated. Tumor formation rate of orthotopic inoculation was 40 mice and the success rate was 88.9%. (3) Anatomy: 4weeks after orthotopic inoculation, 10 nude mice were dissected every two weeks. Tumor size, bilateral ovaries involvement, ascites, inoculation extent of abdominopelvic cavity, abdominal para-aortic lymph nodes metastasis and etc. were recorded. The ovary with tumor was detached. The tumor tissue was equidistantly divided into 3 pieces from paraneoplastic tissue to non-cancer direction under microscope. They were respectively proximal paraneoplastic tissue, middle paraneoplastic tissue and remote paraneoplastic tissue. Each section was cut into 1mm thickness thin slices of tissue successively. Part of each thin slice of tissue was got for pathological biopsy. Ovaries, detected to be normal by biopsy, were reserved for immunohistochemical detection and RT-PCR detection. The excess tissues were grouped and cryopreserved by vitrification method for screening and transplantation. Meanwhile, 20 nude mice were prepared as a control group. They accepted the same surgical operation and were transplanted in situ with normal ovarian tissues of nude mice.

**Immunohistochemical detection:** Two-step immunohistochemical detection proceeded in accordance with kit instructions. Antibodies, which were detected, included CK-7, CA125, P53, survivin, MMP-2 and TIMP-2. Standard for evaluation of immunohistochemical results: The positive expression manifested claybank particles in cytoplasm, cell membrane or nucleus. P53 was expressed mainly in nucleus. CK-7, MMP-2 and TIMP-2 were primarily expressed in cytoplasm. CA125 was primarily expressed in cytoplasm or cell membrane. Survivin was mainly expressed in nucleus or cytoplasm. 5

high-power fields of each section were observed randomly. In accordance with the standard, staining intensity and the proportion of positive cells under high power lens were synthesized for semi-quantitative treatment. Standard for evaluation of staining intensity: non-staining, 0 point; yellow, 1 point; claybank, 2 points; nigger-brown, 3 points. Standard for evaluation of the proportion of positive cells: the number of positive cells<10%, 0 point; 10%-40%, 1 point; 40%-70%, 2 points; ≥70%, 3 points. The two scores were summed up. Then, 0-1 point was expressed as (-); 2 points was marked as (+); 3-4 points was marked as (++); 5-6 points was marked as (+++); (+++) was defined as strong positive.

**Semi-quantitative RT-PCR detection:** Frozen tissues for detection were fetched and ground into powder at liquid nitrogen temperature. Designated buffer was added and then they were centrifuged. Supernatant was used for one-step extraction of total RNA according to RNeasy Minikit instructions. Then total RNA was reverse-transcribed into cDNA with Superscript II according to kit instructions. Genes, detected by semi-quantitative RT-PCR, contained CK-7, CA125, P53, survivin, MMP-2 and TIMP-2.  $\beta$ -Actin was used as an internal control. Primer sequences of CK-7, CA125, MMP2/TIMP-2, survivin and P53 are shown in Table 1.

**Cryopreservation by vitrification of paraneoplastic normal ovarian tissues for transplantation:** Tissues were fetched under sterile condition and trimmed into 1mm×1mm×1mm tissue blocks. They were washed with PBS for 3 times. Then ovary tissue blocks were removed to pre-equilibrium solution. Osmotic equilibrium proceeded at ambient temperature for 20 minutes. After that, ovary tissue blocks were removed to freezing solution. Osmotic equilibrium proceeded for another 10 minutes. 2 tissue blocks were placed in a 0.25 ml straw which were then stored in liquid nitrogen directly.

**Anabiosis of tissues:** The straw was got out from liquid nitrogen tank and placed at ambient temperature for 30 seconds. Then it was put in 30 °C water bath to thaw. When freezing solution thawed, ovarian tissue blocks were successively removed to thawing solution a, b and c. And each process lasted for 10 min at ambient temperature. Eventually, tissues were rinsed twice with base solution. Each time lasted for 5 min. Then tissue blocks were put in a 37 °C incubator for 30 min. After that, tissue blocks could be transplanted or fixed.

**Activity assessment of tissues for transplantation:** Part of anabiotic ovarian tissues were made into paraffin sections. After HE staining, the morphology and structure of follicles, oocytes and granular cells were observed. Tissue sections would be discarded, if the following

**Table 1. The Primer Sequences of CK-7, CA125, MMP2/TIMP-2, Surviving and P53**

Primer	sense	antisense	length (bp)
$\beta$ -actin	AAGCAGGAGTATGACGAGTCCG	GCCTTCATACATCTCAAGTTGG	559
survivin	CCGCAACTGAGATTGTGGGAAT	GGATCATCTGCCTGAGTATAAT	301
MMP2	CCTGTCTTGGCTGCATAGGT	CGATTCTGCCCTCCTCCTTCG	102
TIMP-2	TGGCAGACTACAATACAAGAGC	AGATGTGGTAGGAGATGATGGG	140
CA125	CCCCTACACTGGCGAAGA	GGTGGCTTCTGAAGTGGC	101
CK-7	GTTCCATTTGCAAAGGCTGT	CAGGTGGTTATCCCGAAAGA	292
P53	AGGACCCTGTCACCGAGA	GTGGAAGCCATAGTTGCC	125

conditions happened: morphology of follicles was irregular; pyknosis of oocytes appeared; morphology of granulosa cells was abnormal and distribution was uneven.

**Preparation of castrated nude mice:** 240 castrated nude mice were prepared in batches. 120 of them were prepared for subcutaneous transplantation, and others were prepared for orthotopic transplantation. Method: Female nude mice, which were aged from 4 to 6 weeks and weighted from 15 to 17 g, were narcotized with 1% sodium pentobarbital at the dose of 45 mg/kg. Then operative field on the back was disinfected. Horizontal incision was made below bilateral costal arch. Then ovaries were cut off. Nude mice for orthotopic transplantation were marked by suture at the position where the original ovaries were cut off.

**Transplantation of ovarian tissue:** According to the number of ovarian tissues actually obtained and different situations, ovarian tissues were grouped as the followings: (1) RT-PCR negative group: Expressions of CK-7, CA125, P53, survivin, MMP-2 and TIMP-2 were all detected to be negative by RT-PCR. In accordance with this standard, 21 paraneoplastic normal ovarian tissues were screened out. One of them manifested pyknosis of oocyte after freezing and thawing. Therefore, this group contained 20 cases. (2) Immunohistochemistry negative group: Expressions of CK-7, CA125, P53, survivin, MMP-2 and TIMP-2 were all detected to be negative by immunohistochemistry. In accordance with this standard, 23 paraneoplastic normal ovarian tissues were screened out. 3 of them manifested irregular morphology of follicle and pyknosis of oocyte. Therefore, this group contained 20 cases. (3) CK-7, CA125 and survivin negative group: Expressions of CK-7, CA125 and survivin were all detected to be negative by RT-PCR and immunohistochemistry. 22 cases in all. (4) CK-7, CA125 and survivin positive group: Expressions of CK-7, CA125 and survivin were all detected to be positive by RT-PCR and immunohistochemistry. 12 cases in all. (5) Cancer tissue: tumor tissues by orthotopic transplantation of nude mice with human epithelial ovarian carcinoma. 20 cases in all. (6) Ovarian tissues of normal nude mice: 20 cases in all. Tissues were subcutaneously transplanted in batches according to the grouping: After intraperitoneal narcotization with 1% sodium pentobarbital, 2 resuscitated tissue blocks were subcutaneously transplanted to the back of neck of nude mice near the armpit; Orthotopic transplantation: After enterocoelia narcotization, operative field on the back of mice was disinfected. Horizontal incision was made below bilateral costal arch under the microscope. Line knot which indicated the position of ovary cut before was found in peritoneal cavity. Peritoneal

around the line knot near the uterus was cut open. Then, 2 resuscitated ovarian tissue blocks were placed in it. And OB gel was dropped on the surface. subcutaneous layer and skin were sutured layer by layer. Cancer tissue was defined as the positive control. Normal ovarian tissue of nude mice was defined as the blank control and accepted the same operation. Mice which were transplanted were all fed in SPF level barrier system for 3 months.

**Main indicators for detection after transplantation**  
**Carcinogenesis rate:** Canceration of ovarian tissue after transplantation was detected by HE staining; Occult carcinogenesis rate: Duo to the relatively high expression specificity of CK-7, CA125 and survivin in epithelial ovarian cancer tissues, if one or more of them were detected to be positive by RT-PCR and immunohistochemistry, occult cancer was confirmed. While routine pathological examination result was normal.

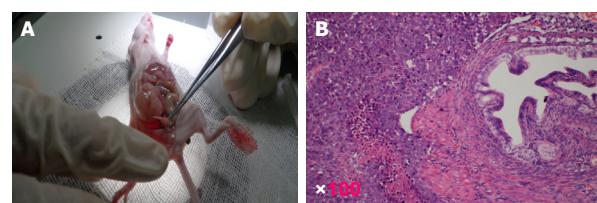
#### Statistical analysis

Results were shown by percentage. The comparisons of rates were tested by  $\chi^2$ . SPSS 13.0 was used for statistical analysis.  $P < 0.05$  meant that differences were statistically significant.

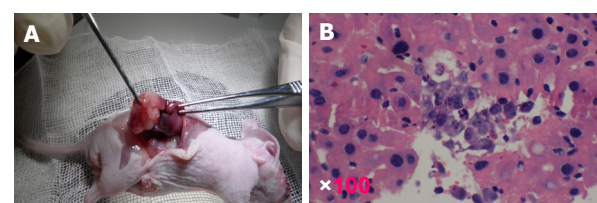
## Results

#### Involvement extent of orthotopic ovarian transplantation tumor and gain rate of residual normal ovarian tissue

Tumors of ovarian cancer appeared 2 weeks after inoculation. Wide range metastasis, including metastasis of liver, intestines, peritoneum, lymph node etc. and ascites, appeared 8 weeks after inoculation. 87.5% (35/40)



**Figure 1. Model and Cell Morphology of Ovarian Orthotopic Transplantation Tumor (HE x100)**



**Figure 2. Liver Metastasis and Cell Morphology of Ovarian Orthotopic Transplantation Tumor (HE x100)**

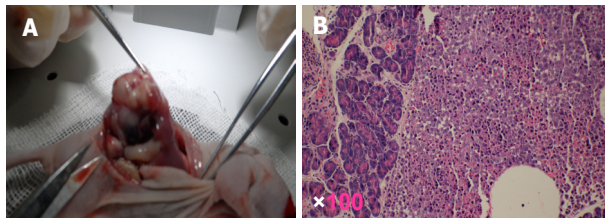
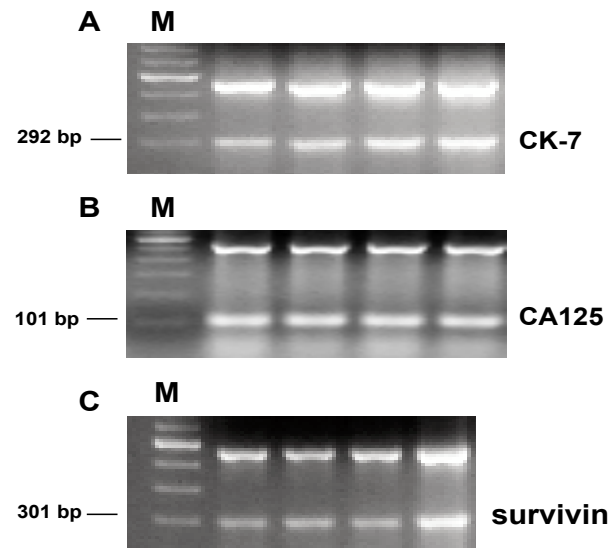
**Table 2. Canceration Involvement Extent of Orthotopic Ovarian Transplantation and Gain Rate of Residual Normal Ovarian Tissue**

	2 weeks	4weeks	6 weeks	8 weeks
Dissected cases	10	10	10	10
Only ovarian transplantation	10(10)	4(4)	1(1)	0
Liver metastasis	0	2(2)	2(2)	2(2)
Intestine metastasis	0	2(2)	3(3)	1(1)
Ascites	0	2(1)	2(1)	3(2)
Retroperitoneal lymph node metastasis	0	0	1(1)	2(1)
Wide range metastasis	0	0	1(1)	2(1)
Gain rate of residual normal ovarian tissue (%)	10(100%)	9(90%)	9(90%)	7(70%)

**Table 3. Cancer Rate and Occult Cancer Rate after Transplantation of Ovarian Tissues Which were Screened out under Different Conditions (Cases, %)**

	Subcutaneous transplantation			Orthotopic transplantation		
	Cases	Cancer rate	Occult cancer rate	Cases	Cancer rate	Occult cancer rate
RT-PCR negative group	20	0(0)	2(10.0) <sup>a</sup>	20	0(0)	2(10.0) <sup>a</sup>
Immunohistochemistry negative group	20	0(0)	1(5.0) <sup>b</sup>	20	0(0)	2(10.0) <sup>b</sup>
CK-7, CA125 and survivin negative group	22	0(0)	1(5.0) <sup>c</sup>	22	0(0)	2(10.0) <sup>c</sup>
CK-7, CA125 and survivin positive group	12	4(33.3)	6(50.0)	12	5(41.7)	6(50.0)
Cancer tissue	20	18(90.0)	0(0)	20	17(85.0)	0(0)
Normal ovarian tissue of nude mice	20	0(0)	0(0)	20	0(0)	0(0)

a, b, c: Comparing with CK-7, CA125 and survivin positive group, P<0.01

**Figure 3. Intestine Metastasis and Cell Morphology of Ovarian Orthotopic Transplantation Tumor (HE×100)****Figure 4. Semi-quantitative RT-PCR electrophoretogram of CK-7, CA125 and survivin in transplanted tissues**

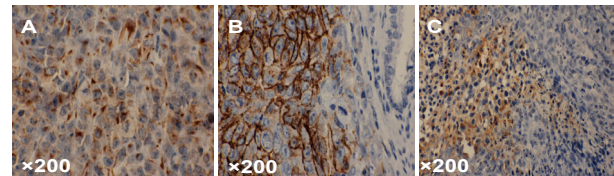
of them had ovarian tissues which were detected to be normal by pathology detection. These tissues might have potential of metastasis and should be further screened. (Table 2, Figure 1, Figure 2, Figure 3)

#### Screening results of paraneoplastic normal ovarian tissues by RT-PCR

Pieces of tissues for transplantation, in which the expressions of CK-7, CA125, P53, survivin, MMP-2 and TIMP-2 were all negative, were screened out by RT-PCR from proximal paraneoplastic tissues, middle paraneoplastic tissues and remote paraneoplastic tissues.

#### Screening results of paraneoplastic normal ovarian tissues by immunohistochemistry

23 pieces of tissues for transplantation, in which the expressions of CK-7, CA125, P53, survivin, MMP-2

**Figure 5. Expressions of CK-7, CA125 and Survivin in Transplanted Tissues Immunohistochemistry Two-step Method ×200. A. CK-7: Claybank particles appeared in cytoplasm; B. CA125: Claybank particles appeared in cytoplasm or cell membrane; C. survivin: Claybank particles appeared in nucleus or cytoplasm**

and TIMP-2 were all negative, were screened out by immunohistochemistry from proximal paraneoplastic tissues, middle paraneoplastic tissues and remote paraneoplastic tissues.

#### Cancer rates and occult cancer rates after transplantation of ovarian tissues which were screened out under different conditions

Tissues, in which the expressions of all the indicators or main indicators, including CK-7, CA125 and survivin, were negative, did not cancerate after transplantation. And occult cancer rate was also lower than that of the group, in which the expressions of main indicators, including CK-7, CA125 and survivin, were positive (Table 3, Figure 4, Figure 5).

#### Carcinogenesis rates and occult carcinogenesis rates after ovarian tissue transplantation in different transplantation positions

Situations of the above groups, except cancer tissue and normal ovarian tissue of nude mice, were counted after subcutaneous transplantation and orthotopic transplantation. It was found that cancer rates as well as occult cancer rates had no statistical significance.

#### Cancer rates and occult cancer rates after transplantation of ovarian tissues which were gained under different severities

Situations after transplantation of ovarian tissues, which were gained under the conditions of only ovarian inoculation and outside ovarian inoculation, in all negative groups, excluding cancer tissue, normal ovarian tissue of nude mice as well as CK-7, CA125 and survivin expression negative group, were counted. It was found that there was no statistical significance between cancer rates of the two groups as well as occult cancer rates.

## Discussion

Autologous transplantation of ovarian tissue has been used in a variety of malignant tumors to restore ovarian function, but there are several problems which limit the tentative application of autologous transplantation of ovarian tissues in epithelial ovarian cancer treatment. First, whether enough normal ovarian tissues for transplantation can be get from ovaries of patients with epithelial ovarian cancer. Second, whether there is a dependable method or technology to screen out normal ovarian tissues, so that re-transplantation of residual cancer cells or cells with subclinical metastasis tendency can be avoided. Third, whether canceration or occult canceration of screened tissues will occur after transplantation.

It was shown in this research that tumors of 15 cases were limited in ovaries and outside ovarian inoculation, including liver metastasis, intestines metastasis, ascites, retroperitoneal lymph node metastasis and wide range metastasis, of 25 cases happened in 40 ovarian orthotopic transplantation tumor models. 35 pieces of ovarian tissues which were detected to be normal by biopsy were obtained, which suggested that there was still a chance to obtain normal ovarian tissues for transplantation under the condition of wide range metastasis. However, in that case, residual normal ovarian tissues obtained was relatively less. In clinical practice, it is common that normal ovarian tissues without invasion can be found in ipsilateral or contralateral ovary of patients with epithelial ovarian cancer. Actually, it is reported that some patients with advanced ovarian cancer accept large resection of foci and their residual tissues have normal function and metastasis does not appear after surgery (Miller et al., 1997; Dykgraaf et al., 2009). These residual normal ovarian tissues may contain residual cancer cells or have potential metastasis tendency. How to further screen? Recent studies have confirmed that RT-PCR and immunohistochemical techniques are effective methods for the screening of residual foci, micrometastasis and occult metastasis. Some tumor related genes are often used to screen residual cancer cells and occult metastasis. In related genes which mediate invasion and metastasis of ovarian tissues, the expression of CK-7 is relatively stable in primary ovarian cancer or metastases from ovaries. CK-7 is a common indicator to judge whether the metastases are from ovaries (Heatley, 2008). CA125 is a common tumor marker for epithelial ovarian cancer and its expression is relatively high in ovarian tumor tissues. CA125 is often used to identify whether there are residual foci after chemotherapy of ovarian cancer and to further identify negative tissues of routine pathological examination (Miller et al., 2008). Almost all highly malignant epithelial ovarian cancers have mutant P53 expression. And P53 has been a target gene of epithelial ovarian cancer treatment (Rahma et al., 2012). There is no expression or a low expression of survivin gene in normal tissues, and it is a common molecular indicator for monitoring of tumor metastasis, efficacy judgment and prognosis (Felisiak-Golabek et al., 2011). Because adhesion and extracellular matrix (ECM) degradation is the first step of ovarian cancer invasion and metastasis,

the expression of MMP-2/TIMP-2 is relatively high in epithelial ovarian cancer tissues, which is different from other members of MMPs/TIMP family. The expression of MMP-2/ TIMP-2 is low in benign ovarian tumor tissues (Brun et al., 2008). These genes are tested by many clinical and experiment researches. They are relatively mature and have certain representativeness. They can be used as good molecular indicators for screening residual cancer foci and predicting occult metastasis. CK-7, CA125, P53, survivin, MMP-2, TIMP-2 and other indicators were detected by RT-PCR and immunohistochemistry. Tissues, in which these indicators were all negative, were used for transplantation. Due to the high expression specificity of CK-7, CA125 and survivin in epithelial ovarian cancer tissues, CK-7, CA125 and survivin negative group and positive group were simultaneously used for transplantation. Changes were observed after transplantation. Results showed that cancer rate and occult cancer rate of transplanted tissues, which were screened out by RT-PCR and immunohistochemistry, were close to those of normal control group. That suggested that these screened tissues were safe for transplantation and both RT-PCR and immunohistochemistry could be used to screen tissues for transplantation. From a security perspective, the two methods were similar. Both methods had advantages and disadvantages. Cell morphology could be observed by immunohistochemistry, but organic solvent in filmmaking process might cause that part of antigen in tissues lost and the sensibility of results were affected. However, sensibility of RT-PCR was relatively high, but morphology of tumor cells could not be observed. At present, immunohistochemistry are more common in clinical practice. Immunohistochemistry can be the main method for screening residual cancer foci and occult metastasis (Lotz et al., 2011). Cancer rate and occult cancer rate of transplanted tissues, in which CK-7, CA125 and survivin were negative, were as same as those of the group, in which all indicators were negative, as well as normal control group. While cancer rate and occult cancer rate of CK-7, CA125 and survivin positive group were relatively high after transplantation, which suggested that the combination of CK-7, CA125 and survivin was valuable to screening residual cancer foci and predicting canceration and occult canceration after transplantation. Common sites of ovarian tissue transplantation include subcutaneous transplantation and orthotopic transplantation. Do different transplantation sites affect canceration and occult canceration of transplanted tissues? This experiment result showed that survival rate of orthotopic transplantation was slightly higher than that of subcutaneous transplantation, while cancer rates and occult cancer rates had no difference. That suggested that survival rate might be partly affected by transplantation environment, due to the difference of pressure and blood supply. But canceration was not affected. Both sites were safe for transplantation. This experiment result also showed that cancer rate and occult cancer rate of transplanted ovarian tissues which were obtained under the condition of outside ovarian inoculation, including liver metastasis, intestines metastasis, ascites, retroperitoneal lymph node metastasis and wide range metastasis, were

as same as those of tissues obtained under the condition of ovarian metastasis only. Reproductive function reservation of ovarian germ cell tumor in clinical stage III did not increase the risk of recurrence (Al-Sayed et al., 2011), which suggested that severity was not a factor of canceration as long as the screening standard of molecular indicator was reached.

It is undoubtedly safe that all 6 indicators, including CK-7, CA125, P53, survivin, MMP-2 and TIMP-2, in ovarian tissues for transplantation are detected by both RT-PCR and immunohistochemistry. But RT-PCR is mostly used in experimental study, due to false positive results, which is caused by template pollution, and false negative results, which is caused by poorly controlled experimental conditions. It is not commonly used in clinical application. RT-PCR detection needs more tissues. Comparing with RT-PCR, immunohistochemistry has certain advantages. In security aspect, combination of CK-7, CA125 and survivin and all the indicators have the same screening efficiency. Therefore, detection of CK-7, CA125 and survivin by immunohistochemistry can be used as security screening standard of ovarian tissues for transplantation.

## Acknowledgements

This study was supported by National Natural Science Foundation (30960408).

## References

- Al-Sayed MM, El-Sayed AA, El-Barbary TM, et al (2011). Conservative surgery in patients with malignant ovarian germ cell tumours. *J Egypt Soc Parasitol*, **41**, 737-44.
- Brun JL, Cortez A, Commo F, et al (2008). Serous and mucinous ovarian tumors express different profiles of MMP-2, -7, -9, MT1-MMP, and TIMP-1 and -2. *Int J Oncol*, **33**, 1239-46.
- Dolmans MM, Marinescu C, Saussoy P, et al (2010). Reimplantation of cryopreserved ovarian tissue from patients with acute lymphoblastic leukemia is potentially unsafe. *Blood*, **116**, 2908-14.
- Donnez J, Dolmans MM (2011). Preservation of fertility in females with haematological malignancy. *Br J Haematol*, **154**, 175-84.
- Donnez J, Squifflet J, Jadoul P, et al (2011). Pregnancy and live birth after autotransplantation of frozen-thawed ovarian tissue in a patient with metastatic disease undergoing chemotherapy and hematopoietic stem cell transplantation. *Fertil Steril*, **95**, 1787.e1-4.
- Dykgraaf RH, de Jong D, van Veen M, et al (2009). Clinical management of ovarian small-cell carcinoma of the hypercalcemic type: a proposal for conservative surgery in an advanced stage of disease. *Int J Gynecol Cancer*, **19**, 348-53.
- Felisiak-Golabek A, Rembiszewska A, Rzepecka IK, et al (2011). The Polish Ovarian Cancer Study Group (POCSG). Nuclear survivin expression is a positive prognostic factor in taxane-platinum-treated ovarian cancer patients. *J Ovarian Res*, **4**, 20.
- Finch A, Narod SA (2011). Quality of life and health status after prophylactic salpingo-oophorectomy in women who carry a BRCA mutation: review. *Maturitas*, **70**, 261-5.
- Georgescu ES, Goldberg JM, du Plessis SS, et al (2008). Present and future fertility preservation strategies for female cancer patients. *Obstet Gynecol Surv*, **63**, 725-32.
- Heatley MK (2008). Immunohistochemical biomarkers of value in distinguishing primary ovarian carcinoma from gastric carcinoma: a systematic review with statistical meta-analysis. *Histopathology*, **52**, 267-76.
- Lotz L, Montag M, van der Ven H, et al (2011). Xenotransplantation of cryopreserved ovarian tissue from patients with ovarian tumors into SCID mice--no evidence of malignant cell contamination. *Fertil Steril*, **95**, 2612-4.
- MacLennan AH (2011). HRT in difficult circumstances: are there any absolute contraindications? *Climacteric*, **14**, 409-17.
- Meirou D, Hardan I, Dor J, et al (2008). Searching for evidence of disease and malignant cell contamination in ovarian tissue stored from hematologic cancer patients. *Hum Reprod*, **23**, 1007-13.
- Michelsen TM, Pripp AH, Tonstad S, et al (2009). Metabolic syndrome after risk-reducing salpingo-oophorectomy in women at high risk for hereditary breast ovarian cancer: a controlled observational study. *Eur J Cancer*, **45**, 82-9.
- Miller DM, Ehlen TG, Saleh EA (1997). Successful term pregnancy following conservative debulking surgery for a stage IIIA serous low-malignant-potential tumor of the ovary: a case report. *Gynecol Oncol*, **66**, 535-8.
- Miller K, Price JH, Dobbs SP, et al (2008). An immunohistochemical and morphological analysis of post-chemotherapy ovarian carcinoma. *J Clin Pathol*, **61**, 652-7.
- Radford JA, Lieberman BA, Brison DR, et al (2001). Orthotopic reimplantation of cryopreserved ovarian cortical strips after high-dose chemotherapy for Hodgkin's lymphoma. *Lancet*, **357**, 1172-5.
- Rahma OE, Ashtar E, Czystowska M, et al (2012). A gynecologic oncology group phase II trial of two p53 peptide vaccine approaches: subcutaneous injection and intravenous pulsed dendritic cells in high recurrence risk ovarian cancer patients. *Cancer Immunol Immunother*, **61**, 373-84.
- Stranahan D, Cherpelis BS, Glass LF, et al (2009). Immunohistochemical stains in Mohs surgery: a review. *Dermatol Surg*, **35**, 1023-34.
- Takami H, Sentani K, Matsuda M, et al (2012). Cytokeratin expression profiling in gastric carcinoma: clinicopathologic significance and comparison with tumor-associated molecules. *Pathobiology*, **79**, 154-61.