

A comparison of different gingival depigmentation techniques: ablation by erbium:yttrium-aluminum-garnet laser and abrasion by rotary instruments

Kwang-Myung Lee¹, Dong-Yeol Lee¹, Seung-Il Shin¹, Young-Hyuk Kwon^{1,2}, Jong-Hyuk Chung^{1,2}, Yeek Herr^{1,2,*}

Department of ¹Periodontology, ²Institute of Oral Biology, Kyung Hee University School of Dentistry, Seoul, Korea

Purpose: The aim of this study is to compare two different gingival depigmentation techniques using an erbium:yttrium-aluminum-garnet (Er:YAG) laser and rotary instruments.

Methods: Two patients with melanin pigmentation of gingiva were treated with different gingival depigmentation techniques. Ablation of the gingiva by Er:YAG laser was performed on the right side, and abrasion with a rotary round bur on the opposite side.

Results: The patients were satisfied with the esthetically significant improvement with each method. However, some pigment still remained on the marginal gingival and papilla. The visual analog scale did not yield much difference between the two methods, with slightly more pain on the Er:YAG laser treated site.

Conclusions: The results of these cases suggest that ablation of the gingiva by an Er:YAG laser and abrasion with a rotary round bur is good enough to achieve esthetic satisfaction and fair wound healing without infection or severe pain. Prudent care about the gingival condition, such as the gingival thickness and degree of pigmentation along with appropriate assessment is needed in ablation by the Er:YAG laser procedure.

Keywords: Hyperpigmentation, Lasers, Melanins, Pigmentation.

INTRODUCTION

Oral pigmentation is a discoloration of the oral mucosa or gingiva associated with several exogenous and endogenous factors. Oral pigmented lesions can have various etiologies, including drugs, heavy metals, genetics, endocrine disturbance, and inflammation [1-3]. Also, smoking may stimulate melanin production and cause melanin pigmentation [3-5]. The intensity of the pigmentation is related to the duration

of smoking and number of cigarettes consumed [6]. This type of oral pigmentation is mostly located in the anterior labial gingiva, affecting females more than males [1,5].

Melanin pigmentation is caused by melanin granules in gingival tissue, which are produced in melanosomes of melanocytes. Melanocytes are primarily located in the basal and suprabasal cell layers of the epithelium [1-3,7]. The color of the oral melanin pigmentation may vary from light to dark brown or black, depending on the amount and distribution

Received: Jun. 14, 2011; **Accepted:** Jul. 16, 2011

***Correspondence:** Yeek Herr

Department of Periodontology, Institute of Oral Biology, Kyung Hee University School of Dentistry, 1 Hoegi-dong, Dongdaemun-gu, Seoul 130-701, Korea

E-mail: yherr@khu.ac.kr; Tel: +82-2-958-9380, Fax: +82-2-958-9387

Copyright © 2011 Korean Academy of Periodontology

This is an Open Access article distributed under the terms of the Creative Commons Attribution Non-Commercial License (<http://creativecommons.org/licenses/by-nc/3.0/>).

www.jpis.org | pISSN 2093-2278
eISSN 2093-2286

of melanin in the tissue [2]. In addition, the oral pigmentation is due to the activity of melanocytes rather than the number of melanocytes in the tissue [8]. Although physiologic melanin pigmentation is not a medical problem, patients may complain that their black gums are unesthetic. Numerous procedures have been developed for depigmentation of the gingiva, such as epithelial abrasion [9], free gingival graft [10], gingivectomy [8], cryosurgery [11-13], acellular dermal matrix allograft [14], and laser surgery [15-19].

Recently, many techniques using various lasers have been introduced and many studies have reported the use of the laser for depigmentation. Laser ablation for gingival depigmentation has been recognized as one of the most effective, comfortable, and reliable techniques [17]. The erbium:yttrium-aluminum-garnet (Er:YAG) laser, which has been used widely in dentistry, also can be applied to depigmentation and many cases have been presented about its effectiveness. The Er:YAG laser has been studied and applied effectively to periodontal soft tissue management without causing major thermal damage. The Er:YAG laser has a wavelength of 2,940 nm, and the rate of absorption of this laser's energy by water is high. Because of the high energy absorption by water, Er:YAG laser irradiation results in minimal heating of the tissue and surroundings [20-22]. This minimal damage prevents scarring and enables favorable wound healing [23].

This case report compares two different depigmentation techniques for removing melanin pigmentation of gingiva: The Er:YAG laser was used on the right side, while on the other side the epithelium was removed with a rotary round bur. Moreover, the post-operative results were evaluated clinically on a weekly basis. Through this case report, the effectiveness of the Er:YAG laser in depigmentation of hyperpigmented oral lesions can be evaluated. This study was approved by the Institutional Review Board of Kyung Hee University Dental Hospital (IRB number: KHD IRB 003-3).

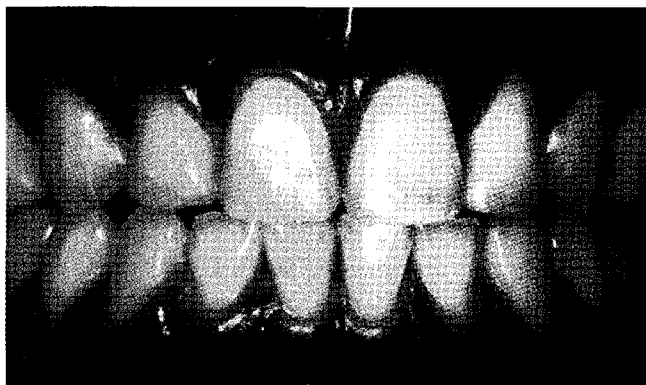


Figure 1. Case 1: pre-operative view. Diffused melanin hyperpigmentation was observed.

CASE DESCRIPTION

Case 1

A 27-year-old male who had a chief complaint of unesthetic melanin pigmentation in the anterior part of the maxillary and mandibular gingiva visited the Department of Periodontology, School of Dentistry, Kyung Hee University. There was no remarkable medical history, but he had been smoking a pack of cigarettes per day on average for the last 10 years. Diffused melanin hyperpigmentation was found on the labial surface of both the maxillary and mandibular arches (Fig. 1).

For the comparison of the two techniques, melanin pigmentation was removed bilaterally: on the right side Er:YAG laser therapy was used, while on the other side the epithelium was mechanically removed with a rotary round bur.

Ablation by Er:YAG laser

The patient was treated with local anesthesia (lidocaine 2% with 1:80,000 epinephrine). The Er:YAG laser (KaVo KEY Laser, KaVo Dental GmbH, Biberach, Germany) was set at 250 mJ, 15 Hz and non-contact method. The handpiece tip was kept 10 mm away from the tissue in defocusing mode. The laser beam was activated using the 'brush technique,' as described by Tal et al. [17], with continuous movement of the beam overlapping the laser spots by approximately 20 to 30%. The laser was cautiously used to avoid injury to the tooth surface or adjacent tissues during the ablation. The papillary edges and free gingival margins were left untreated to decrease the risk of gingival recession.

Abrasion by rotary round bur

A high speed handpiece and round carbide bur were used for abrasion on the other side. Abrasion under water spray over an epithelial layer was performed until whitish connective tissue was exposed. A # 2 round bur was used to draw the outline of the pigmented lesion and # 6 round bur was used

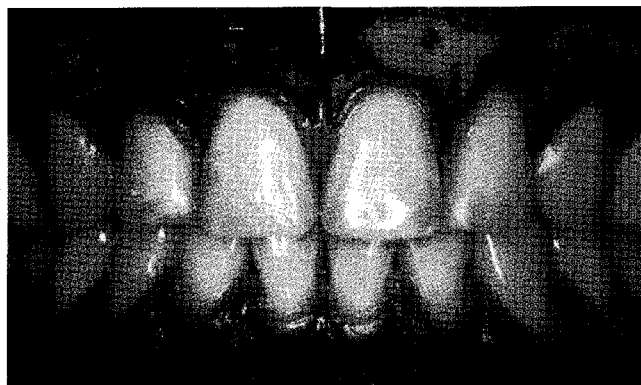

Figure 2. Post-operative view.

for abrasion. All the melanin remnants of the epithelium were completely removed to prevent the possibility of recurrence (Fig. 2).

Upper jaw surgery was conducted 2 weeks prior to mandibular surgery. After surgery, the denuded connective tissue was covered with a periodontal pack. The procedure time was recorded on each quadrant and the visual analog scale (VAS) was also recorded to evaluate the subjective pain level. The VAS consisted of a horizontal line 100 mm long, anchored at the left end by the descriptor 'no pain' and at the other end by 'unbearable pain'. The patient was asked to mark the severity of the pain by him/herself. The distance between the left end to the point checked was recorded in millimeters and used as the VAS score. In addition, clinical parameters, such as wound healing, gingival color, pain, discomfort and tissue deformity, were recorded at 24 hours and 1, 2, 3 and 4 weeks after the procedure. The time spent on ablation of the gingiva by the Er:YAG laser was about 20 to 30 minutes on each quadrant, while that on abrasion with the rotary instruments was about 10 to 15 minutes.

One day after surgery, the patient reported slight pain on both sides with distinct irritation on the right side. Post-op-

erative bleeding was not observed, and the connective tissue was still exposed with whitish sloughing (Fig. 3). After 1 week, neither side showed full epithelization, with slightly more advanced recovery on the left side, which had been treated with the rotary instruments (Fig. 4). After 2 weeks, re-epithelization was almost complete but had epithelium had not recovered its thickness yet (Fig. 5). After 4 weeks, the gingiva showed a normal appearance with pink color and keratinization (Fig. 6).

The patient was satisfied with the significant improvement in color. Tissue deformities, e.g., gingival recession and loss of papilla, were not observed after 4 weeks because the papillary edges and free gingival margins were left untreated. However, some pigments remained on the marginal gingiva and papillary area (Fig. 7).

Case 2

A 32-year-old female who requested cosmetic therapy for "black gum" in the anterior part of the mandibular gingiva visited the Department of Periodontology, School of Dentistry, Kyung Hee University. There were no contributory medical problems. Melanin hyperpigmentation was found

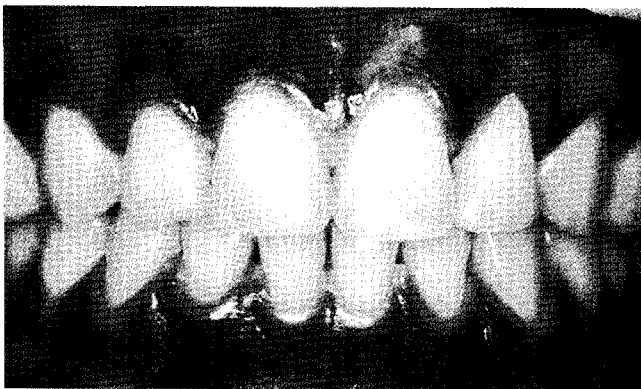

Figure 3. Postoperative view (1 day later). The connective tissue was still exposed.

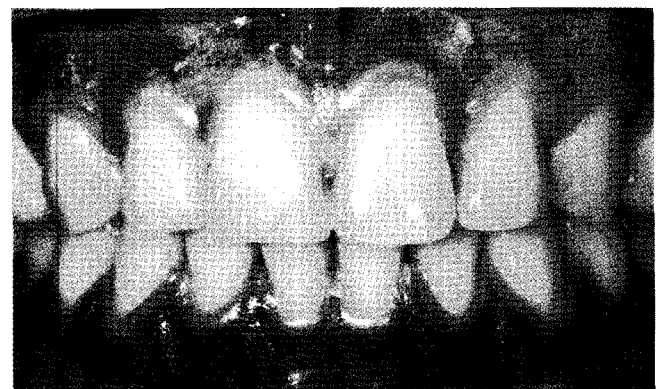


Figure 4. Postoperative view (1 week later).

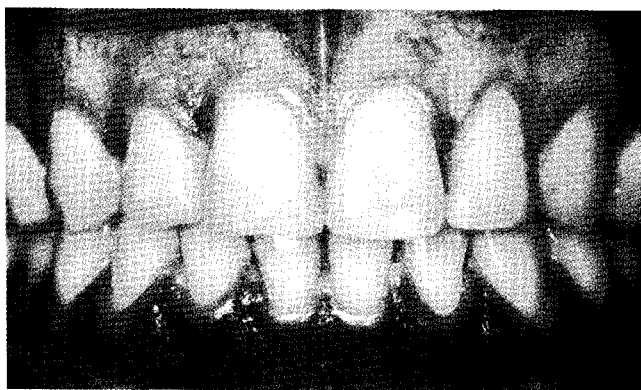


Figure 5. Postoperative view (2 weeks later). Re-epithelization was almost complete but the epithelium had not yet recovered its thickness.

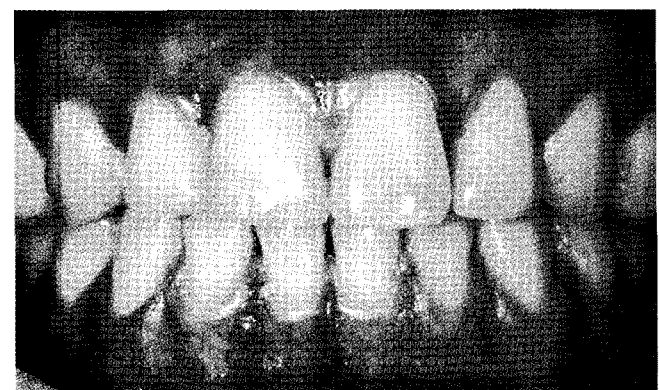


Figure 6. Postoperative view (upper jaw, 4 weeks later; lower jaw, 2 weeks later).

on the labial surface of the mandibular arches and maxillary lateral incisor. Compared with case 1, pigmentation showed more focal pigmented lesions (Fig. 8).

The same depigmentation techniques were applied: the Er:YAG laser on the right side and mechanical depigmentation of rotary round bur on the left side. Since the patient had

focal pigmentation, depigmentation was conducted on both the maxilla and mandible area simultaneously. Due to the patient's thin gingival biotype and careless laser application, case 2 showed exposure of underlying bone around the incisal area on the right side of the mandible (Fig. 9).

At 1 week, the gingiva showed gradual epithelization, but

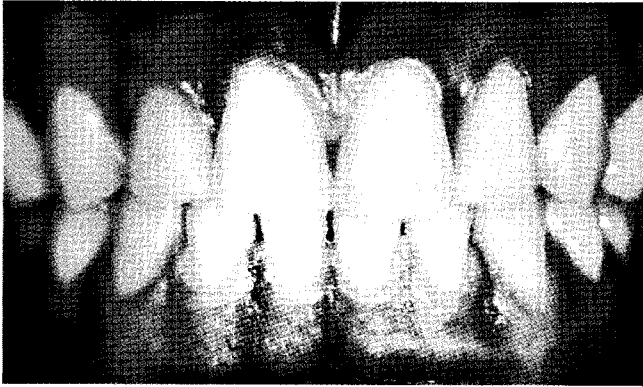

Figure 7. Postoperative view (upper jaw, 5 weeks later; lower jaw, 3 weeks later). The gingiva showed a normal appearance with a pink color and keratinization.

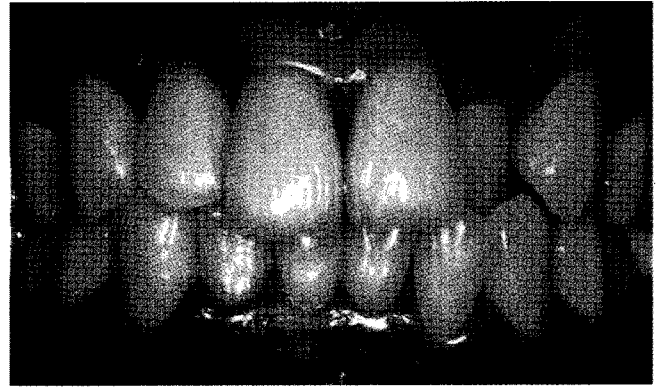


Figure 8. Case 2: preoperative view. The patient showed focal pigmentation.

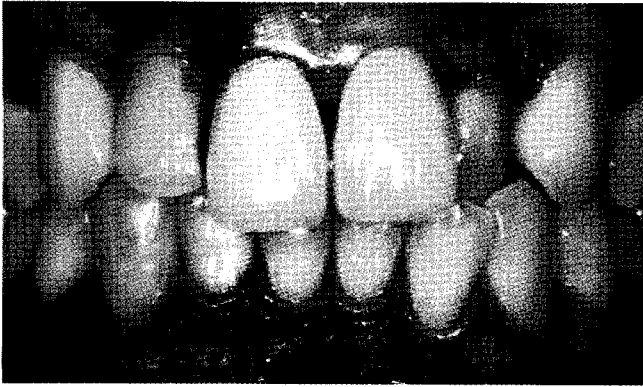


Figure 9. Postoperative view. Exposure of underlying bone can be observed around the incisal area on the right mandible. Arrows show the exposed area.

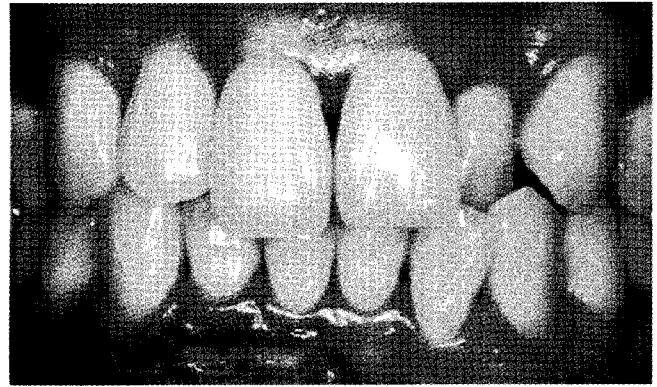


Figure 10. Postoperative view (1 week later). Unfavorable healing is observed with the appearance of necrosis on the right side of the mandibular area.

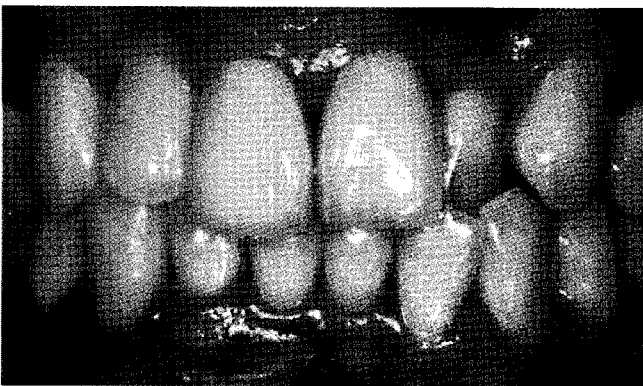


Figure 11. Postoperative view (2 weeks later).

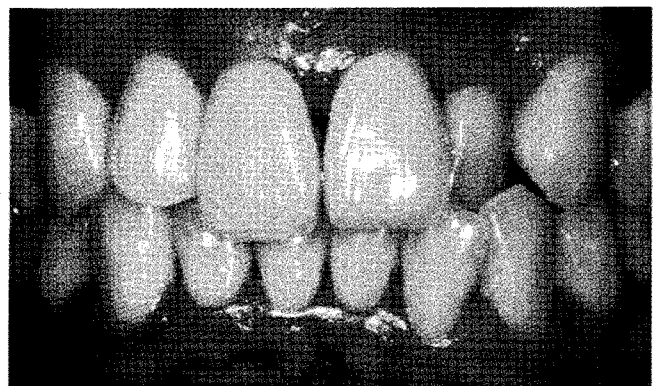


Figure 12. Post-operative view (4 weeks later). The wound healing was almost completed, but slight redness remained.

Table 1. Visual analog scale (VAS) value assessment on each quadrant.

VAS pain score (0-100)	Maxillary area		Mandibular area	
	Right (laser)	Left (round bur)	Right (laser)	Left (round bur)
Case 1	15	10	25	20
Case 2	10	10	25	20

was in an immature state. The laser surgery area showed redness and unfavorable healing with an appearance of necrosis. On the other hand, on the left side where the high speed rotary was applied, almost complete re-epithelization was observed (Fig. 10). After 2 weeks, epithelization was completed except in the right mandibular area (Fig. 11). A linear cleft was observed in the right mandibular area until 3 weeks. The wound healing was almost completed, but slight redness still remained at 4 weeks after surgery. However, the patient was satisfied with the significant improvement in color. Gingival recession and loss of papilla were not observed at 4 weeks after surgery (Fig. 12).

DISCUSSION

Gingival melanin pigmentation causes esthetic concerns, and cosmetic therapy is becoming important for patients suffering from this problem. Recently, various laser techniques were introduced, and the Er:YAG laser has proven its effectiveness in depigmentation by ablation of pigmented gingiva [17-19]. Case 1 and 2 elicited the difference between ablation by the Er:YAG laser and mechanical depigmentation by a rotary high speed handpiece.

Laser devices are of use in various fields of dentistry. Among them, the Er:YAG laser is applied in treatment of both hard and soft tissue. Because of the Er:YAG laser's high absorption by water, less tissue degeneration with very thin surface interaction occurs after Er:YAG laser irradiation than after irradiation with other types of lasers. Because of this characteristic, use of an Er:YAG laser can minimize the damage to deep tissue and prevent scarring from the laser application. It is also favorable for wound healing and has a bacteriocidal effect [24] and provides photobiostimulation (low-level laser therapy) [25,26].

Not much difference was observed in patients' subjective pain as measured by the VAS. The mandibular part showed relatively more pain than the maxilla, and the Er:YAG laser-treated site showed more pain than the mechanically depigmented area (Table 1). In wound healing, the mechanically depigmented area showed faster epithelization than the Er:YAG laser-treated site. These results can be explained by several factors. Even though the Er:YAG laser inflicts little

heat damage on adjacent tissue, the damage that does occur cannot be neglected. Also the treatment time of ablation with Er:YAG laser using 'brush technique' was twice as long as abrasion with the rotary round bur.

Technical difficulty should be taken into account in using the Er:YAG laser for de-epithelization. Most of the melanin and melanocytes are located in the basal and suprabasal cell layer of the epithelium. Generally, the range of ablation is limited to within the epithelium. The wavelength of the Er:YAG laser corresponds to the absorption coefficient of water, causing water to evaporate into steam in the tissue, resulting in microexplosions. Due to these microexplosions, an exact and uniform depth control is required. During the Er:YAG laser application, remnants of vaporized tissue should be removed with sterile gauze for proper visualization. This cleaning procedure facilitates careful and complete removal of the pigmented tissue. On the other hand, mechanical abrasion with a rotary round bur enabled clear observation and a distinctive endpoint of epithelial elimination because there was no carbonization or protein coagulum formation caused by laser usage.

Bone exposure on the mandibular area caused by the Er:YAG laser can be explained by microexplosions of laser. The patient in case 2 had a severe thin biotype and mild pigmented lesion compared with the patient in case 1. Due to the thin thickness of the epithelial layer, uniform and stable epithelial elimination using microexplosions was difficult to achieve. This caused bone exposure on the mandible and, combined with heat damage of adjacent tissue, resulted in poor wound healing.

The severe hyperpigmentation of case 1 showed a definite color difference after elimination of the melanin in the basal layer. However, the mild pigmentation of case 2 was difficult to distinguish from protein coagulum during laser therapy.

In summary, depigmentation using an Er:YAG laser can be technique-sensitive, especially for patients with a thin biotype.

Even though patients were satisfied with the esthetic results, some pigmentation still remained on the marginal gingiva and papilla because the epithelium of the papillary edges and free gingival margins were not removed perfectly. Effective spot size for Er:YAG laser therapy is about 1 mm and this figure is not fine enough for minute treatment of the gingival margin, including the papilla. A diamond bur with a sharp-ending or hyperfine round bur is suggested for complete removal of pigmented lesions.

A limitation of this case report is that more time should have been spent for longer observation in case of a relapse. Recurrence of pigmentation has been reported in many studies using various techniques [8-10,15,27]; thus clinicians should be aware of the possibility of repigmentation. Con-

tinuous observation with a longer period can confirm the possibility of repigmentation.

Both cases showed almost complete depigmentation and similar esthetic results. Ablation and abrasion techniques were good enough to achieve esthetic satisfaction and fair wound healing without infection or pain. Prudent care about the gingival condition, such as gingival thickness and degree of pigmentation along with appropriate assessment is needed in ablation by the Er:YAG laser procedure.

In this case report, Er:YAG laser ablation and mechanical removal were compared and both depigmentation methods showed satisfactory results with regard to esthetics, safety, and effectiveness. A periodic check and assessment should be conducted to confirm the recurrence of melanin pigmentation.

CONFLICT OF INTEREST

No potential conflict of interest relevant to this article was reported.

REFERENCES

1. Kauzman A, Pavone M, Blanas N, Bradley G. Pigmented lesions of the oral cavity: review, differential diagnosis, and case presentations. *J Can Dent Assoc* 2004;70:682-3.
2. Mirowski GW, Waibel JS. Pigmented lesions of the oral cavity. *Dermatol Ther* 2002;15:218-28.
3. Meleti M, Vescovi P, Mooi WJ, van der Waal I. Pigmented lesions of the oral mucosa and perioral tissues: a flow-chart for the diagnosis and some recommendations for the management. *Oral Surg Oral Med Oral Pathol Oral Radiol Endod* 2008;105:606-16.
4. Hedin CA, Pindborg JJ, Axéll T. Disappearance of smoker's melanosis after reducing smoking. *J Oral Pathol Med* 1993;22:228-30.
5. Hedin CA, Axéll T. Oral melanin pigmentation in 467 Thai and Malaysian people with special emphasis on smoker's melanosis. *J Oral Pathol Med* 1991;20:8-12.
6. Araki S, Murata K, Ushio K, Sakai R. Dose-response relationship between tobacco consumption and melanin pigmentation in the attached gingiva. *Arch Environ Health* 1983;38:375-8.
7. Eisen D. Disorders of pigmentation in the oral cavity. *Clin Dermatol* 2000;18:579-87.
8. Perlmutter S, Tal H. Repigmentation of the gingiva following surgical injury. *J Periodontol* 1986;57:48-50.
9. Farnoosh AA. Treatment of gingival pigmentation and discoloration for esthetic purposes. *Int J Periodontics Restorative Dent* 1990;10:312-9.
10. Tamizi M, Taheri M. Treatment of severe physiologic gingival pigmentation with free gingival autograft. *Quintessence Int* 1996;27:555-8.
11. Tal H, Landsberg J, Kozlovsky A. Cryosurgical depigmentation of the gingiva. A case report. *J Clin Periodontol* 1987;14:614-7.
12. Yeh CJ. Cryosurgical treatment of melanin-pigmented gingiva. *Oral Surg Oral Med Oral Pathol Oral Radiol Endod* 1998;86:660-3.
13. Arikan F, Gürkan A. Cryosurgical treatment of gingival melanin pigmentation with tetrafluoroethane. *Oral Surg Oral Med Oral Pathol Oral Radiol Endod* 2007;103:452-7.
14. Pontes AE, Pontes CC, Souza SL, Novaes AB Jr, Grisi MF, Taba M Jr. Evaluation of the efficacy of the acellular dermal matrix allograft with partial thickness flap in the elimination of gingival melanin pigmentation. A comparative clinical study with 12 months of follow-up. *J Esthet Restor Dent* 2006;18:135-43.
15. Nakamura Y, Hossain M, Hirayama K, Matsumoto K. A clinical study on the removal of gingival melanin pigmentation with the CO₂ laser. *Lasers Surg Med* 1999;25:140-7.
16. Atsawasuwan P, Greethong K, Nimmanon V. Treatment of gingival hyperpigmentation for esthetic purposes by Nd:YAG laser: report of 4 cases. *J Periodontol* 2000;71:315-21.
17. Tal H, Oegiesser D, Tal M. Gingival depigmentation by erbium:YAG laser: clinical observations and patient responses. *J Periodontol* 2003;74:1660-7.
18. Rosa DS, Aranha AC, Eduardo Cde P, Aoki A. Esthetic treatment of gingival melanin hyperpigmentation with Er:YAG laser: short-term clinical observations and patient follow-up. *J Periodontol* 2007;78:2018-25.
19. Azzeh MM. Treatment of gingival hyperpigmentation by erbium-doped:yttrium, aluminum, and garnet laser for esthetic purposes. *J Periodontol* 2007;78:177-84.
20. Aoki A, Sasaki KM, Watanabe H, Ishikawa I. Lasers in non-surgical periodontal therapy. *Periodontol* 2000 2004;36:59-97.
21. Ishikawa I, Sasaki KM, Aoki A, Watanabe H. Effects of Er:YAG laser on periodontal therapy. *J Int Acad Periodontol* 2003;5:23-8.
22. Watanabe H, Ishikawa I, Suzuki M, Hasegawa K. Clinical assessments of the erbium:YAG laser for soft tissue surgery and scaling. *J Clin Laser Med Surg* 1996;14:67-75.
23. Berger JW, D'Amico DJ. Modeling of erbium: YAG laser-mediated explosive photovaporization: implications for vitreoretinal surgery. *Ophthalmic Surg Lasers* 1997;28:133-9.
24. Ando Y, Aoki A, Watanabe H, Ishikawa I. Bactericidal effect of erbium YAG laser on periodontopathic bacteria. *Lasers*

- Surg Med 1996;19:190-200.
25. Ozcelik O, Cenk Haytac M, Kunin A, Seydaoglu G. Improved wound healing by low-level laser irradiation after gingivectomy operations: a controlled clinical pilot study. *J Clin Periodontol* 2008;35:250-4.
 26. Qadri T, Miranda L, Tunér J, Gustafsson A. The short-term effects of low-level lasers as adjunct therapy in the treatment of periodontal inflammation. *J Clin Periodontol* 2005;32:714-9.
 27. Esen E, Haytac MC, Oz IA, Erdoğan O, Karsli ED. Gingival melanin pigmentation and its treatment with the CO₂ laser. *Oral Surg Oral Med Oral Pathol Oral Radiol Endod* 2004;98:522-7.