

Testicular Epidermoid Cyst on Diffusion-Weighted MR Imaging and ADC Map : A Case Report

Mi Sun Kim¹, Kyung Ah Kim², Sun Hee Chang³

Testicular epidermoid cyst is a rare benign tumor, accounting for 1-2% of all testicular tumors. It can be cured by organ preserving surgery, so accurate preoperative diagnosis is very important for preventing unnecessary and extensive orchiectomy. We experienced a case of an 18-year-old man who presented with a painless lump in his right testis. The testicular mass showed an onion ring sign on ultrasonography. Computed tomography images showed the mass as a low attenuating lesion with curvilinear calcification. On Magnetic resonance imaging (MRI), the mass appeared as high signal intensity with internal alternating low signal intensity patterns on T2-weighted images. The mass was displayed as having homogeneous high signal intensity on diffusion magnetic resonance imaging and showed lower apparent diffusion coefficient values than normal testis parenchyma, similar to intracranial epidermoid cysts. Testicular MRI with DWI and ADC map can help to more accurately diagnose testicular epidermoid cyst.

Index words : Epidermoid cyst
Testis
Diffusion weighted imaging
Magnetic resonance imaging (MRI)

Introduction

Epidermoid cyst is a rare benign tumor, which accounts for 1-2% of all testicular tumors (1). It can be cured by organ preserving surgery.

We experienced a case of pathologically confirmed testicular epidermoid cyst, which showed typical onion

ring appearance on ultrasonography (US) and high signal intensity with internal alternating low signal intensity patterns on T2-weighted magnetic resonance imaging (MRI). The mass revealed homogeneous high signal intensity on diffusion weighted imaging (DWI) and low apparent diffusion coefficient (ADC) value. DWI is designed to detect Brownian motion of water molecules within tissues. It is a useful imaging tool to

JKSMRM 15:154-159(2011)

¹Department of Radiology, Ilsan Paik Hospital, Inje University College of Medicine

²Department of Radiology, Yonsei University College of Medicine

³Department of Pathology, Ilsan Paik Hospital, Inje University College of Medicine

Received; May 13, 2011, revised; June 21, 2011, accepted; July 14, 2011

Corresponding author : Kyung Ah Kim, M.D., Department of Radiology, Yonsei University College of Medicine,

134 Shinchon-dong, Seodaemun-gu, Seoul 120-752, Korea.

Tel. 82-2-2228-7400 Fax. 82-2-393-3035 E-mail: bellena@daum.net

differentiate malignancy from benign lesions (2). In the field of neuroradiology, finding of diffusion restriction has been known to be useful in diagnosing epidermoid cysts (3).

We illustrate imaging features including DWI, and ADC maps and the pathologic findings of testicular epidermoid cysts.

Case Report

An 18-year-old man presented with a nontender and

palpable mass in the right testis. An elastic and firm mass without tenderness was palpable in the middle portion of the right hemiscrotum on physical examination. There was no evidence of erythema on the overlying skin or palpable lymphadenopathy. He had no history of trauma or other medical history. Sex hormones, α -fetoprotein and β -human chorionic gonadotropin on laboratory studies were within normal range.

He underwent gray scale and Doppler US of the scrotum (Fig. 1). The mass showed alternating

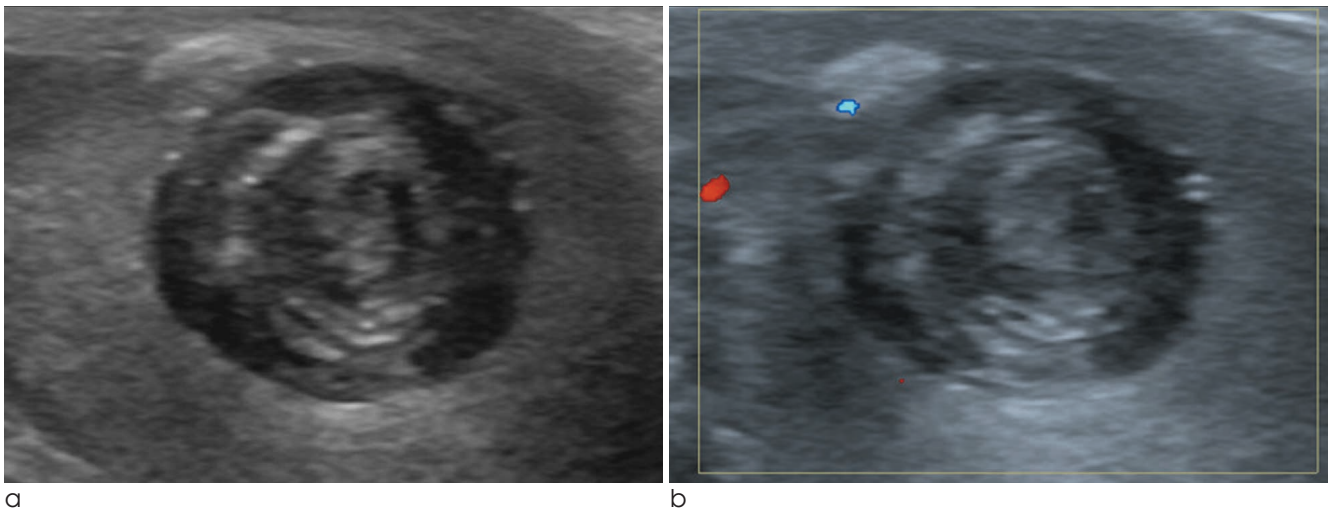


Fig. 1. Ultrasonography (US) finding for the testicular epidermoid cyst. (a) Gray scale transverse US reveals a well-circumscribed intratesticular mass in the mid portion of right testis. It shows alternating rings of hyper- and hypoechogenicities. (b) Doppler US reveals no vascularity in the mass.

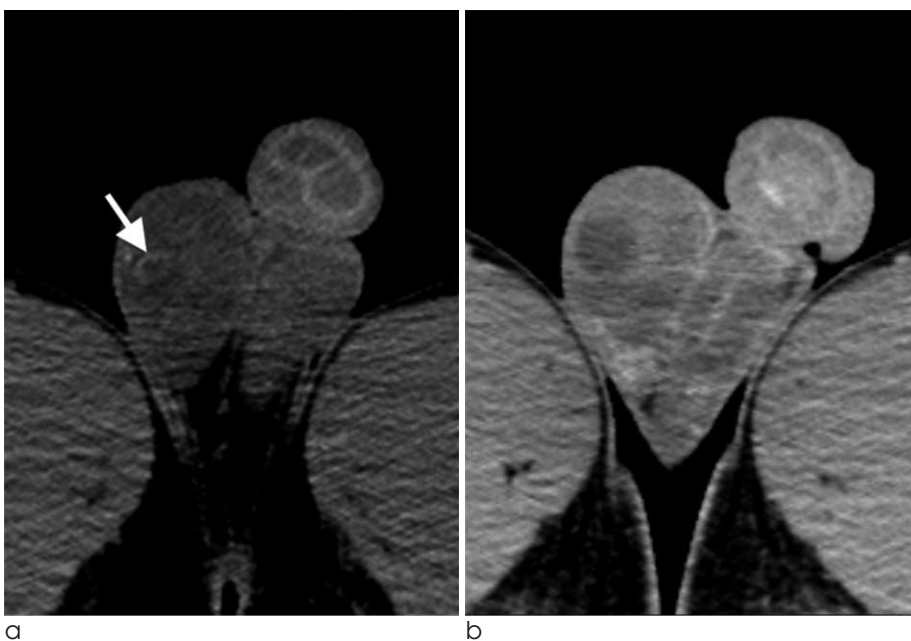


Fig. 2. CT shows a well-defined non-enhancing cystic mass in the right testis. (a) Non-enhanced axial CT image reveals focal curvilinear calcification (arrow). (b) Enhanced axial CT image shows no enhancement of the mass.

concentric rings of hypo- and hyperechogenicities with hypoechoic rim, which has been termed the 'onion ring' appearance. No vascularity was detected within the testicular mass on Doppler US study. The left testis was normal. Precontrast CT images revealed curvilinear calcification in the periphery of the testicular mass (Fig. 2A). Region of interest of the mass was measured as 25–30 HU. The testicular mass showed no enhancement on contrast-enhanced CT images (Fig. 2B). There was no evidence of significantly enlarged lymph nodes or imaging findings indicating metastasis. We considered testicular epidermoid cyst, testicular teratoma or other testicular tumors as initial diagnosis. Scrotal MRI was performed for further evaluation of the mass (Fig. 3). The mass showed low signal intensity with low signal peripheral rim on T1-weighted images. T2-weighted images revealed high

signal intensity with alternating concentric and linear low signal intensity rings that was similar to the onion ring sign on the US. The mass lacked an enhancing solid portion or fat component, which is usually detected in teratomas. DWI was obtained at b-values of 50 and 800 sec/mm². The mass showed high signal intensity on DWI with the low b-value of 50 sec/mm² without signal drop in the high b-value of 800 sec/mm², and lower ADC values than normal parenchyma of the testis.

Organ preserving surgery of the right testis was performed. A well-encapsulated mass of 2×2 cm in size was disclosed in the right scrotal sac and was resected. The resected mass was filled with friable and yellow-whitish materials (Fig. 4A). Upon microscopic examination, the cyst was found to be lined by squamous epithelium with a granular cell layer and

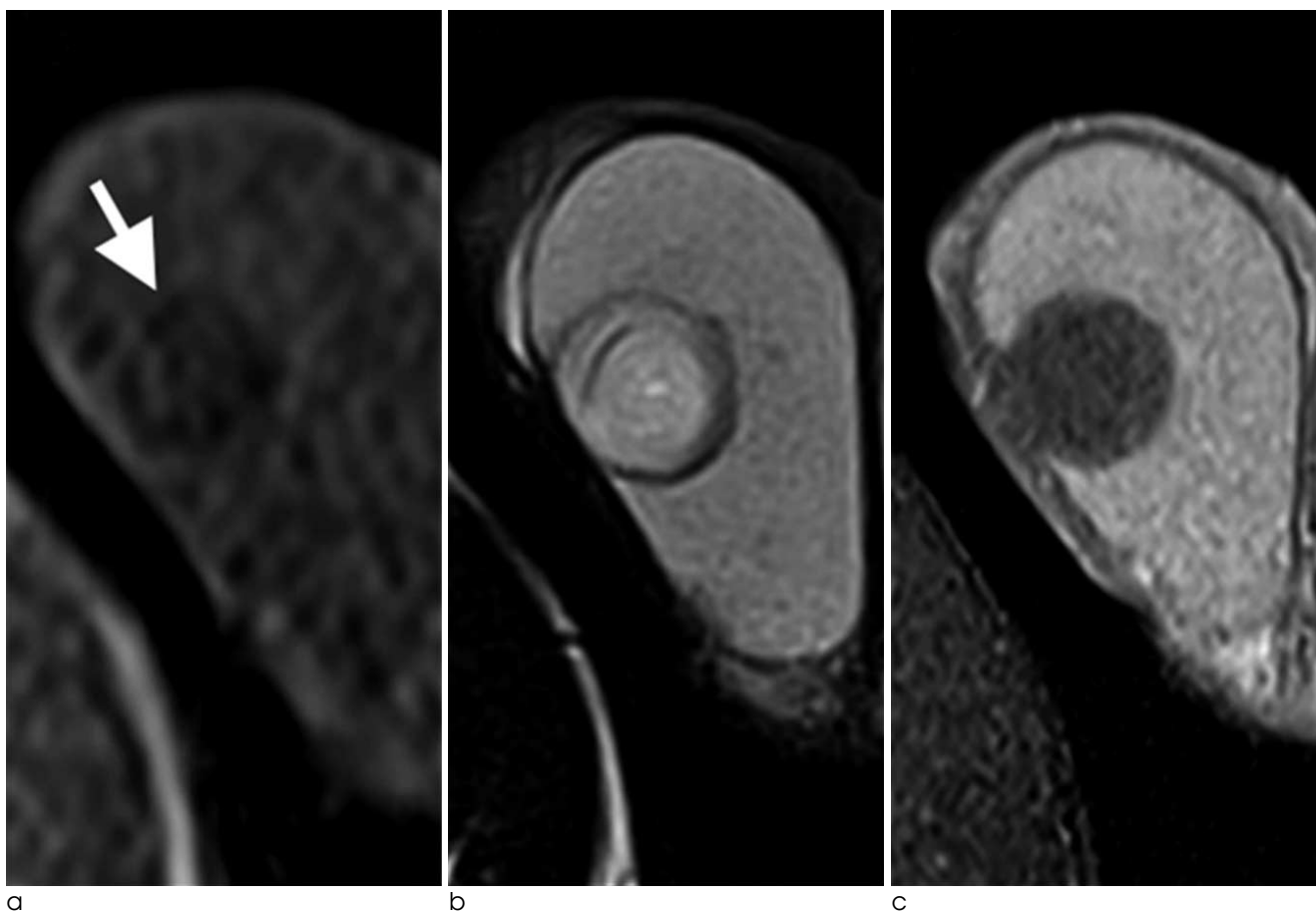
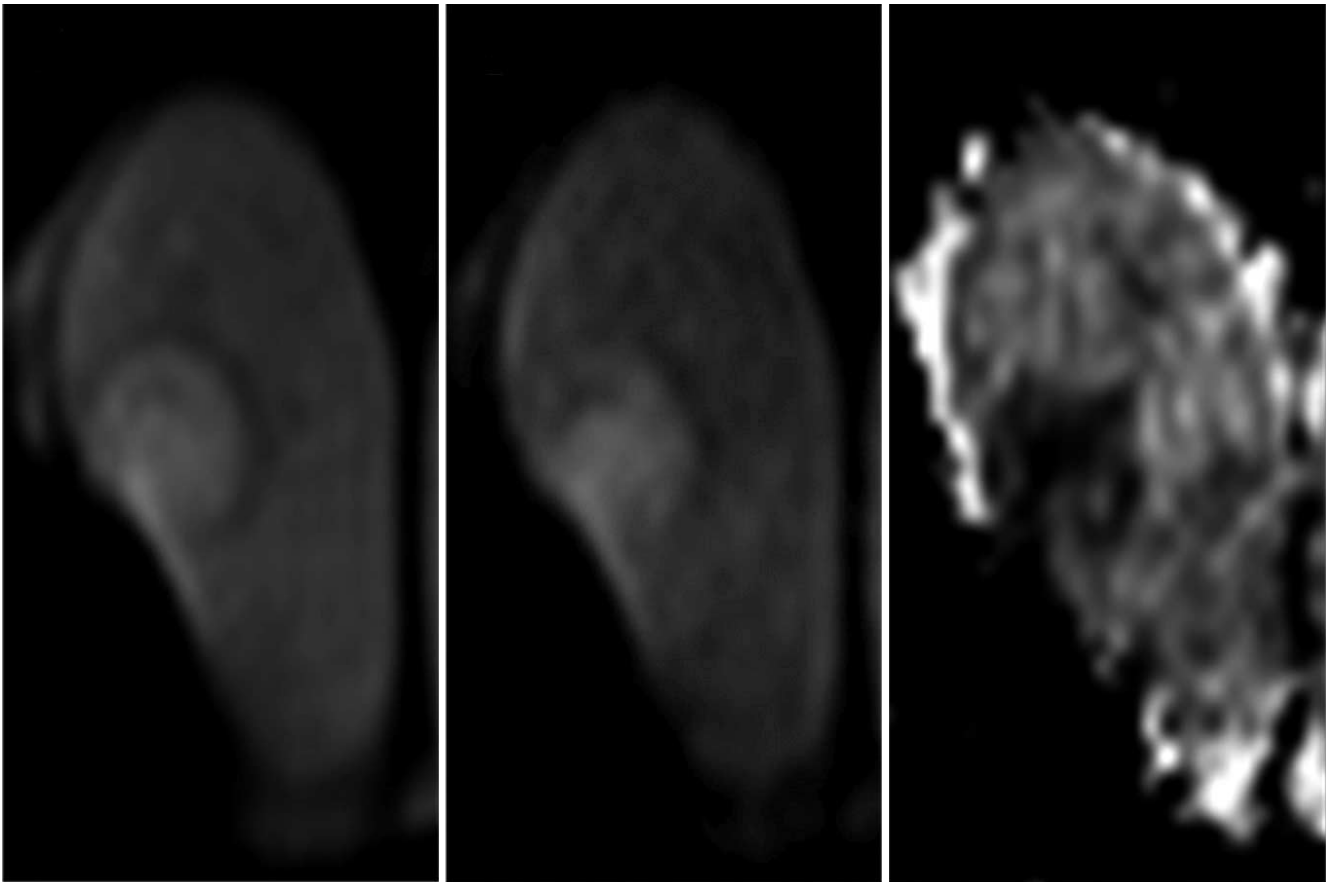
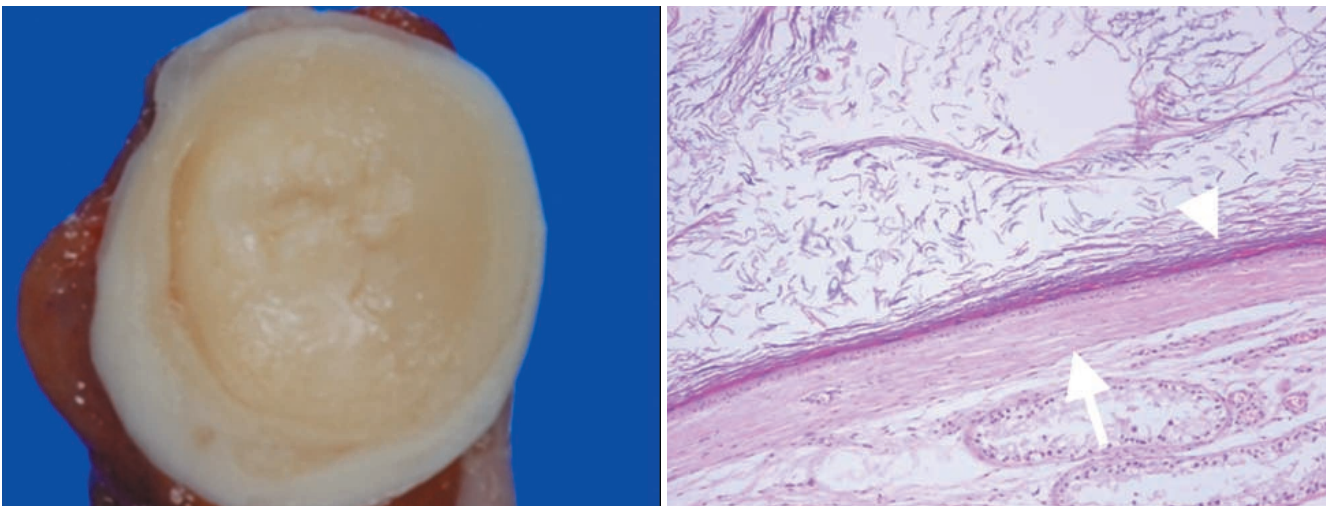


Fig. 3. MR images of the testicular epidermoid cyst. (a) Axial T1-weighted image (TR/TE 90/4.9) shows a well-circumscribed low signal intensity mass with a low signal rim (arrow). (b) Axial T2-weighted image (TR/TE 3000/92) shows high signal intensity with multi-layered concentric low signal rings. Peripheral low signal rim is seen on both T1-weighted image and T2-weighted image. (c) Axial gadolinium-enhanced T1-weighted fat suppression image (TR/TE 724/9.6) shows no contrast enhancement.



d e f
Fig. 3. (d, e) DWI shows higher signal intensity in the tumor than in the adjacent normal testicular parenchyma (b-value 50, 800). (f) ADC map shows lower ADC values than in the normal testicular parenchyma.



a b
Fig. 4. (a) Gross specimen reveals a well-encapsulated whitish mass of 2×2 cm in size. (b) Upon microscopic examination, the wall of the testicular mass is lined by squamous epithelium (arrowhead) with a granular cell layer and a fibrous wall (arrow) of variable thickness, and it is filled with keratin.

fibrous wall. The mass was filled with keratinized debris and cleft space without teratomatous elements, compatible with a testicular epidermoid cyst (Fig. 4B). The surrounding seminiferous tubules showed intact spermatogenesis without atrophic change.

Discussion

Epidermoid cyst is a benign epithelial tumor that is commonly found in the brain, meninges, spleen, salivary gland, pancreas, etc. (4). Epidermoid cysts in the testis account for 1–2% of all testicular tumors (1). Epidermoid cysts can occur in multiplicity, in which case it is related to Gardner syndrome, Klinefelter syndrome, primary carcinoid tumor and cryptorchid testis. The usual clinical manifestation of testicular epidermoid cyst is a nontender, palpable and solitary intratesticular mass at 20–40 years of age. Tumor markers such as serum α -fetoprotein and β -human chorionic gonadotropin are within normal range (5).

The onion ring sign on the scrotal US was considered as a characteristic finding of a testicular epidermoid cyst (4). Although sonographic findings may suggest testicular epidermoid cyst, it is not pathognomonic because of considerable overlap with cystic teratoma (6). It has been reported that teratoma can show onion ring pattern without blood flow on color Doppler examination (7). In this case, the lesion showed an onion ring appearance on US and the US finding was pathologically associated with alternating layers of compacted keratin and loosely dispersed desquamated squamous cells (1). Teratoma of the testis has malignant potential and can cause metastasis. If teratoma of the testis is suggested, orchiectomy is needed. However, testicular epidermoid cyst is a benign lesion without recurrence, and organ preserving surgery as treatment is enough. For that reason, differential diagnosis of these lesions is important when deciding upon treatment strategy (7–9).

Calcification in testicular epidermoid cysts is occasionally noted on CT (4), as it was in our case. CT is useful in evaluating metastasis or systemic nodal staging and demonstrating calcification. However, this finding has no more benefits for tumor characterization or differential diagnosis.

Recently, MRI has been used to differentiate epidermoid cysts from other testicular malignancies

and to facilitate a precise preoperative diagnosis (10). The testicular mass in our case showed high signal intensity with internal concentric rings of alternating high and low signal intensity on T2-weighted images. The findings were concordant with the onion ring appearance on the US. Also, the peripheral low signal rim on T1 and T2 weighted images represented fibrous capsule and epithelial lining of the epidermoid cyst. The absence of contrast enhancement is associated with the benign nature of these lesions. This point helped to make a differential diagnosis from other solid testicular tumors or abscesses, which showed enhancement. Malignant testicular tumors usually show enhancing solid portions and areas of hemorrhage or necrosis. Also, a malignant testicular mass can invade adjacent organs beyond the testis. MRI can help to characterize testicular tumor due to high tissue contrast characterization. The fat component of a mature cystic teratoma appears as high signal intensity on T1 weighted images. In this case, no fat component in the mass was detected on the phase images of MRI. The testicular mass showed high signal intensity on DWI and lower ADC values than adjacent normal testicular parenchyma. The signal intensities of DWI and ADC are typical findings of epidermoid cysts in the brain. On DWI, intracranial epidermoid cysts show restricted diffusion with high signal intensity and similar ADC values to brain parenchyma. The low ADC values of intracranial epidermoid cysts were supposed to result from the dense keratinous and proteinous content, and could be applied to testicular epidermoid cysts (3). Abnormal high SI on DWI in ovarian mature cystic teratoma has been reported to correspond to keratinoid substance and Rokitansky protuberances. However, high SI in ovarian mature cystic teratoma on DWI usually presents as small focal portion of cystic mass which is different with our case that showed homogeneous diffusion restriction. Heterogeneous appearance due to stratified squamous lining, keratinoid or mucoid content, fatty component and calcified epithelial derivatives could add diagnostic value in differentiating mature cystic teratoma from epidermoid cyst. To the best of our knowledge, there have been no report about the findings of DWI and ADC map in epidermoid cysts and mature cystic teratoma of testis.

Enucleation is currently performed for testicular

epidermoid cyst because it may offer better psychologic and cosmetic results, and also preserve fertility. A careful frozen section analysis and biopsies of the adjacent parenchyma can ensure this process (7). There has been no reported recurrence in patients who underwent enucleation for testicular epidermoid cysts (1). The procedure could be more safely performed if preoperative diagnosis is accurate and reliable.

Conclusion

This testicular epidermoid cyst showed homogeneous high signal intensity on DWI with low and high b-values and low ADC values, similar to those in the brain. Testicular MRI, in addition to DWI and ADC map, can help to more accurately diagnose testicular epidermoid cysts.

References

1. Cho JH, Chang JC, Park BH, Lee JG, Son CH. Sonographic and MR imaging findings of testicular epidermoid cysts. *AJR Am J Roentgenol* 2002;178:743-748

2. Saremi F, Knoll AN, Bendavid OJ, Schultze-Haakh H, Narula N, Sarlati F. Characterization of genitourinary lesions with diffusion-weighted imaging. *Radiographics* 2009;29:1295-1317

3. Hakyemez B, Aksoy U, Yildiz H, Ergin N. Intracranial epidermoid cysts: diffusion-weighted, FLAIR and conventional MR findings. *Eur J Radiol* 2005;54:214-220

4. Atchley JT, Dewbury KC. Ultrasound appearances of testicular epidermoid cysts. *Clin Radiol* 2000;55:493-502

5. Langer JE, Ramchandani P, Siegelman ES, Banner MP. Epidermoid cysts of the testicle: sonographic and MR imaging features. *AJR Am J Roentgenol* 1999;173:1295-1299

6. Stein MM, Stein MW, Cohen BC, Li M, Koenigsberg M. Unusual sonographic appearance of an epidermoid cyst of the testis. *J Ultrasound Med* 1999;18:723-726

7. Maizlin ZV, Belenky A, Baniel J, Gottlieb P, Sandbank J, Strauss S. Epidermoid cyst and teratoma of the testis: sonographic and histologic similarities. *J Ultrasound Med* 2005;24:1403-1409; quiz 1410-1401

8. Chen C, Wu C, LIN W, Cheng W, Sun G, Chen C. Unusual MR imagings of an incidental testicular epidermoid Cyst: a case report. *Chin J Radiol* 2005;30:251-256

9. Woodward PJ, Sohaey R, O'Donoghue MJ, Green DE. From the archives of the AFIP: tumors and tumorlike lesions of the testis: radiologic-pathologic correlation. *Radiographics* 2002;22:189-216

10. Yoshida T. MRI of testicular epidermoid cyst. *Radiat Med* 2004;22:354-356

대한자기공명영상의학회지 15: 154-159(2011)

**확산강조영상과 현상확산계수(ADC) 영상을 통한
고환 표피 낭종의 진단: 증례 보고**

¹인제대학교 일산백병원 영상의학과
²연세대학교 의과대학 영상의학과
³인제대학교 일산백병원 병리과

김미선¹ · 김경아² · 장선희³

고환 표피 낭종은 드문 양성 종양으로, 모든 고환 종양의 1-2%를 차지한다. 양성 질환으로 고환의 보존이 가능하므로 수술 전에 정확한 진단이 가능하다면 불필요한 고환 절제술을 피할 수 있다. 저자는 오른쪽 음낭의 무통성 종괴로 내원한 18세 남자의 고환 표피 낭종 한례를 경험하여 보고하고자 한다. 종괴는 초음파상 양과환 징후를 보였고 컴퓨터 단층 촬영에서는 종괴 내부에 곡선의 석회화가 관찰되었다. 자기공명영상 T2 강조영상에서 종괴는 내부에 교차하는 저 신호의 환을 동반하는 고신호 강도로 보였다. 확산강조 영상에서 이 종괴는 고신호 강도를 보이고 현상확산계수(ADC) 영상에서는 낮은 값을 보였으며 이와 같은 소견은 두개내 표피 낭종에서 보고된 바와 동일한 것이다. 기존의 자기공명영상에 확산강조 영상과 현상확산계수 영상을 추가로 시행한다면 고환 표피 낭종의 진단에 도움이 될 것으로 기대된다.

통신저자 : 김경아, (120-752) 서울시 서대문구 신촌동 134, 연세대학교 의과대학 영상의학과
Tel. (02) 2228-7400 Fax. (02) 393-3035 E-mail: bellenina@daum.net