

## A maxillary canine with two separated root canals: a case report

Dong-Ryul Shin<sup>1</sup>, Jin-Man Kim<sup>2</sup>, Duck-Su Kim<sup>3</sup>, Sun-Young Kim<sup>2</sup>, Paul V Abbott<sup>4</sup>, Sang-Hyuk Park<sup>2\*</sup>

<sup>1</sup>Luden Dental Clinic, <sup>2</sup>Department of Conservative Dentistry, Kyung Hee University School of Dentistry,

<sup>3</sup>Department of Conservative Dentistry, Medical Center, Kyung Hee University School of Dentistry, Seoul, Korea

<sup>4</sup>Winthrop professor of Clinical Dentistry, Department of Endodontics, University of Western Australia, Australia

### ABSTRACT

Maxillary canines have less anatomical diversities than other teeth. They usually have a single root and root canal. This report describes an endodontic treatment of a maxillary canine with two separated root canals which have not been reported through the demonstration of radiography and computerized tomography (CT).

Even though appropriated endodontic treatment has been performed, the severe pain could happen due to lack of consideration of anatomical variations of the teeth. Therefore, the clinicians should be well aware of the possibility of anatomical variations in the root canal system during endodontic treatment even if the number of root canals is obvious such as in this case. [J Kor Acad Cons Dent 2011;36(5):431-435.]

**Key words:** Maxillary canine; Two root canals

-Received 28 April 2011; revised 7 July 2011; accepted 18 July 2011-

### INTRODUCTION

In general, maxillary canines contain only single root and root canals, therefore, only few recent studies regarding maxillary canines with two root canals have been reported.<sup>1,2</sup> This case report will demonstrate a maxillary canine is composed with two root canals which are completely separated, therefore, it will generate more precise understanding of anatomical variations of the maxillary canine.

### CASE REPORT

A 58-year-old man was referred to Luden dental clinic. The main complaint of the patient was severe and continuous pain on the left side of maxillary canine. The tooth was over-prepared because it would be the abutment tooth of a removable partial denture. Any unusual medical histories were not revealed. The clinical examination revealed a pin point pulp exposure in the tooth, and the severe pain

<sup>1</sup>Shin DR, DMD, MSD, PhD, Private practice, Luden Dental Clinic,

<sup>2</sup>Kim JM, DMD, Postgraduate student; Kim SY, DDS, MSD, PhD, Assistant Professor; Park SH, DMD, MSD, PhD, Associate Professor, Department of Conservative Dentistry, Kyung Hee University School of Dentistry,

<sup>3</sup>Kim DS, DMD, MSD, PhD, Clinical Instructor, Department of Conservative Dentistry, Medical Center, Kyung Hee University School of Dentistry, Seoul, Korea

<sup>4</sup>Abbott PV, BDS, MDS, FRACDS (ENDO), FPFA, FADI, FICD, FACD, Winthrop professor of Clinical Dentistry, Department of Endodontics, University of Western Australia, Australia

\*Correspondence to Sang-Hyuk Park, DMD, MSD, PhD.

Associate Professor, Department of Conservative Dentistry, Kyung Hee University School of Dentistry, Hoegi-dong, Dongdaemoon-gu, Seoul, Korea, 130-701

TEL, +82-2-440-6206; FAX, +82-2-440-7549; E-mail, shpark94@khu.ac.kr

※ This research was supported by basic Science Research Program through the National Research Foundation of Korea (NRF) founded by the Ministry of Education, Science and Technology (KRF-20100023448).

## Case report

was found while the ethyl chloride temperature test and the percussion test were performed. Preoperative radiographic findings were revealed no specific periapical pathosis (Figure 1).

On the basis of clinical findings, an irreversible pulpitis of the tooth was diagnosed and endodontic treatment was planned. During the first visit, the access cavity was opened under local anesthesia with 2% lidocaine. Only one root canal orifice was found on the labial side after access cavity opening. The working length was measured with an electronic apex locator (Root ZX, Morita, Tokyo, Japan) and the pulp was extirpated completely using a K-hand file (Kerr, Romulus, MI, USA). At the second visit, the pain was partially relieved, however a positive response to the percussion test was revealed. A cone beam computed tomograph (CT) scan (Implagraphy SC, Vatech, Yongin, Korea) was taken with a 1 mm-thick section. The sagittal plane image of the cone beam CT scan revealed the presence of an additional curved canal on the palatal side (Figure 2). The palatal canal orifice was identified by extending the access cavity to the palatal side (Figure 3). After the working length of the palatal canal was measured using the electronic apex locator, a periapical radiograph was taken (Figure 4). The periapical radiograph revealed two separated root canals. Using a rotary nickel-titanium file (ProFile, Dentsply

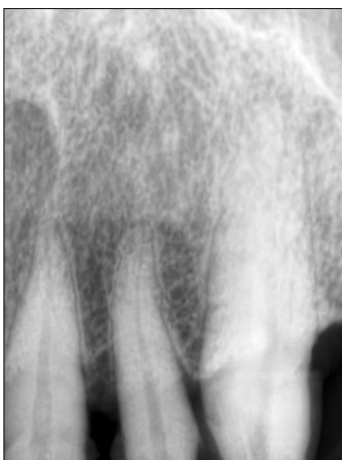Maillefer, Ballaigues, Switzerland), the root canals were shaped to #40 by the crown-down method.

At the third visit, remaining discomfort disappeared completely, and the root canals were filled with gutta-percha (Diadent, Chongju, Korea) and root canal sealer (AH Plus, Dentsply Maillefer, Konstanz, Germany) (Figure 5). The patient did not have any specific symptoms or abnormalities during the 6-month follow-up period.

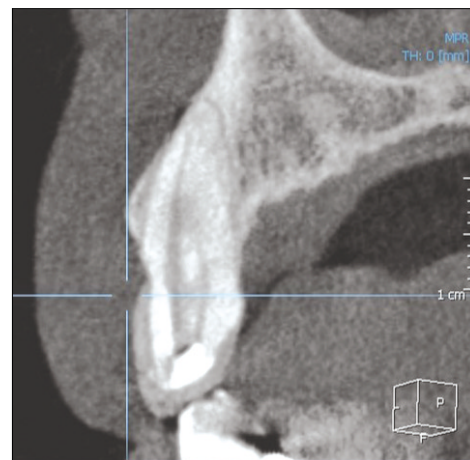
## DISCUSSION

When the anatomical anomaly is observed in the radiographic findings at the first examination, corresponding abnormalities on the opposite side must be suspected. In this case, the radiographic image of the opposite canine of the patient showed a Vertucci Type II (2-1) (Figure 6). Although there are limitations in radiographic image and possibilities of incomplete endodontic treatment, the results also showed a bilateral anatomical anomaly in this case. In this regard, they had stated "The more rare the aberration, the more likely it is to be bilateral in occurrence".<sup>1</sup>

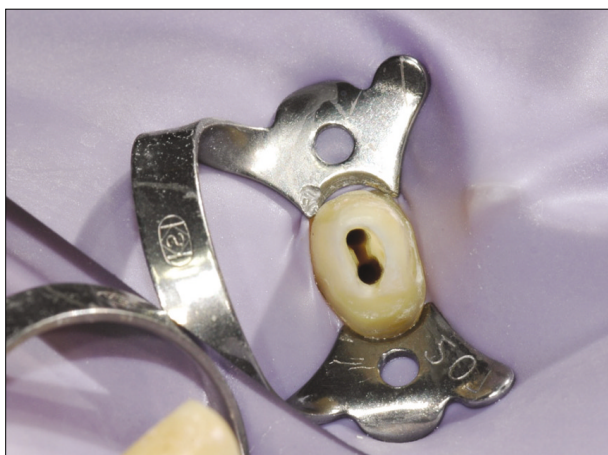Generally, it is considered that all maxillary canines only have a single canal.<sup>2,3</sup> However, two studies have been reported that a maxillary canine is composed with two root canals in the possibility of



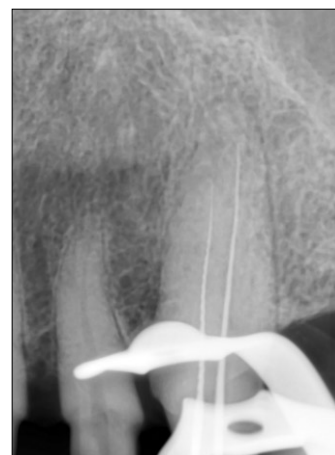**Figure 1.** Preoperative radiograph of left maxillary canine. There was no special periapical pathosis.



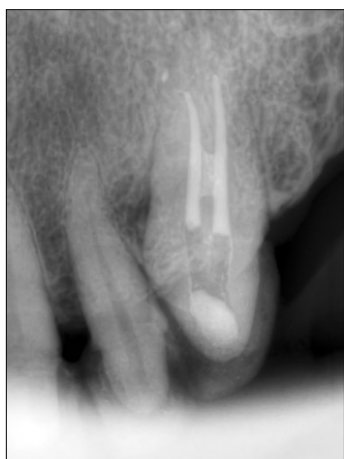**Figure 2.** Sagittal plane cone beam CT image of the left maxillary left canine. Additional s-shaped root canal is observed on the palatal side. CT, computed tomograph.



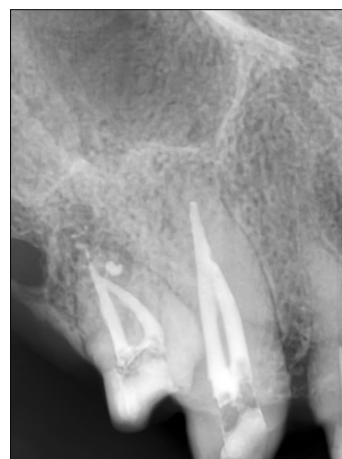**Figure 3.** Clinical pictures after access opening. Two separated orifices can be clearly observed.



**Figure 4.** Files are placed within the root canal to identify the canal path.



**Figure 5.** Radiographic image after canal filling. The root canal showed communicating pattern at middle one-third point.



**Figure 6.** Radiographic image of maxillary right canine of the same patient. Two separated canals converging at the apical one-third point can be seen under the canal filling condition.

the ranges of approximately 2 - 3% as the below Table 1.<sup>4,5</sup> These studies related to the root canal anatomy of the maxillary canine are summarized in Table 1.

In summary, the root canal system of the maxillary canine seems to be diverse. However, this facts were hard to be demonstrated due to difficulties in identifying the various anatomy in the root canal system since roentgenographic or simple staining methods were used. In the other hand, new methods are now being used, including micro CT<sup>6</sup> and cleared teeth

**Table 1.** Studies on the root canal anatomy of the maxillary canine

Author	1 canal	2 canals
Pineda & Kuttler (1972)	100%	0%
Vertucci (1984)	100%	0%
Çalışkan <i>et al.</i> (1995)	97.83%	2.17%
Weng <i>et al.</i> (2009)	96.90%	3.10%

technique<sup>2</sup> to allow three-dimensional identification of the complex aspects of the root canal system. The root canal systems of all teeth including the maxillary canine possible to be demonstrated to be relatively complicated patterns.

There has been only one case report that showed the presence of maxillary canine which has one root and two root canals.<sup>7</sup> However, the reported canine is a type II (2-1) according to the Vertucci classification in which the separated root canals converge with each other at the apex. In this case; however, the maxillary canine has two separate orifices and root canals that communicate at the middle third of the root. According to the Vertucci classification, the present case can be classified as type VI (2-1-2) which has not been reported yet. This case has been provided a broader understanding of anatomical variations in the maxillary canine.

Conflict of Interest: No potential conflict of interest relevant to this article was reported.

### CONCLUSION

Lots of anatomical variations exist in the root canal system<sup>8</sup> and the maxillary canine has been found of containing with two root canals. If both root canals have not been appropriately treated during endodontic treatment, the necrotic tissue may remain after the treatment, and it may negatively affect prognosis.<sup>9</sup> For example, if only one side of root canals has

been treated, the severe pain might be revealed. Therefore, to treat complete removal of any infection and prevention of re-infection, the clinician should be well aware of the possibility of anatomical variations in the root canal system.

### REFERENCES

1. Sabala CL, Benenati FW, Neas BR. Bilateral root or root canal aberrations in a dental school patient population. *J Endod* 1994;20:38-42.
2. Pin&da F, Kuttler Y. Mesiodistal and buccolingual roentgenographic investigation of 7,275 root canals. *Oral Surg Oral Med Oral Pathol* 1972;33:101-110.
3. Vertucci FJ. Root canal anatomy of the human permanent teeth. *Oral Surg Oral Med Oral Pathol* 1984;58:589-599.
4. Cali&kan MK, Pehlivan Y, Sepet&ioğlu F, Türkün M, Tuncer SS. Root canal morphology of human permanent teeth in a Turkish population. *J Endod* 1995;21:200-204.
5. Weng XL, Yu SB, Zhao SL, Wang HG, Mu T, Tang RY, Zhou XD. Root canal morphology of permanent maxillary teeth in the Han nationality in Chinese Guanzhong area: a new modified root canal staining technique. *J Endod* 2009;35:651-656(s35).
6. Davis GR, Wong FS. X-ray microtomography of bones and teeth. *Physiol Meas* 1996;17:121-146.
7. Alapati S, Zaatar EI, Shyama M, Al-Zuhair N. Maxillary canine with two root canals. *Med Princ Pract* 2006;15:74-76.
8. Slowey RR. Radiographic aids in the detection of extra root canals. *Oral Surg Oral Med Oral Pathol* 1974;37:762-772.
9. Nair PN, Sjögren U, Krey G, Kahnberg KE, Sundqvist G. Intraradicular bacteria and fungi in root-filled, asymptomatic human teeth with therapy-resistant periapical lesions: a long-term light and electron microscopic follow-up study. *J Endod* 1990;16:580-588.

## 국문초록

## 두 개의 근관을 가진 상악 견치: 증례보고

신동렬<sup>1</sup> · 김진만<sup>2</sup> · 김덕수<sup>3</sup> · 김선영<sup>2</sup> · Paul V Abbott<sup>4</sup> · 박상혁<sup>2\*</sup><sup>1</sup>루덴 치과, <sup>2</sup>경희대학교 치의학전문대학원 치과 보존과, <sup>3</sup>경희대학교 의료원 치과 보존과, <sup>4</sup>서호주대학교 근관치료과

상악 견치는 다른 치아보다 해부학적 변이가 적으며, 보통 하나의 치근과 하나의 근관을 가진다. 이 연구는 이전에 거의 보고되지 않은 2개의 분리된 근관을 가진 상악 견치의 방사선 사진과 CT(컴퓨터 단층촬영)를 이용한 근관치료에 관한 증례보고이다.

비록 적절한 근관치료가 행해졌다고 해도, 치아의 해부학적 변이가 고려되지 않았기 때문에 심한 통증이 있을 수 있다. 따라서 임상가는 근관의 수가 이 경우처럼 명백한 경우의 치아에서도 근관치료 시 근관시스템의 해부학적 변이 가능성을 잘 알고 있어야 한다.

**주요단어:** 상악견치; 2근관