

Clinical Article

Targeting a Safe Entry Point for C2 Pedicle Screw Fixation in Patients with Atlantoaxial Instability

Hyung-Joon Chun, M.D., Koang Hum Bak, M.D.

Department of Neurosurgery, Hanyang University Medical Center, Seoul, Korea

Objective : This investigation was conducted to evaluate a new, safe entry point for the C2 pedicle screw, determined using the anatomical landmarks of the C2 lateral mass, the lamina, and the isthmus of the pars interarticularis.

Methods : Fifteen patients underwent bilateral C1 lateral mass-C2 pedicle screw fixation, combined with posterior wiring. The C2 pedicle screw was inserted at the entry point determined using the following method : 4 mm lateral to and 4 mm inferior to the transitional point (from the superior end line of the lamina to the isthmus of the pars interarticularis). After a small hole was made with a high-speed drill, the taper was inserted with a 30 degree convergence in the cephalad direction. Other surgical procedures were performed according to Harm's description. Preoperatively, careful evaluation was performed with a cervical X-ray for C1-C2 alignment, magnetic resonance imaging for spinal cord and ligamentous structures, and a contrast-enhanced 3-dimensional computed tomogram (3-D CT) for bony anatomy and the course of the vertebral artery. A 3-D CT was checked postoperatively to evaluate screw placement.

Results : Bone fusion was achieved in all 15 patients (100%) without screw violation into the spinal canal, vertebral artery injury, or hardware failure. Occipital neuralgia developed in one patient, but this subsided after a C2 ganglion block.

Conclusion : C2 transpedicular screw fixation can be easily and safely performed using the entry point of the present study. However, careful preoperative radiographic evaluation, regardless of methods, is mandatory.

Key Words : Atlantoaxial instability · C2 pedicle screw · Entry point · Technique.

INTRODUCTION

Several methods for stabilization of atlantoaxial instability have been introduced, including the posterior wiring technique (Gallie's⁶⁾ and Brook's¹⁾ technique), the interlaminar clamp²⁵⁾, transarticular screw fixation (TAF)¹⁶⁾, and C1 lateral mass-C2 pedicle (C1LM-C2P) screw fixation.¹⁰⁾ Among them, the C1LM-C2P technique has recently gained popularity due to several advantages, including less vertebral artery injury, greater fixation strength, intraoperative reduction, the ability to perform laminectomy concurrently, and a high fusion rate. However, surgeons should pay close attention to C2 pedicle screw fixation to prevent vertebral artery (VA) injury. In the present study, the authors describe a new, safe entry targeting method for C2 pedicle screw fixation.

MATERIALS AND METHODS

Surgical technique

Unless noted otherwise, the procedures are similar to Harm's technique. Under general anesthesia, prone positioning was achieved with a head clamp. Using C-arm guidance, the alignment of the C1-C2 complex was checked. Subperiosteal exposure was performed from the occiput to C4 and the lateral border of the C1-C2 articulation. The venous plexus of the C1-C2 joint was coagulated with bipolar cautery and mechanical compression with a hemostatic agent. Full exposure of the bony structures of the C1-C2 articulation was performed for screw insertion at C1 and C2. For exposure of the entry point of the C1 lateral mass, the ganglion of C2 was retracted in a caudal direction, and the entry point was then marked with a 1 mm high speed burr drill, as in Harm's technique. For C2 pedicle screw fixation, the medial border of the C2 pars interarticularis was carefully exposed to prevent screw malpositioning into the spinal canal. The entry point of C2 was targeted according to the transitional corner, which is the more cephalad portion of the lamina and the C2 isthmus (Fig. 1A, B). Using a high-speed drill, the entry point was marked 4 mm lateral to and 4 mm

• Received : March 8, 2011 • Revised : April 12, 2011

• Accepted : June 8, 2011

• Address for reprints : Koang Hum Bak, M.D.

Department of Neurosurgery, Hanyang University Medical Center,
17 Haengdang-dong, Seongdong-gu, Seoul 133-792, Korea

Tel : +82-2-2290-8496, Fax : +82-2-2281-0954

E-mail : pkh2325@hanyang.ac.kr

caudal to the above-mentioned corner (Fig. 1C). The direction was approximately 20° to 30° in a medial and cephalad direction in regard to the medial border of the C2 pars interarticularis under C-arm guidance. After hole tapering and identification with a probe, a 3.5 mm polyaxial screw of the proper length was inserted (Fig. 1D). Before rod application, a bone strut, either an autologous piece of iliac bone or cadaveric bone, was inserted between the decorticated C1-C2 inter-laminar space with a cable to achieve a high fusion rate. Finally, the rod was applied compressing the space between the C1 and C2 screws.

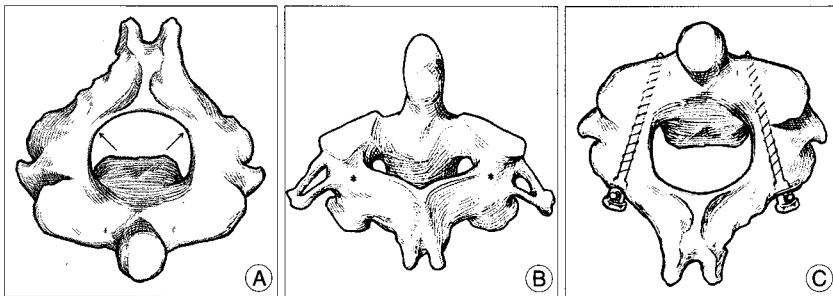


Fig. 1. Drawing of the anatomical entry point for the C2 pedicle screw. A : Superior aspect of C2. The black arrow points to the transitional point from the superior line of the lamina to the isthmus of the pars interarticularis. B : The asterisk indicates the entry point for the C2 pedicle screw, 4 mm lateral to and 4 mm caudal to the transitional point. C : Schematic drawing shows inserted C2 pedicle screws without violation into the spinal canal and the vertebral foramen.

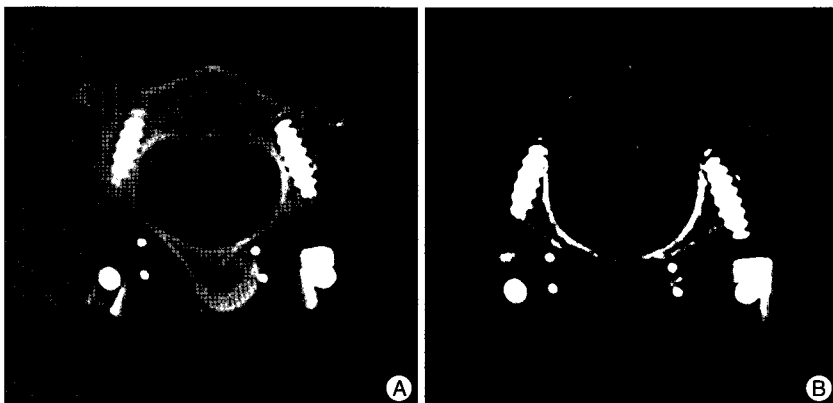


Fig. 2. Postoperative computed tomogram scan of the C2 pedicle screw. Axial scan reveals no violation into the spinal canal (A) or the vertebral foramen (B).




Fig. 3. Three dimensional computed tomogram shows suitable location of screws and wiring with cadaveric bone in the last follow-up period. A : Anteroposterior view. B : Lateral view.

Patient demographics

From Jan. 2008 to Dec. 2008, a total of 15 patients underwent C1LM-C2P screw fixation for atlantoaxial stabilization. The instability was due to several causes, including rheumatoid arthritis in 11 patients and traumatic lesions in 4 patients. The mean age was 56.88 years with a range of 27 to 74 years. There were 5 males and 10 females. Follow-up was achieved for at least 12 months.

Radiographic evaluation

All patients underwent preoperative radiographic evaluation, as follows : plain X-ray with dynamic views to assess alignment, cervical magnetic resonance imaging for evaluation of the spinal cord and atlantoaxial ligaments, and a 3-dimensional computed tomogram (3-D CT) scan for assessment of the screw pathway and the course of the VA. Follow-up radiographs were checked immediately, 3 months, 6 months, and 12 months postoperatively to identify fusion and any instrument abnormalities. 3-D cervical CT scans were also performed for the evaluation of screw placement in the immediate postoperative period.

RESULTS

Bilateral C1LM-C2P screw fixation with posterior wiring was performed in all patients. Intraoperatively, there were no cases of screw insertion failure, and there was no significant bleeding from VA injury. When compared with the preoperative atlantodental interval, postoperative radiographs showed satisfactory reduction of the atlantoaxial joint in all cases. Among the total 30 C2 pedicle screws, there was no violation into the spinal canal (Fig. 2A). One case of occipital neuralgia was easily treated with a C2 ganglion block. No VA injury was observed in the immediate postoperative CT scans (Fig. 2B). In all patients, atlantoaxial instability was reduced, and solid fusion was identified on the follow-up films (Fig. 3). Other complications, such as infection or implant failure, were not observed.

DISCUSSION

Among the several methods for stabi-

lization of C1-C2 instability, the screw system is utilized in Margerl's¹⁰, Harms's²⁶, and the Wright¹⁴ techniques. Over the course of several decades, various rates of VA injury have been reported, yet TAF has been the gold standard of treatment for C1-C2 instability^{3,8,12,21-23}. To prevent VA injury, several methods related to TAF have been recommended: a stereotactic frameless imaging system¹⁹, an aiming device²⁴, modification of the entry point¹⁵, and unilateral TAF with posterior wiring¹¹. Recently, despite the fact that long-term follow-up data for TAF is scant, the Harms' technique has been widely used to treat atlantoaxial instability because of its high fusion rate and low complication rate. Harms et al.¹⁰ and Goel et al.⁷ reported 100% bony fusion without VA injury or spinal cord violation using C1LM-C2P screw fixation. Additionally, in a previous paper by Gunnarsson et al.⁹, it was reported that C2 pedicle screw insertion had a lower rate of VA injury than TAF.

For C2 screw fixation, Wright described a technique in 2004, called crossed C2 intralaminar screw fixation dependent on intact and adequate sized C2 lamina, in which polyaxial screws are inserted into the lamina of C2 in a bilateral crossing fashion²⁶. Crossed C2 intralaminar screw fixation is useful in many cases, particularly when there is an anomalous course of the vertebral artery or a very small C2 pedicle. Although this technique has been reported to have a high fusion rate and a low rate of surgical complications¹⁸, Lapsiwala et al.¹⁴ reported that there was a statistically significant difference in the amount of lateral bending between TAF combined with cable augmentation and crossed C2 intralaminar screws with a cable. However, if assisted with posterior cable wiring, there was no significant difference between TAF and C1LM-C2P screw fixation¹⁴. Additionally, Claybrooks et al.² demonstrated that C2 pedicle screw fixation was a more stable fixation than C2 intralaminar screw fixation in terms of lateral bending and axial rotation. In other words, if implementation is possible, the C2 pedicle screw fixation technique should be used, as it is superior to the C2 intralaminar screw system in terms of the motion of atlantoaxial articulation.

The C2 pedicle is located medially beneath the superior articular facet and anteromedially to the transverse foramen, and it is the short portion of bone connecting the posterior elements with the vertebral body. The pars interarticularis is the narrow portion of bone between the superior and inferior articular facets. The pars interarticularis of C2 is defined by a narrow portion of bone between the superior articular facet and the inferior articular process⁵. In the strict sense, the pathway of a C2 pedicle screw should start at the posterior portion of the inferior articular process and via the pars interarticularis and should continue into the pedicle and the vertebral body. According to papers by Panjabi et al.²⁰ and Xu et al.²⁷, the C2 pedicle is relatively large, ranging 9-11 mm in height and 7-9 mm in width. However, these results are, in fact, a measurement of the isthmus of the pars interarticularis according to the abovementioned anatomical definition. Additionally, several papers have suggest-

ed that the diameter of the pedicle is less than 5 mm in 2.4-11.7% of the population^{13,17,27}. In such cases, even if using a 3.5 mm screw, safe screw placement is technically difficult when considering convergence and the cephalad direction of the C2 pedicle.

Since the beginning of C2P screw fixation, a definitive entry point of the C2 pedicle screw has not been established. Ebraheim et al.⁴ described two different methods for C2 pedicle screw placement: the designation of an entry point (Method A) and the intraoperative method (Method B), which is related to the medial and superior aspect of the C2 pedicle. In method A, the entry point was defined as 5 mm inferior to and 7 mm lateral to the intersection point crossing an imaginary line between the superior border of the lamina and the lateral limits of the spinal canal. There were four major violations of the vertebral artery using this method. Using method B, Ebraheim et al.⁴ reported only 2 minor violations into the transverse foramen without vascular injury. However, because the imaginary point or line can vary depending on both the operative field and the operators, an entry point using bony anatomy may be more appropriate.

In the authors' opinion, there is no risk of neural injury in C2 pedicle screw fixation because the screw has already passed the spinal cord at this depth. There are several reasons why the entry point for the C2 pedicle screw should be designed from the medial aspect of the pars interarticularis to prevent the possibility of vertebral artery injury. First, the width of the C2 pedicle may be determined by the invaginated degree of the medial aspect of the transverse foramen, if the medial cortical margin of the pedicle is fixed. Second, by using the point 4 mm lateral to the transitional corner of the lamina and the isthmus, one can prevent violation into the spinal canal and the transverse foramen when a 30 degree angle of convergence, a cephalad direction, and a proper screw diameter are all utilized. Third, this point is relatively less irritated, as compared to the circumferential tissue, and, consequently, the possibility of individual variation, such as with hypertrophy, is low.

Although the present study has several limitations, including the absence of a cadaveric study and a small sample size, the authors believe that this entry point allows for safe and reliable screw placement into the C2 pedicle.

CONCLUSION

Although the suggested entry point is located in the cranial and medial quadrant of the C2 isthmus surface, as was described in Harms's paper, we present a precise anatomical location and propose that this entry point be used uniformly. Nevertheless, careful anatomical assessment with preoperative radiographs is still of the utmost importance.

• Acknowledgements

This work was supported by the research fund of Hanyang University (HY-2007-C).

References

1. Brooks AL, Jenkins EB : Atlanto-axial arthrodesis by the wedge compression method. *J Bone Joint Surg Am* 60 : 279-284, 1978
2. Claybrooks R, Kayanja M, Milks R, Benzel E : Atlantoaxial fusion: a biomechanical analysis of two C1-C2 fusion techniques. *Spine J* 7 : 682-688, 2007
3. Dickman CA, Sonntag VK : Posterior C1-C2 screw fixation for atlanto-axial arthrodesis. *Neurosurgery* 43 : 275-281, 1998
4. Ebraheim N, Rollins JR Jr, Xu R, Jackson WT : Anatomical consideration of C2 pedicle screw placement. *Spine (Phila Pa 1976)* 21 : 691-694, 1996
5. Ebraheim NA, Fow J, Xu R, Yeasting RA : The location of the pedicle and pars interarticularis in the axis. *Spine (Phila Pa 1976)* 26 : 34-37, 2001
6. Gallie WE : Fractures and dislocations of the cervical spine. *Am J Surg* 46 : 495-499, 1939
7. Goel A, Desai KI, Muzumdar DP : Atlantoaxial fixation plate and screw method : a report of 160 treated patients. *Neurosurgery* 51 : 1351-1357, 2002
8. Grob D, Jeanneret B, Aebi M, Markwalder TM : Atlanto-axial fusion with transarticular screw fixation. *J Bone Joint Surg Br* 73 : 972-976, 1991
9. Gunnarsson T, Massicotte EM, Govender PV, Raja Rampersaud Y, Fehlings MG : The use of C1 lateral mass screws in complex cervical spine surgery : indications, techniques, and outcome in a prospective consecutive series of 25 cases. *J Spinal Disord Tech* 20 : 308-316, 2007
10. Harms J, Melcher RP : Posterior C1-C2 fusion with polyaxial screw and rod fixation. *Spine (Phila Pa 1976)* 26 : 2467-2471, 2001
11. Hue YH, Chun HJ, Yi HJ, Oh SH, Oh SJ, Ko Y : Unilateral posterior atlantoaxial transarticular screw fixation in patients with atlantoaxial instability : Comparison with bilateral method. *J Korean Neurosurg Soc* 45 : 1-6, 2009
12. Jeanneret B : Posterior transarticular screw fixation of C1-C2. *Tech Orthop* 1 : 49-59, 1994
13. Karaikevic E, Daubs M, Madsen R, Gaines R : Morphologic characteristics of human cervical spines. *Spine (Phila Pa 1976)* 22 : 493-500, 1997
14. Lapsiwala SB, Anderson PA, Oza A, Resnick DK : Biomechanical comparison of four C1 to C2 rigid fixative techniques : anterior transarticular, posterior transarticular, C1 to C2 pedicle and C1 to C2 intralaminar screws. *Neurosurgery* 58 : 516-521, 2006
15. Lee JH, Jahng TA, Chung CK : C1-2 transarticular screw fixation in high-riding vertebral artery : suggestion of new trajectory. *J Spinal Disord Tech* 20 : 499-504, 2007
16. Magerl F, Seeman PS : Stable posterior fusion of the atlas by transarticular screw fixation in Kehr P, Weidner A (eds) : *Cervical Spine I*. New York, NY : Springer-Verlag, 1987
17. Mandel Im, Kamach BJ, Petersilge CA, Johnstone B, Yoo JU : Morphologic considerations of C2 isthmus dimensions for placement of transarticular screws. *Spine (Phila Pa 1976)* 25 : 1542-1547, 2000
18. Menendez JA, Wright NM : Techniques of posterior C1-C2 stabilization. *Neurosurgery* 60 : S103-S111, 2007
19. Neo M, Sakamoto T, Fujibayashi S, Nakamura T : A safe screw trajectory for atlantoaxial transarticular fixation achieved using an aiming device. *Spine (Phila Pa 1976)* 30 : 236-242, 2005
20. Panjabi MM, Duranceau J, Goel V, Oxland T, Koichiro T : Cervical human vertebrae-Quantitative three dimensional anatomy of the middle and lower regions. *Spine (Phila Pa 1976)* 16 : 861-869, 1991
21. Starr JK, Eismont FJ : Atypical hangman's fracture. *Spine (Phila Pa 1976)* 18 : 1954-1957, 1993
22. Stulik J, Vyskocil T, Sebesta P, Kryl J : Atlantoaxial fixation using the polyaxial screw-rod system. *Eur Spine J* 16 : 479-484, 2007
23. Suchomel P, Stutlck J, Klézl Z, Chrobok J, Lukas R, Krbec M, et al. : Transarticular fixation of C1-C2 : a multicenter retrospective study. *Acta Chir Orthop Traumatol Cech* 71 : 6-12, 2004
24. Takahashi J, Shono Y, Nakamura I, Hirabayashi H, Kamimura M, Ebara S, et al. : Computer-assisted screw insertion for cervical disorders in rheumatoid arthritis. *Eur Spine J* 16 : 485-494, 2007
25. Tucker HH : Technical report : method of fixation of subluxed or dislocated cervical spine below C1-C2. *Can J Neurol Sci* 2 : 381-382, 1975
26. Wright NM : Posterior C2 fixation using bilateral, crossing C2 laminar screws : Case series and technical note. *J Spinal Disord Tech* 17 : 158-162, 2004
27. Xu R, Nadaud MC, Ebraheim NA, Yeasting RA : Morphology of the second cervical vertebra and the posterior projection of the C2 pedicle axis. *Spine (Phila Pa 1976)* 20 : 259-263, 1995