

(Review Article)

Gross Abnormalities in Tilapia

Douglas Tave¹, Jae-Yoon Jo^{2*} and Dong Soo Kim²

¹Los Lunas Silvery Minnow Refugium, New Mexico Interstate Stream Commission,
1000 Main St. NW, Building H, Los Lunas, NM 87031, USA

²Department of Marine Bio-Materials and Aquaculture, Pukyong National University,
Busan 608-737, Korea

Thirty-one gross abnormalities that have been observed in tilapia are described: 10 fin, five eye, five jaw, four body shape, three head, two yolk sac, one operculum, and conjoined twins. Twenty-one have been described in published papers; the others were obtained from a survey. Breeding experiments revealed that three were heritable, while six were not heritable. Five could be caused by a bacterial infection, and one could be produced by a fungus. Four deformities were in offspring of males that had been injected with methyl methane sulphonate. Three were produced when sperm was treated with methyl methane sulphonate. Six were observed during sex reversal studies, and one was found following heat shock of fertilized eggs. Three were observed in polluted river water. The cause of other deformities is not known.

Key words: Tilapia, Abnormality, Genetics, Pollution, Disease, Sex-reversal

Introduction

Aquacultured fish with gross abnormalities can be problematic because they can affect marketability (e.g., Afonso et al. 2000; Michie 2001; Verhaegen et al. 2007; Castro et al. 2008). Consequently it is important to describe deformities, determine their frequencies and determine their causes.

Abnormal fish occur in all populations. Dawson (1964, 1966, 1971) and Dawson and Heal (1976) cataloged dozens of abnormalities in several hundred species of fish in a 1,499-reference review. A detailed examination of any population will reveal deformed individuals. For example, Afonso et al. (2000) found 39 deformities in a hatchery population of 11,640 gilthead sea bream *Sparus aurata* and Verhaegen et al. (2007) found that 80% of intensively raised stocks of gilthead seabream had deformed individuals. Sullivan et al. (2007) surveyed six Atlantic salmon *Salmo salar* farms and found that 3.8-8.8% of the fish had the "stubby body" deformity.

Surveys of tilapia populations have also revealed this problem. Guilherme (1992) found 2,621 *Oreochromis niloticus* that had one of three fin deformities in 5,456 specimen fish. Eissa et al. (2009)

surveyed *O. niloticus* at two Egyptian farms and found that 2.7% and 1.6% of the fish at these facilities were deformed. Phelps and Karsina (Phelps RP and Karsina E, Auburn University, AL, pers. comm.) examined Auburn University-Ivory Coast strain (AU-I) *O. niloticus* and found 23 deformed fingerlings that had one of four deformities in a sample of 7,200 fish; they also found that 2 of 234 brood fish were deformed (a single deformity).

The occurrence of deformed fish at fish farms should not be surprising, because a major goal of fish culture is to maximize survival (Tave 1993). Eggs and fry are often artificially incubated, which enable deformed ones to survive. Ponds are fertilized and fish are fed; deformed fish that might have trouble finding food in the wild have easy access to food. Finally, efforts are taken to exclude or kill predators; abnormal individuals that would be vulnerable to predation in the wild can survive at a fish farm.

It is often assumed that all abnormalities have a genetic basis, but most are non-heritable (Tave, 1993). Non-heritable abnormalities can be caused by disease (e.g., Hoffman et al., 1962; Hoffman, 1984; Pasnik et al. 2007); injury (e.g., Breeder, 1953; Gunter and Ward, 1961); environmental disturbances (e.g., Rogers 1956; Garside, 1959; Yamamoto et al. 1963; Schröder, 1969; Mayer et al., 1978; Couch et al., 1979; Backiel et al., 1984; Grady et al., 1992;

© This is an Open Access article distributed under the terms of the Creative Commons Attribution Non-Commercial License (<http://creativecommons.org/licenses/by-nc/3.0/>) which permits unrestricted non-commercial use, distribution, and reproduction in any medium, provided the original work is properly cited.

*Corresponding author: jjjo@pknu.ac.kr

Copyright@The Korean Society of Fisheries and Aquatic Science

Wargelius et al., 2005; Sun et al., 2009); nutritional deficiencies (e.g., Rucker et al., 1970; Andrews and Murai, 1975; Lim and Lovell, 1978; Murai and Andrews, 1978), and culture conditions (e.g., Romanov, 1984; Wiegand et al., 1989; Leary et al., 1991; Krise and Smith, 1993; Sawada et al., 2006). They can also be the result of developmental errors (e.g., Tave et al., 1982; Dunham et al., 1991; Handwerker and Tave, 1994; Tave and Handwerker, 1994).

When abnormalities are produced genetically, they are usually produced by recessive alleles (e.g., Aida, 1930; Matsui, 1934a; Rosenthal and Rosenthal, 1950; Schultz, 1963; Thomerson, 1966; Tukeuchi, 1966; Mair, 1992). One reason why genetically-produced abnormalities occur at hatcheries is that most hatchery populations have small effective breeding numbers (Tave, 1993, 1999). Inbreeding is inversely related to effective breeding number, and one aspect of inbreeding depression is an increase in the production of abnormal fish--these abnormalities are produced by recessive alleles.

Inbreeding studies in fish have produced abnormalities in rainbow trout *Oncorhynchus mykiss* (Aulstad and Kittelson, 1971; Kincaid, 1976), zebra fish *Danio rerio* (Piron, 1978; Mrakovčić and Haley, 1979; and convict cichlid *Cichlasoma nigrofasciatum* (Winemiller and Taylor, 1982). For example, one generation of brother-sister matings (inbreeding=25%), increased the percentage of deformed rainbow trout by 3%, and two generations (inbreeding=37%) increased it by 10% (Kincaid, 1976).

Even though most heritable abnormalities are produced by recessive alleles, they can also be produced by dominant alleles (Matsui, 1934b; Lodi, 1978; Tave et al., 1983).

Deformed fish can be produced when species are hybridized (e.g., Ihssen, 1978; Chappell, 1979; Beck and Biggers, 1983; Blanc and Poisson, 1983; Blanc and Chevassus, 1986; Kurokura et al., 1986; McKay et al., 1992). In some cases the incidence is so high that it makes the hybrid unsuitable for commercial development. For example, Chappell (1979) found that the hybrids between white catfish, *Ameiurus catus* and both channel catfish *Ictalurus punctatus* and blue catfish *I. furcatus* were unsuitable for commercial purposes because many were deformed. These abnormal hybrids were produced because white catfish have 48 chromosomes, while channel catfish and blue catfish have 58 chromosomes (LeGrande et al. 1984).

Deformed fish can be produced during breeding programs that involve chromosomal manipulation

(e.g., Chourrout, 1980 1982; Thorgaard et al., 1981; Cassani and Caton, 1986; Chao et al., 1986; Chen et al., 1986; Myers, 1986; Cherfas et al., 1990, 1993; Myers and Hershberger, 1991; Gray et al., 1993; Yamazaki and Goodier, 1993). These deformities can be either genetic or environmental.

Because all hatchery populations contain deformed individuals, farmers and hatchery managers should routinely monitor their fish and catalog abnormalities (written description and photograph) and calculate the frequencies. This is critical, because it is the only way to determine if certain abnormalities recur annually and if the frequencies are increasing.

If the frequency of an abnormality increases, the effects that it has on production traits and marketability should be studied. Some deformities have been shown to adversely affect growth, survival, hatchability, disease resistance, or other traits (Tave et al. 1983; Koumoundouros et al., 1997). On the other hand, some can improve market value. For example, bizarre phenotypes such as telescope eyes in goldfish *Carassius auratus* are desired by tropical fish fanciers, and common carp *Cyprinus carpio*, with abnormal scale patterns command higher market prices in some locales.

This paper describes 31 gross deformities that have been observed in tilapia and provides some information on their frequencies and causes. Twenty-one were described in published reports; the others were obtained from a survey.

Fin Deformities

Saddleback

This abnormality was discovered in the Auburn University population of *O. aureus* (Tave et al., 1983). Bondari (1984) observed it in a population of *O. aureus* at the University of Georgia, Tifton, GA; that population was founded by fish that came from Auburn University. It was observed in *O. aureus* in the St. John River, Florida (Zale A, University of Florida, Gainesville, FL, USA, pers. comm.); he estimated that the frequency was 0.05%.

Saddlebacks lack parts of or all of the dorsal fin. Fin ray loss was variable; some individuals were missing only the first 1 or 2 hard spines, while others had no dorsal fin (Fig. 1). In some saddlebacks, the pectoral, pelvic and/or anal fins were either deformed or missing. Vertebrae 1-3 were always deformed, and this resulted in curvature of the spine and affected body length. Missing spines and rays in the dorsal fin were accompanied by missing pterygiophores; this produced the depression of the dorsal margin of the




Fig. 1. Saddleback in *Oreochromis aureus* (b-n), showing the variable expression of the phenotype; (a) is a normal individual. Source: Tave et al. (1983) J Fish Dis 6, 59-73; with permission, courtesy of Journal of Fish Diseases.

body. Deformed or missing paired fins were accompanied by abnormal or missing bones in the pectoral and/or pelvic girdles.

Saddleback is produced by an autosomal dominant lethal allele that exhibits incomplete dominance. Homozygous dominant individuals (SS) are aborted; heterozygotes ($S+$) are saddlebacks; homozygous recessive ($++$) individuals are normal.

The $S+$ genotype (the genotype that produces saddleback) had adverse pleiotropic effects on viability and disease resistance: 67% of saddlebacks died during the first 2-3 months. When challenged by *Saprolegnia* sp., 33% of saddlebacks died, while only 5% of normal fish died.

Because this abnormality is produced by a dominant allele, a single generation of selection

where all saddlebacks are culled will eliminate the deformity.

Abella (Abella TO, University College of Swansea, Wales, UK, pers. comm.) observed a similar phenotype in *O. niloticus*. In a sample of 1,000 fish, 10 had no dorsal fin.

Caudal Deformity Syndrome (CDS)

CDS was discovered in the Lake Manzala strain of *O. niloticus* maintained at University College of Swansea, Wales (Mair 1992). The deformity was characterized at the first feeding stage by the reduction of the caudal fin; additionally, there was an upward curvature of the caudal region of the spine (Fig. 2). Fish with CDS also had deformed opercula; they were not fully developed, and some gill lamellae were exposed. Fish with this deformity were unable to swim efficiently. No fish with CDS lived more than 7 days after yolk sac absorption.

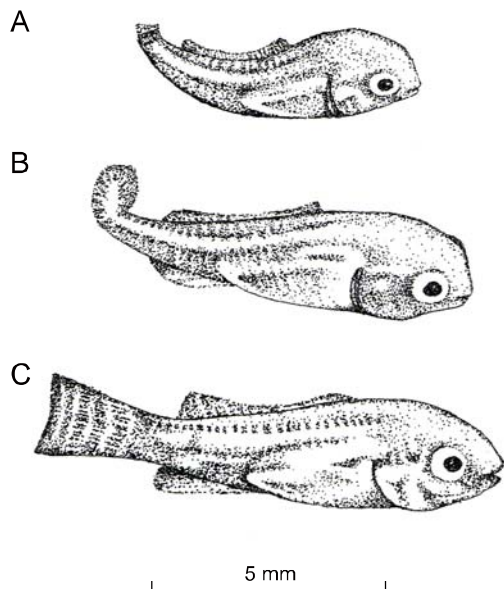


Fig. 2. Caudal deformity syndrome in *Oreochromis niloticus* (A and B), illustrating the extreme expressions of the phenotype; (C) is a normal individual. Source: Mair (1992) J Fish Dis 15, 71-75; with permission, courtesy of Journal of Fish Diseases.

Breeding experiments revealed that this deformity is produced by an autosomal recessive allele; CDS is produced by the recessive allele: ++ and +m fish are normal, while mm fish have CDS.

If this phenotype exists in a population of *O. niloticus*, it can adversely affect fingerling production, since 25% of the offspring produced by the mating of two heterozygotes will die. Because this deformity is

produced by a recessive allele, selection cannot eliminate the allele. Progeny testing must be used to eliminate the allele.

No dorsal fin

This deformity was observed in *O. niloticus* during a sex reversal study; 1,114 of 5,416 had this deformity. Survival of the fish with no dorsal fin was similar to that of normal fish (Guilherme 1992). Pasnik et al. (2007) found that *Streptococcus agalactinae* could produce this deformity in *O. niloticus*.

No dorsal and no anal fin

This deformity was observed in *O. niloticus* during a sex reversal study (Fig. 3). A subsequent breeding study revealed that the deformity was heritable (Guilherme, 1994).



Fig. 3. *Oreochromis niloticus* without dorsal and anal fins. Source: Guilherme (1994) Cienc Pratica Lavras 18, 123-124; with permission, courtesy of Ciencia e Pratica, Lavras.

Tailless

This phenotype has been observed in several stocks of *O. niloticus*. It was first described in AU-I *O. niloticus* (Tave et al., 1982). Tailless individuals were missing the caudal peduncle and the caudal fin (Fig. 4b). Tailless fish had only 26 vertebrae, 3 fewer than normal fish. Vertebrae 20-26 were deformed, causing curvature of the spine; this demonstrated that the deformity was not due to injury. Only two tailless individuals were found, and they died before they could be spawned. Phelps and Karsina (pers. comm.) surveyed a population of 7,200 AU-I *O. niloticus* fingerlings, and observed one tailless individual.

A tailless individual was observed in a population in Saudi Arabia (George, 2006; George TT, pers. comm., Global Aquaculture Consultants, Toronto, ON, Canada).




Fig. 4. Stumpbody in *Oreochromis aureus* (c and d) and tailless in *O. niloticus* (b), compared to a normal *O. aureus* (a). Source: Tave et al. (1982) 5, 487-494; with permission, courtesy of Journal of Fish Diseases.

A tailless individual was observed in the population maintained at the Pukyong National University, Busan, Korea (Jo and Kim, unpublished data.). Abella (Abella TO, pers. comm.) found 10 tailless fish in a survey of 1,000 *O. niloticus* at the University College of Swansea, Wales.

Pasnik et al. (2007) found that *S. agalactinae* could produce this deformity in *O. niloticus*.

No anal fin

Guilherme (1992) found 863 *O. niloticus* with no anal fin in a population of 5,456 fish during a sex reversal study. Survival of the deformed fish was 3.4%.

Phelps and Karsina (pers. comm.) surveyed a population of 234 AU-I *O. niloticus* brood fish and observed two that had no anal fin. Tave et al. (1983) found one *O. aureus* saddleback with no anal fin, but that individual had no fins except for the caudal fin (Fig. 1n).

Pasnik et al. (2007) found that *S. agalactinae* could produce this deformity in *O. niloticus*.

No pelvic fin

Guilherme (1992) found 644 *O. niloticus* with this deformity in a population of 5,456 fish during a sex reversal study. Survival of the deformed fish was 46.9%. Tave et al. (1983) found some saddleback *O. aureus* that were missing pelvic fins.

Pasnik et al. (2007) found that *S. agalactinae* could produce this deformity in *O. niloticus*.

Fusion of dorsal and anal fins

Eissa et al. (2009) found this deformity in *O. niloticus* in Egypt. The deformity constricted and twisted the body (Fig. 5).

Swayback

This deformity was observed in the Auburn University population of *O. mossambicus* (Tave, unpublished data). Swaybacks were missing the middle portion of the dorsal fin. Twenty-four individuals were observed when fish were 2-4 cm. All died within a week of discovery.

Split fins

Oreochromis spp. with split fins were observed in polluted rivers in Taiwan; 1-87.5% of the fish observed had this deformity (Sun et al. 2009).

Body Deformities

Stumpbody

Stumpbody was discovered in the Auburn University population of *O. aureus* (Tave et al., 1982). Stumpbodies were dwarfs, whose body was shortened along the anterior-posterior axis (Fig. 4c and 4d). The posterior portion of the trunk appeared to be compressed. The trunk was much thicker than that of normal fish, and the relative body depth was also greater.

Stumpbodies had gross skeletal deformities. They had 15 vertebrae, which was approximately half the




Fig. 5. Fusion of dorsal and anal fins (3B) in *O. niloticus*; 3A is a normal individual. 4 are radiographs of the normal (4A) and deformed (4B) individuals. Source: Eissa et al. (2009) *Chemosphere* 77, 419-425; with permission, courtesy of Chemosphere.

number found in normal fish (29). Many vertebrae were grossly deformed, which resulted in marked curvature of the spine. Vertebral deformities varied considerably among stumpybodies; no two individuals were identical. Breeding experiments revealed that it was not heritable.

Eissa et al. (2009) observed this phenotype in farmed populations of *O. niloticus* in Egypt. Eissa (Eissa AE, Faculty of Veterinary Medicine, Cairo University, Giza, Egypt pers. comm.) was able to produce stumpybodies by experimental infection with *Aspergillus ochraceus*.

A similar phenotype was observed in Lake Manzala strain *O. niloticus* at University College of Swansea, Wales, (Mair GC, Central Luzon State University, Nueva Ecija, Philippines, pers. comm.) and in a strain of "Florida red tilapia," (a strain derived from *O. urolepis hornorum* ♀ × *O. mossambica* ♂ matings) (Watanabe WO, Caribbean Marine Research Center, Vero Beach, FL, USA, pers. comm.); he estimated that the frequency of the deformity in the hybrid population was 0.014-0.02%.

Runts

Phelps and Karsina (pers. comm.) found 19 runts in a survey of 7,200 AU-I *O. niloticus* fingerlings. These fish were one-half to one-quarter the size of their sibs and did not grow well. It is not known if this was a morphological deformity or a physiological defect, such as a malfunctioning pituitary.

Ra'anán and Lahav (Ra'anán Z and Lahav E, Aquaculture Production Technologies, Ltd., Jerusalem, Israel, pers. comm.) found runts in the ND5 female line of *O. niloticus*. They described the fish as exceptionally short and flat, and the deformity appears at a constant frequency of 2%.

Flattened body

This deformity was produced in F₂ *O. mossambicus* × *O. niloticus* hybrids at the University of Wales, Swansea (Shah 1984). Sperm from F₁ hybrid males had been treated with 0.005 M of methyl methane sulphonate (a mutagen). A single fish with a flattened body was produced by this treatment.

Bent tail

This deformity was produced in *O. niloticus* from Stirling University, Stirling Scotland (Shah 1984). It was produced from matings where males had been injected with 50 mg methyl methane sulphonate/kg body weight IP prior to spawning. Individuals with this deformity has marked curvature of the body; the caudal area and tail was bent laterally at a right angle.

Operculum Deformities

Deformed opercula, described as "semi-operculum," were observed in both Auburn University-Egypt strain *O. niloticus* and Auburn University population of *O. mossambicus* (Handwerker and Tave, 1994; Tave and Handwerker, 1994). Fish with this deformity had a shortened operculum that exposed part of the gills (Fig. 6). All fish had one normal and one deformed operculum. The deformity was variable, in that some fish with a semi-operculum had a deformed operculum that was minimally shortened, while others had an operculum that so deformed that most of the gill lamellae were exposed. Breeding studies with both species revealed that the deformity was not genetic.

Phelps and Karsina (pers. comm.) found 2 fish with this deformity in their survey of 7,200 AU-I *O. niloticus*.




Fig. 6. Semi-operculum in *Oreochromis niloticus*. The deformity is identical in *O. mossambicus*. Source: Tave and Handwerker (1994) J World Aquac Soc 25, 333-336; with permission, courtesy of Journal of the World Aquaculture Society .

An incompletely developed operculum in tilapia can be produced by environmental contaminants and by infection. Clemens and Inslee (1968) observed fish with what they described as a “poorly formed opercle” in *O. mossambicus* that had consumed methyl testosterone-treated feed during a sex-reversal study; the deformity was not observed in the control. Pasnik et al. (2007) found that *S. agalactiae* could produce this deformity in *O. niloticus*. Sun et al. (1998, 2009) found that this deformity in *O. niloticus* and *O. mossambicus* in rivers in Taiwan. Sun et al. (2009) found that it could be produced in *O. niloticus* by low levels of dissolved oxygen, high levels of ammonia, and by heavy metals.

Eye Deformities

Anophthalmia

Anophthalmia (the congenital absence of one or both eyes) was observed in the Auburn University

population of *O. mossambicus* (Tave and Handwerker, 1998). Seven anophthalmics were observed; five were missing the left eye, and two were missing the right eye. The area over the missing eye was covered with scales and the skull was slightly depressed. When viewed dorsally, the skull appeared to be slightly curved (Fig. 7). A breeding study revealed that the deformity was not heritable.

In a survey of 1,000 fish in the *O. niloticus* population at the University College of Swansea, Abella (Abella TO, pers. comm.) observed 3 anophthalmics.

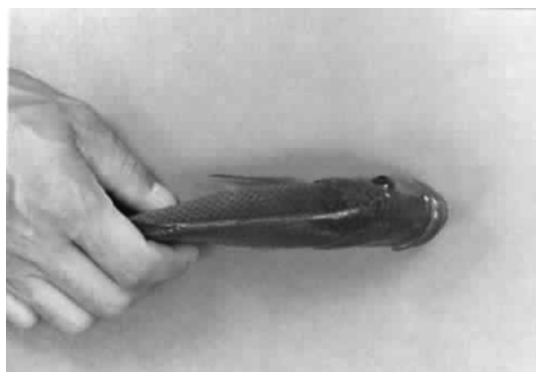

Fig. 7. Anophthalmia in *Oreochromis mossambicus*. Source: Tave and Handwerker (1998) Ribarstvo 56, 125-130; with permission, courtesy of Ribarstvo.

Four eyes

A single four-eyed fish (Fig. 8) was observed in *O. niloticus* at the Tennessee Valley Authority Hatchery, Muscle Shoals, AL (Jo, unpublished data). The fish died shortly after it was observed.

Both eyes on one side

This deformity was observed in a *O. niloticus* population at the University College of Swansea, (Abella TO, pers. comm.); the position of the eyes was described as similar to that of most flounders.

Less developed eyes

This deformity was produced in *O. niloticus* from Stirling University (Shah, 1984). It was produced from matings where males had been injected with 50 mg methyl methane sulphonate/kg body weight IP prior to spawning. Eyes in fish with this deformity were significantly smaller than those of normal fish.

Fused eyes

This deformity was observed in *O. aureus* maintained at the University of Wales (Mair GC, pers. comm.). The anterior-most portion of the head in these fish was flat and the eyes were fused at the

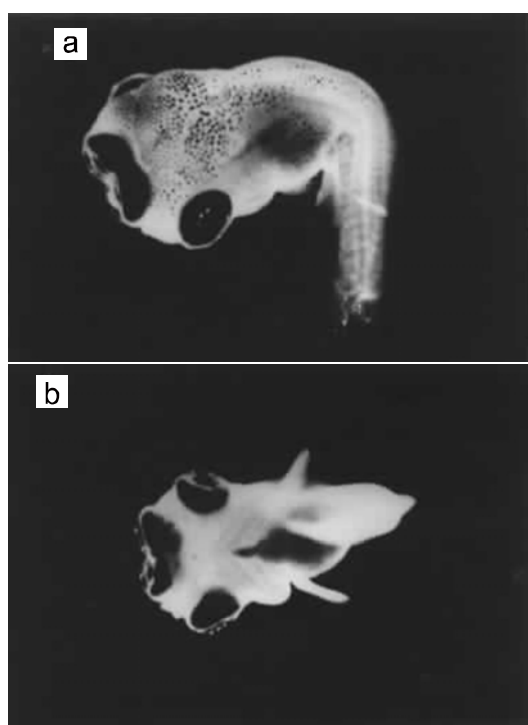


Fig. 8. A four-eyed in *Oreochromis niloticus*. (a) Dorsal view. (b) Ventral view. Photograph by Jae-Yoon Jo.

flattened front. These fish also had the deformity called “protruding jaw.” Three fish with fused eyes were observed. A breeding experiment revealed that the deformity was not genetic.

Jaw Deformities

Bullhead

This deformity was produced in F_2 *O. mossambicus* \times *O. niloticus* hybrids at the University of Wales (Shah, 1984). Sperm from F_1 hybrid males had been treated with 0.05 M of methyl methane sulphonate. Three bullheads were produced. The lower jaw of these fish was much larger than that of normal fish. A breeding study showed that the deformity was not genetic.

Upturned mouth

This deformity was produced in F_2 *O. niloticus* \times *O. mossambicus* hybrids at the University of Wales (Shah, 1984). Sperm from F_1 hybrid males were treated with 0.05 M of methyl methane sulphonate. A single fish with upturned mouth was produced. The mouth in the deformed individual terminated in an upward direction.

Deformed lower jaw

Clemens and Inslee (1968) reported that some *O. mossambicus* that had consumed methyl testosterone-treated feed during a sex-reversal breeding program had a deformed lower jaw, but the deformity was not described. No fish in the control population had this deformity.

Protruding jaw

This deformity was observed in *O. aureus* maintained at the University of Wales (Mair GC, pers. comm.). Fish with this deformity had a jaw that protruded in a tube-like fashion, and the mouth was at the end of the jaw. These fish also had the fused eye deformity. Three fish with protruding jaw were observed. A breeding experiment revealed that the deformity was not genetic.

A similar deformity named “lower lip extension” was observed in *O. niloticus* found in polluted rivers in Taiwan (Sun et al., 1998, 2009).

Lateral projection of mandibles

This deformity was observed in farmed populations of *O. niloticus* in Egypt (Eissa et al. 2009). The deformity is characterized by a lateral bowing of the mandibles with outward thickening of the lateral sides of the mandibles (Eissa AE, pers. comm.)

Head Deformities

Foreshortened head

Clemens and Inslee (1968) observed this deformity in *O. mossambicus* that had consumed methyl testosterone-treated feed during a sex reversal study; the deformity was not observed in the control population.

Parrot-like head

This deformity was observed in a farmed population of *O. niloticus* in Egypt (Eissa et al., 2009). The anterior portion of the head above the mouth is stunted, given the fish a protruding mouth (Fig. 9).

Microcephaly

Microcephaly, an abnormal reduction in head size, was observed in *O. niloticus* from Stirling University (Shah, 1984). It was produced from matings where males had been injected with 50 mg methyl methane sulphonate/kg body weight IP prior to spawning.

Yolk Sac Deformities

Double yolk sac

Rothbard et al. (1980) described an *O. urolepis*

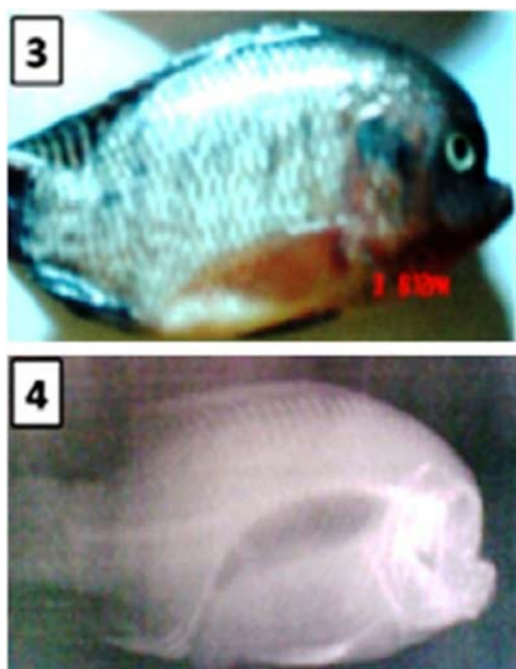


Fig. 9. Parrot-like head in *O. niloticus*, with a radiograph of the deformity. Source: Eissza et al. (2009) *Chemosphere* 77, 419-425; with permission, courtesy of Chemosphere.

hornorum fry with a double yolk sac. The yolk sac was large and partially constricted in the middle.

Enlarged yolk sac

This deformity was produced in *O. niloticus* from Stirling University (Shah, 1984). It was produced from matings where males had been injected with 50 mg methyl methane sulphonate/kg body weight prior to spawning. Individuals with this deformity had yolk sacs that were significantly larger than those possessed by normal individuals.

Conjoined Twins

Hulata and Rothbard (1978) described two sets of conjoined twins that they found in *O. mossambicus* and one from an *O. urolepis* ♀ × *O. niloticus* ♂ hybrid mating. Rothbard et al. (1980) described one set of conjoined twins from an *O. niloticus* ♀ × *O. aureus* ♂ hybrid mating. Owusu-Frimpong and Hargreaves (2000) found conjoined *O. aureus* following heat shock of fertilized eggs. Four sets of conjoined twins were observed from a total of 100 spawns (70,000-100,000 eggs) that were produced by 14 *O. niloticus* females at the Pukyong National University, Busan (Fig. 10) (Jo and Kim, unpublished data). Abella (Abella TO, pers. comm.) observed conjoined *O.*



Fig. 10. Conjoined twin in *Oreochromis niloticus*. Photograph by Dong Soo Kim.

niloticus. Abiado (Abiado MA, Central Luzon State University, Nueva Ecija, Philippines, pers. comm.) observed 4 sets of conjoined twins in a population of 2,500 *O. niloticus* × *O. aureus* hybrid swim-up fry. Mair (Mair G, pers. comm.) observed conjoined twins in both *O. niloticus* and *O. aureus* stocks maintained at the University of Wales. Tave (unpublished data) observed a set of AU-I *O. niloticus* conjoined twins.

Conclusion

All fish populations contain abnormal individuals. Thirty-one gross abnormalities in tilapia were described in this review. Fin abnormalities accounted for almost a third of those that were observed (10), followed by abnormalities of the eye (five), jaw (five), body shape (four), head (three), yolk sac (two), operculum (one), and conjoined twins. It is often assumed that abnormalities have a genetic basis and that they are a clinical sign of inbreeding depression, but this survey shows that only three of nine abnormalities that were subjected to genetic studies were heritable, and one was caused by a dominant allele which means that it was not a side effect of inbreeding. Most abnormalities are non-heritable, and this survey shows that that abnormalities in tilapia can be produced by pathogens, by pollutants and other chemicals, by heat shock, and by sex reversal. Because abnormalities can decrease yields and profits, it is important to census a managed population to catalog the abnormalities. A yearly census will let managers know how many abnormalities are present and whether the percent is increasing over time. An increase in percent deformities or of a particular deformity can be an indication that a problem exists. If a deformity becomes problematic, a study should be conducted to determine the cause and possible solutions.

Acknowledgments

We thank R.P. Phelps, T.O. Abella, E. Karsina, A. Zale, G.C. Mair, W.O. Watanabe, M.A. Abiabo, Z. Ra'anan, E. Lahev, T.T. George, and A.E. Eissa for providing unpublished information about deformities they have observed in their populations of tilapia. We thank A.E. Eissa and L.C. Guilherme for providing Figs. 5 and 9 and Fig. 3, respectively. We thank the following for allowing us to use copyrighted figures in this review: Journal of Fish Diseases (Figs. 1, 2, and 4); Ciencia e Pratica, Lavras (Fig. 3); Chemosphere (Figs. 5 and 9); Journal of the World Aquaculture Society (Fig. 6); Ribarstvo (Fig. 7). We sent a questionnaire to selected people several years ago, and use the addresses that correspondents had at the time of the survey.

References

- Aida T. 1930. Further genetical studies of *Aplocheilichthys latipes*. Genetics 15, 1-16.
- Afonso JM, Montero D, Robaina L, Astorga N, Izquierdo MS and Ginés R. 2000. Association of a lordosis-scoliosis-kyphosis deformity in gilthead seabream (*Sparus aurata*) with family structure. Fish Physiol Biochem 22, 159-163.
- Andrews JW and Murai T. 1975. Studies on the vitamin C requirements of channel catfish (*Ictalurus punctatus*). J Nutr 105, 557-561.
- Aulstad D and Kittelsen A. 1971. Abnormal body curvatures of rainbow trout (*Salmo gairdneri*) inbred fry. J Fish Res Board Can 28, 1918-1920.
- Backiel T, Kokurewicz B and Ogorzałek A. 1984. High incidence of skeletal anomalies in carp, *Cyprinus carpio*, reared in cages in flowing water. Aquaculture 43, 369-380.
- Beck ML and Biggers CJ. 1983. Ploidy of hybrids between grass carp and bighead carp determined by morphological analysis. Trans Am Fish Soc 112, 808-811.
- Blanc JM and Chevassus B. 1986. Survival, growth and sexual maturation of the tiger trout hybrid (*Salmo trutta* ♀ × *Salvelinus fontinalis* ♂). Aquaculture 52, 59-69.
- Blanc JM and Poisson H. 1983. Parental sources of variation in hatching and early survival rates of *Salmo trutta* ♀ × *Salvelinus fontinalis* ♂ hybrid. Aquaculture 32, 115-122.
- Bondari K. 1984. A study of abnormal characteristics of channel catfish and blue tilapia. Proc Southeast Assoc Fish Wildl Agencies 35 (1981), 566-578.
- Breder CM Jr. 1953. A case of survival of a goldfish following the loss of its tail. Zoologica 38, 49-52.
- Cassani JR and Caton WE. 1986. Efficient production of triploid grass carp (*Ctenopharyngodon idella*) utilizing hydrostatic pressure. Aquaculture 55, 43-50.
- Castro J, Pino-Querido A, Hermida M, Chavarrias D, Romero R, García-Cortés LA, Toro MA and Martínez P. 2008. Heritability of skeleton abnormalities (lordosis, lack of operculum) in gilthead seabream (*Sparus aurata*) supported by microsatellite family data. Aquaculture 279, 18-22.
- Chao NH, Chen SJ and Liao IC. 1986. Triploidy induced by cold shock in cyprinid loach, *Misgurnus anguillicaudatus*. In: The First Asian Fisheries Forum. Maclean JL, Dizon LB and Hosillos LV, eds. Asian Fisheries Society, Manila, PH, pp. 101-104.
- Chappell JA. 1979. An Evaluation of Twelve Genetic Groups of Catfish for Suitability in Commercial Production. Ph.D. Dissertation, Auburn University, Auburn, AL, US.
- Chen SJ, Chao NH and Liao IC. 1986. Diploid gynogenesis induced by cold shock in cyprinid loach, *Misgurnus anguillicaudatus*. In: The First Asian Fisheries Forum. Maclean JL, Dizon LB and Hosillos LV, eds. Asian Fisheries Society, Manila, PH, pp. 105-108.
- Cherfas NB, Kozinsky O, Rothbard S and Hulata G. 1990. Induced gynogenesis and triploidy in ornamental (koi) carp, *Cyprinus carpio* L. Isr J Aquac Banidgeh 42, 3-9.
- Cherfas NB, Hulata G and Kozinsky O. 1993. Induced diploid gynogenesis and polyploidy in ornamental (koi) carp, *Cyprinus carpio* L. 2. Timing of heat shock during the first cleavage. Aquaculture 111, 281-290.
- Chourrout D. 1980. Thermal induction of diploid gynogenesis and triploidy in the eggs of the rainbow trout (*Salmo gairdneri* Richardson). Reprod Nutr Dev 20, 727-733.
- Chourrout D. 1982. Tetraploidy induced by heat shocks in the rainbow trout (*Salmo gairdneri* R.). Reprod Nutr Dev 22, 569-574.
- Clemens HP and Inslee T. 1968. The production of unisexual broods by *Tilapia mossambica* sex-reversed with methyl testosterone. Trans Am Fish Soc 97, 18-21.
- Couch JA, Winstead JT, Hansen DJ and Goodman LR. 1979. Vertebral dysplasia in young fish exposed to the herbicide trifluralin. J Fish Dis 2, 35-42.
- Dawson CE. 1964. A bibliography of anomalies of fishes. Gulf Res Rep 1, 308-399.
- Dawson CE. 1966. A bibliography of anomalies of fishes, supplement 1. Gulf Res Rep 2, 169-176.
- Dawson CE. 1971. A bibliography of anomalies of fishes,

- supplement 2. Gulf Res Rep 3, 215-239.
- Dawson CE and Heal E. 1976. A bibliography of anomalies of fishes, supplement 3. Gulf Res Rep 5, 35-41.
- Dunham RA, Smitherman RO and Bondari K. 1991. Lack of inheritance of Stumpbody and taillessness in channel catfish. Prog Fish-Cult 53, 101-105.
- Eissa AE, Moustafa M, El-Husseiny IN, Saeid S, Saleh O and Borhan T. 2009. Identification of some skeletal deformities in freshwater teleosts raised in Egyptian aquaculture. Chemosphere 77, 419-425.
- Garside ET. 1959. Some effects of oxygen in relation to temperature on the development of lake trout embryos. Can J Zool 37, 689-698.
- George TT. 2006. Survival of a deformed "miracle fish" *Oreochromis niloticus* [sic] in an intensive water recirculating system. Bull Aquac Assoc Can 106-3, 28-32.
- Grady AW, Fabacher DL, Frame G and Steadman BL. 1992. Morphological deformities in brown bullheads administered dietary β -naphthoflavone. J Aquat Anim Health 4, 7-16.
- Gray AK, Evans MA and Thorgaard GH. 1993. Viability and development of diploid and triploid salmonid hybrids. Aquaculture 112, 125-142.
- Guilherme LC. 1992. Teste de progênie em *Oreochromis niloticus* (Trewavas, 1982) submetidos a inversão sexual. Cienc Pratica Lavras 16, 283-287.
- Guilherme LC. 1994. Constatação, seleção e reprodução da Tilápia nilótica *Oreochromis niloticus* sem as nadadeiras dorsal e anal. Cienc Pratica Lavras 18, 123-124.
- Gunter G and Ward JW. 1961. Some fishes that survive extreme injuries, and some aspects of tenacity of life. Copeia 1961, 456-462.
- Handwerker TS and Tave D. 1994. Semioperculum: a nonheritable deformity in Mozambique tilapia. J Aquat Anim Health 6, 85-88.
- Hoffman GL. 1984. Two fish pathogens, *Parvicapsula* sp. and *Mitraspora cyprini* (Myxosporea), new to North America. Symp Biol Hung 23, 127-135.
- Hoffman GL, Dunbar CE and Bradford A. 1962. Whirling Disease of Trout Caused by *Myxosoma cerebralis* in the United States. Special Scientific Report, Fisheries No. 427. U.S. Fish and Wildlife Service, Washington, DC, US.
- Hulata G and Rothbard S. 1978. "Siamese-twins" in *Sarotherodon mossambicus*. J Fish Biol 13, 45.
- Ihssen P. 1978. Inheritance of bluesac disease for hatchery charr of the genus *Salvelinus*. Environ Biol Fish 3, 317-320.
- Kincaid HL. 1976. Inbreeding in rainbow trout (*Salmo gairdneri*). J Fish Res Board Can 33, 2420-2426.
- Koumoundouros G, Oran G, Divanach P, Stefanakis S and Kentouri M. 1997. The opercular complex deformity in intensive gilthead sea bream (*Sparus aurata* L.) larviculture. Moment of apparition and description. Aquaculture 156, 165-177.
- Krise WF and Smith RA. 1993. Eye abnormalities of lake trout exposed to gas supersaturation. Prog Fish-Cult 55, 177-179.
- Kurokura H, Kumai H and Nakamura M. 1986. Hybridization between female red sea bream (*Pagrus major*) and male crimson sea bream (*Evynnis japonica*) by means of sperm cryopreservation. In: The First Asian Fisheries Forum. Maclean JL, Dizon LB and Hosillos LV, eds. Asian Fisheries Society, Manila, PH, pp. 113-116.
- Leary RF, Allendorf FW and Knudsen KL. 1991. Effects of rearing density on meristics and developmental stability of rainbow trout. Copeia 1991, 44-49.
- LeGrande WH, Dunham RA and Smitherman RO. 1984. Karyology of three species of catfishes (Ictaluridae: *Ictalurus*) and four hybrid combinations. Copeia 1984, 873-878.
- Lim C and Lovell RT. 1978. Pathology of the vitamin C deficiency syndrome in channel catfish (*Ictalurus punctatus*). J Nutr 108, 1137-1146.
- Lodi E. 1978. Palla: a hereditary vertebral deformity in the guppy, *Poecilia reticulata* [sic] Peters (Pisces, Osteichthyes). Genetica 48, 197-200.
- Mair GC. 1992. Caudal deformity syndrome (CDS): an autosomal recessive lethal mutation in the tilapia, *Oreochromis niloticus* (L.). J Fish Dis 15, 71-75.
- Matsui Y. 1934a. Genetical studies on gold-fish of Japan. 2. On the Mendelian inheritance of the telescope eyes of gold-fish. J Imp Fish Inst 30, 37-46.
- Matsui Y. 1934b. Genetical studies on gold-fish of Japan. 4. On the inheritance of caudal and anal fins of gold-fish. J Imp Fish Inst 30, 67-96.
- Mayer FL, Mehrle PM and Crutcher PL. 1978. Interactions of toxaphene and vitamin C in channel catfish. Trans Am Fish Soc 107, 326-333.
- McKay LR, Ihssen PE and McMillan I. 1992. Early mortality of tiger trout (*Salvelinus fontinalis* \times *Salmo trutta*) and the effects of triploidy. Aquaculture 102, 43-54.
- Michie I. 2001. Causes of downgrading in the salmon industry. In: Farmed Fish Quality. Kestin SC and Warriss PD, eds. Fishing News Books, Oxford, GB, pp. 129-136.
- Mrakovčić M and Haley LE. 1979. Inbreeding depression in the zebra fish *Brachydanio rerio* (Hamilton Buchanan). J Fish Biol 15, 323-327.
- Murai T and Andrews JW. 1978. Riboflavin requirement of channel catfish fingerlings. J Nutr 108, 1512-1517.
- Myers JM. 1986. Tetraploid induction in *Oreochromis* spp. Aquaculture 57, 281-287.

- Myers JM and Hershberger WK. 1991. Early growth and survival of heat-shocked and tetraploid-derived triploid rainbow trout (*Oncorhynchus mykiss*). *Aquaculture* 96, 97-107.
- Owusu-Frimpong M and Hargreaves JA. 2000. Incidence of conjoined twins in tilapia after thermal shock induction of polyploidy. *Aquac Res* 31, 421-426.
- Pasnik DJ, Evans JJ and Klesius PH. 2007. Development of skeletal deformities in a *Streptococcus agalactiae*-challenged male Nile tilapia (*Oreochromis niloticus*) broodfish and in its offspring. *Bull Eur Assoc Fish Pathol* 27, 169-176.
- Piron RD. 1978. Spontaneous skeletal deformities in the zebra danio (*Brachydanio rerio*) bred for fish in toxicity tests. *J Fish Biol* 13, 79-83.
- Rogers KT. 1956. Re-examination of the production of cyclopia in *Fundulus heteroclitus* with magnesium chloride and ethyl alcohol. *Biol Bull* 110, 344-351.
- Romanov NS. 1984. Effect of culture conditions on skull morphology in smolts of the masu salmon, *Oncorhynchus masou* (Brevoort). *Aquaculture* 41, 147-153.
- Rosenthal HL and Rosenthal RS. 1950. Lordosis, a mutation in the guppy, *Lebistes reticulatus*. *J Hered* 41, 217-218.
- Rothbard S, Hulata G and Itzkovich J. 1980. Abnormalities in *Sarotherodon* larvae. *J Fish Dis* 3, 441-442.
- Rucker RR, Yasutake WT and Wedemeyer G. 1970. An obscure disease of rainbow trout. *Prog Fish-Cult* 32, 3-8.
- Sawada Y, Hattori M, Sudo N, Kato K, Takagi Y, Ura K, Kurata M, Okada T and Kumai H. 2006. Hypoxic conditions induce centrum defects in red sea bream *Pagrus major* (Temminck and Schlegel). *Aquac Res* 37, 805-812.
- Schröder JH. 1969. Inheritance of radiation-induced spinal curvatures in the guppy, *Lebistes reticulatus*. *Can J Genet Cytol* 11, 937-947.
- Schultz RJ. 1963. Stubby, a hereditary vertebral deformity in the viviparous fish *Poeciliopsis prolifica*. *Copeia* 1963, 325-330.
- Shah MS. 1984. Genetic studies in *Poecilia* and *Tilapia*. Ph.D. Dissertation, University of Wales, Swansea, Wales, GB.
- Sullivan M, Hammond G, Roberts RJ and Manchester NJ. 2007. Spinal deformation in commercially cultured Atlantic salmon, *Salmo salar* L.: a clinical and morphological study. *J Fish Dis* 30, 745-752.
- Sun PE, Hawkins WE, Overstreet RM and Brown-Peterson NJ. 2009. Morphological deformities as biomarkers in fish from contaminated rivers in Taiwan. *Int J Environ Res Public Health* 6, 2307-2331.
- Sun PL, Brown-Peterson NJ, Hawkins WE, Overstreet RM, Krol RM, Tsaio SH and Zhu Y. 1998. Morphological and histological abnormalities in tilapia (*Oreochromis* spp.) from two contaminated rivers in southern Taiwan. *Environ Sci* 6, 129-152.
- Tave D. 1993. *Genetics for Fish Hatchery Managers*. 2nd ed. Van Nostrand Reinhold, New York, NY, US.
- Tave D. 1999. *Inbreeding and Brood Stock Management*. Food and Agriculture Organization of the United Nations, Rome, IT.
- Tave D and Handwerker TS. 1994. Semi-operculum: a non-heritable birth defect in *Tilapia nilotica*. *J World Aquac Soc* 25, 333-336.
- Tave D and Handwerker TS. 1998. Anophthalmia: a non-heritable eye deformity in *Oreochromis mossambicus*. *Ribarstvo* 56, 125-130.
- Tave D, Bartels JE and Smitherman RO. 1982. Stumpbody *Sarotherodon aureus* (Steindachner) (= *Tilapia aurea*) and tail-less *S. niloticus* (L.) (= *T. nilotica*): two vertebral anomalies and their effects on body length. *J Fish Dis* 5, 487-494.
- Tave D, Bartels JE and Smitherman RO. 1983. Saddleback: a dominant lethal gene in *Sarotherodon aureus* (Steindachner) (= *Tilapia aurea*). *J Fish Dis* 6, 59-73.
- Thomerson JE. 1966. The stubby vertebral deformity in aquarium-raised *Fundulus cingulatus*. *Copeia* 1966, 878-879.
- Thorgaard GH, Jazwin ME and Stier AR. 1981. Polyploidy induced by heat shock in rainbow trout. *Trans Am Fish Soc* 110, 546-550.
- Tukeuchi K. 1966. "Wavy-fused" mutants in the medaka, *Oryzias latipes*. *Nature* 211, 866-867.
- Verhaegen Y, Adriaens D, De Wolf T, Dhert P and Sorgeloos P. 2007. Deformities in larval gilthead seabream (*Sparus aurata*): a qualitative and quantitative analysis using geometric morphometrics. *Aquaculture* 268, 156-168.
- Wargelius A, Fjellidal PG and Hansen T. 2005. Heat shock during early somatogenesis induces caudal vertebral column defects in Atlantic salmon (*Salmo salar*). *Dev Genes Evol* 215, 350-357.
- Wiegand MD, Hataley JM, Kitchen CL and Buchanan LG. 1989. Induction of developmental abnormalities in larval goldfish, *Carassius auratus* L., under cool incubation conditions. *J Fish Biol* 35, 85-95.
- Winemiller KO and Taylor DH. 1982. Inbreeding depression in the convict cichlid, *Cichlasoma nigrofasciatum* (Baird and Girard). *J Fish Biol* 21, 399-402.
- Yamamoto T, Tomita H and Matsuda N. 1963. Hereditary and nonheritable vertebral ankylosis in the medaka, *Oryzias latipes*. *Jpn J Genet* 38, 36-47.
- Yamazaki F and Goodier J. 1993. Cytogenetic effects of

the hydrostatic pressure treatment to suppress the first cleavage of salmon embryos. *Aquaculture* 110, 51-59.

(Received 9 May 2011; Revised 18 May 2011;
Accepted 8 June 2011)