

# Evaluation of the Cause of Internal Jugular Vein Obstruction on Head and Neck Contrast Enhanced 3D MR Angiography Using Contrast Enhanced Computed Tomography

Hye Mi Gweon, Tae-Sub Chung, Sang Hyun Suh

**Purpose :** To evaluate the cause of internal jugular vein (IJV) obstruction on contrast enhanced 3D MR angiography (CE-MRA) using contrast enhanced computed tomography (CE-CT).

**Materials and Methods :** A total number of 30 patients were enrolled, who underwent both head and neck CE-MRA and CE-CT from 2005 to 2008. We defined obstruction group which had IJV obstruction and control group which had no IJV obstruction on CE-MRA. The following parameters were measured from axial images of CE-CT: 1) diameter of IJV; 2) distance between the styloid process and ipsilateral lateral mass of the atlas; 3) maximum area of lateral mass of the atlas. Each parameter was compared between obstruction group and control group.

**Results :** The diameter of IJV and distance between the styloid process and lateral mass of the atlas at IJV obstruction side in obstruction group were  $1.6 \pm 1.0$  mm and  $4.1 \pm 2.1$  mm respectively, which resulted in statistical significance ( $p < 0.01$ ). The maximum area of lateral mass of the atlas at IJV obstruction side in obstruction group was  $103.4 \pm 25.3$  mm<sup>2</sup> which is significantly larger than in control group ( $p < 0.05$ ).

**Conclusion :** We found that the cause of IJV obstruction on CE-MRA could be narrow space between the styloid process and the lateral mass of the atlas, which was related with asymmetric larger area of lateral mass of atlas.

**Index words :** Internal jugular vein  
Atlas  
Computed tomography (CT)  
Magnetic resonance angiography

## Introduction

The internal jugular vein (IJV), which collects much of the blood flow from the cerebrum and cerebellum, is

main cerebral venous outflow tract. Anatomically, IJV immediately below the jugular foramen is located directly above the anterior surface of the lateral mass of the atlas. Depending on the position, the lateral mass of

**JKSMRM 15:41-47(2011)**

Department of Diagnostic Radiology, Gangnam Severance Hospital, Yonsei University Health System, Korea

Received; April 8, 2011, revised; April 13, 2011, accepted; April 14, 2011

Corresponding author : Tae-Sub Chung, M.D., Department of Diagnostic Radiology, Gangnam Severance Hospital

146-92 Dogok-dong, Gangnam-gu, Seoul 135-720, Korea.

Tel. 82-2-2019-3514 Fax. 82-2-3462-5472 E-mail: tschung@yuhs.ac

the atlas indents or kinks the wall of the IJV and causing the obstruction (1-4).

We have observed that the asymmetric obstruction of IJV is occasionally identified in patients who underwent contrast-enhanced MR angiography (CE-MRA). However, it remains unclear whether the asymptomatic obstruction is associated by thrombosis or by secondary compression. Thus neck contrast-enhanced computed tomography (CE-CT) was used for evaluation of the internal jugular vein and surrounding bony morphology. The purpose of our study is to evaluate the cause of high level IJV obstruction on head and neck CE-MRA and CE-CT.

### Materials and Methods

#### Patients

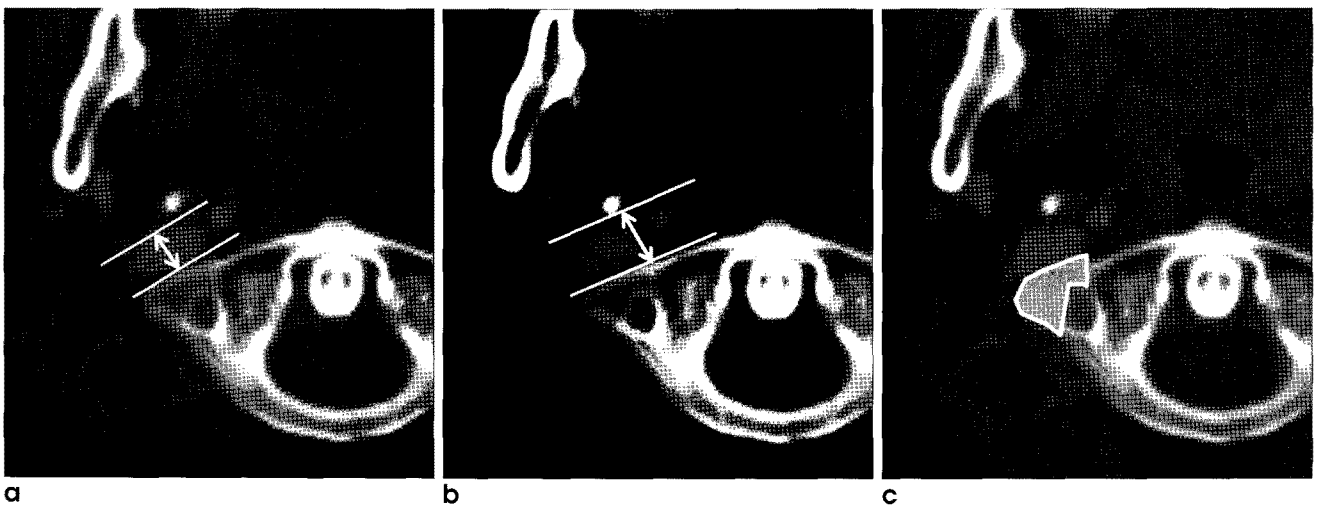
This retrospective study was approved by our institutional review board (IRB), and informed consent was waived.

Head and neck CE-MRA and CE-CT were retrospectively collected from 2005 through 2008 regardless of clinical history. Total 1800 cases of head and neck CE-MRA were reviewed. Finally, thirty patients who performed both head and neck CE-MRA and CE-CT were enrolled in this study. All venous phase images of head and neck CE-MRA were reviewed in terms of the presence of IJV obstruction.

#### Image Acquisition

The neck CE-MRA was performed with a 3T MR unit (Signa® EXCITE™ 3.0T, General Electric Medical Systems, Milwaukee, USA). Three-dimensional neck MRA was performed for arterial and venous phase imaging with following parameters: repetition time 4900 ms, echo time minimum, a 30×27 cm field of view, image matrix 256×192, flip angle 20°, and section thickness 14 mm. The dose of gadobutrol (Gadovist®; Schering, Berlin, Germany) was 0.2 mL/kg of body weight. The contrast agent injected with a power injector (Spectris MR Injector®; Medrad, Pennsylvania, USA) at a rate of 2 mL/sec. When the contrast was visually detected in the carotid artery by the technologist on axial plane during injection of the contrast, the coronal 3D gradient echo sequence was initiated; and image acquisition time 2-3 minutes. After acquisition of arterial phase of CE-MRA, venous phase images were obtained. For venous phase of CE-MRA, maximum intensity projection (MIP) images were generated using the commercially available 3D-software to evaluate the patency of IJV.

The neck CE-CT was performed using a 64-MDCT scanner (Somatom Sensation 64 VB30, Siemens Medical Solutions, Forchheim, Germany). A total of 100 mL of contrast medium (Optiray 350; Tyco healthcare, Canada) was administered intravenously at a rate of 1.5 mL/sec using a power injector (Stellant, Medrad, Pennsylvania, USA). The scanning parameters



**Fig. 1.** Each parameters were obtained from axial images of neck contrast-enhanced CT (a) Measurements calipers placed at the region of IJV at the level of maximum area of lateral mass of atlas. (b) Measurements calipers placed at the distance between styloid process and lateral mass of atlas at the level of maximum area of lateral mass of atlas. (c) Measuring the cross-sectional 2D area of maximum area of lateral mass of atlas.

were as follows: 750 msec gantry rotation time, 120 kV, 220 mAs, 3 mm slice thickness, and 1.3 cm table feed per rotation.

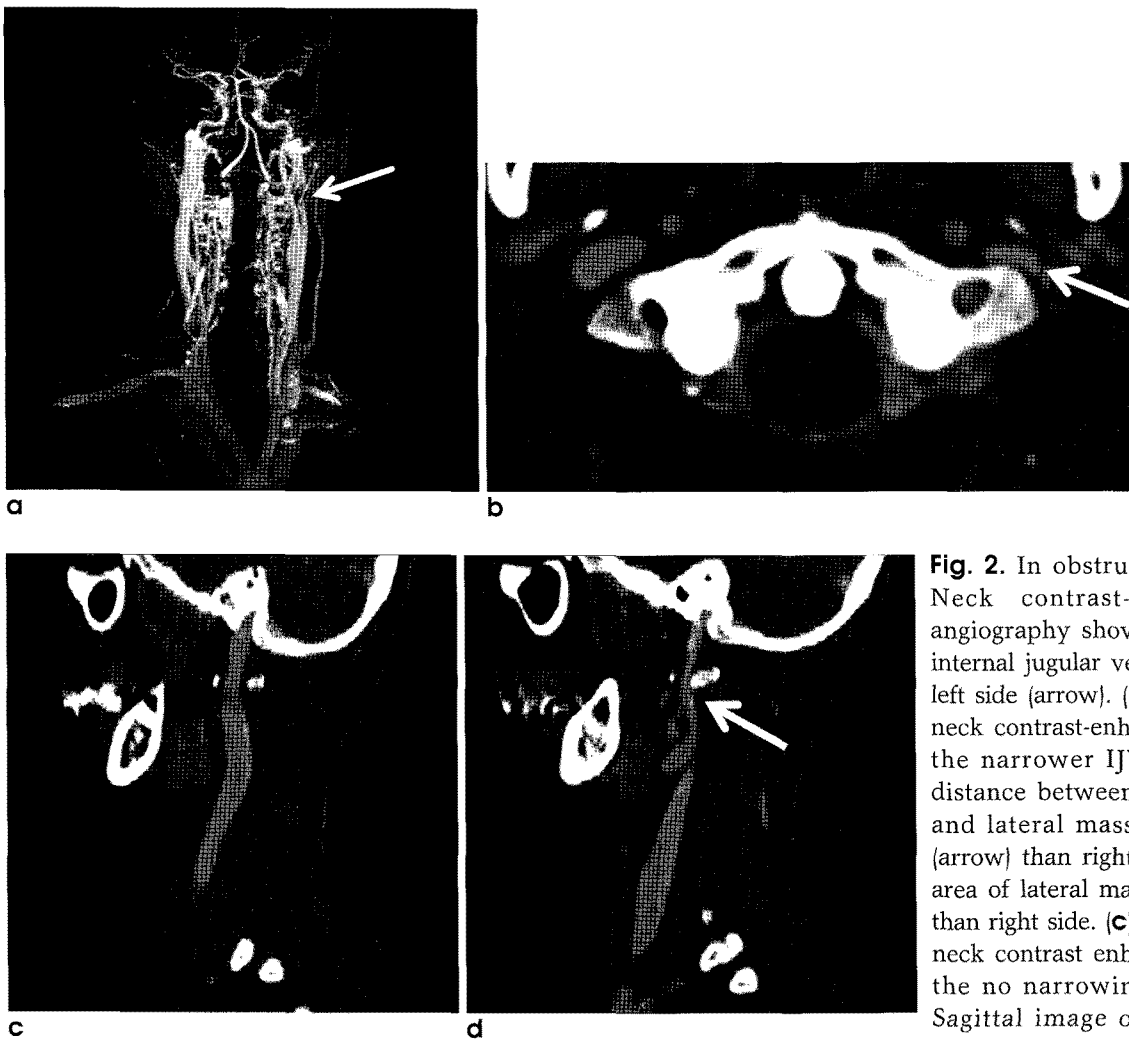
### Image Analysis

The images were independently reviewed by two radiologists in a blinded protocol.

The presence or absence of the IJV obstruction was determined on CE-MRA. We defined obstruction group which had IJV obstruction and control group which had no IJV obstruction on CE-MRA. Following parameters were measured on axial source data of CE-CT, 1) the diameter of IJV at the level of maximum area of lateral mass of the atlas (Fig. 1a); 2) the distance between the styloid process and ipsilateral lateral mass

of the atlas at the level of maximum area of lateral mass of the atlas (Fig. 1b); 3) maximum area of lateral mass of the atlas (Fig. 1c). Each parameter was compared between IJV obstruction side and contralateral normal side in obstruction group, and between IJV obstruction side in obstruction group and mean value of both sides in control group.

All measurements were obtained by manually placing measurements calipers. Millimeter measurements were acquired by using the submillimeter measurement and magnification tools on the PACS workstation (Centricity™ PACS, GE Healthcare, Slough, United Kindom)



**Fig. 2.** In obstruction group, (a) Neck contrast-enhanced MR angiography showing presence of internal jugular vein obstruction at left side (arrow). (b) Axial image of neck contrast-enhanced CT shows the narrower IJV diameter and distance between styloid process and lateral mass of atlas at left (arrow) than right side, and larger area of lateral mass of atlas at left than right side. (c) Sagittal image of neck contrast enhanced CT shows the no narrowing right IJV. (d) Sagittal image of neck contrast enhanced CT shows the narrowing left IJV at the level of between styloid process and lateral mass of atlas (arrow).

**Statistical Methods**

Continuous variables are presented as means ± standard deviations. The statistical significances for measurements data were examined using a Student t-test between the obstruction group and control group. Pearson’s correlation was performed to determine correlation between the narrowest IJV diameter and the narrowest distance from styloid process to lateral mass of atlas, as well as between the narrowest IJV diameter and the maximum area of lateral mass of atlas. All raw data were analyzed by using the SPSS software (version 12.0.1, Statistical Package for the Social Sciences, Chicago, USA).

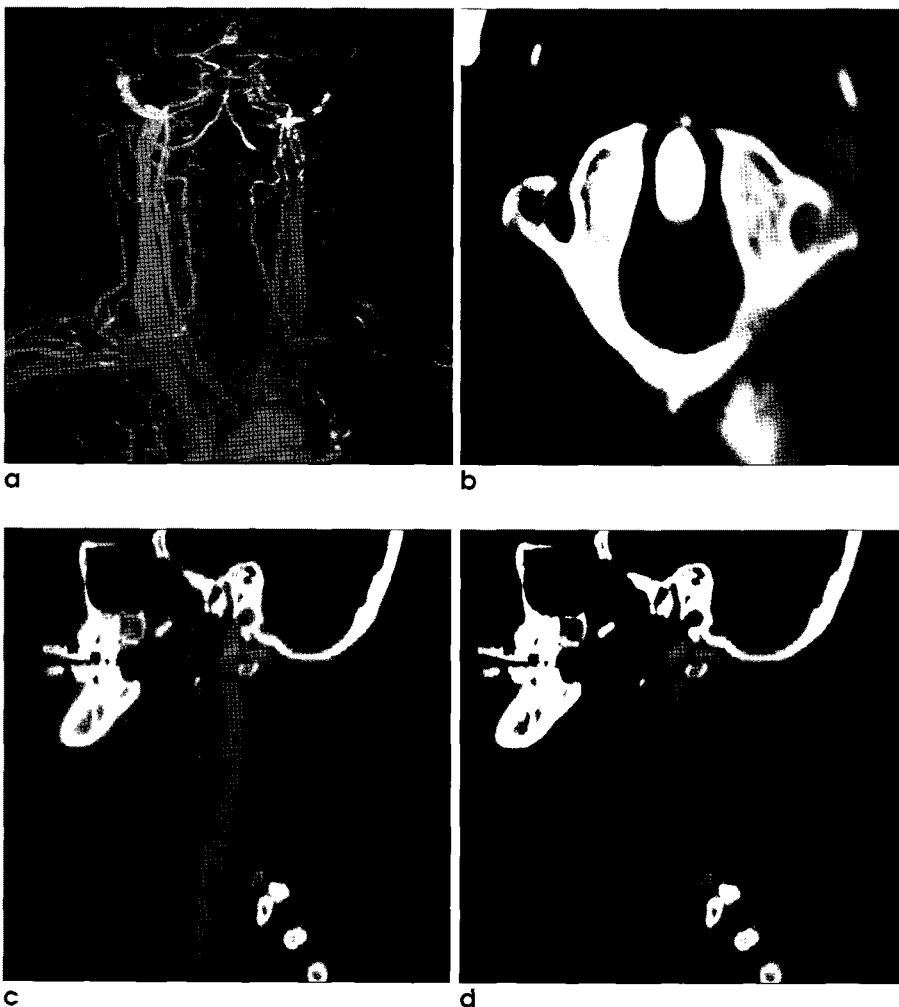
**Results**

The obstruction group who had IJV obstruction on CE-MRA was eleven cases (male 5, female 6) (Fig. 2a-d). Their mean age was 55 years (range, 24-76 years) at the time of examination. The control group who had no IJV obstruction on CE-MRA was nineteen cases (male 4, female 15) (Fig. 3a-d). Their mean age was 60.9 years (range, 33-79 years).

In obstruction group, the diameter of IJV at obstruction side was  $1.6 \pm 1.0$  mm and at contralateral normal side was  $5.1 \pm 2.0$  mm on axial CE-CT images.

**Table 1.** Analysis of the Parameters between IJV Obstruction Side and Contralateral Normal Side in Obstruction Group

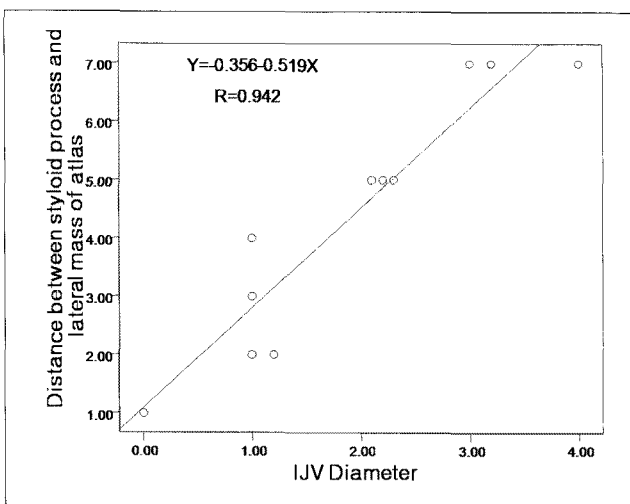
Parameters	Obstruction Side	Normal Side	p Value
IJV diameter	$1.6 \pm 1.0$ mm	$5.1 \pm 2.0$ mm	<0.001
Distance between styloid process and lateral mass of atlas	$4.1 \pm 2.1$ mm	$7.8 \pm 3.0$ mm	<0.01
Maximum area of lateral mass of atlas	$103.4 \pm 25.3$ mm <sup>2</sup>	$79.2 \pm 21.6$ mm <sup>2</sup>	<0.001



**Fig. 3.** In control group, (a) Neck contrast-enhanced MR angiography showing absence of internal jugular vein obstruction. (b) Axial image of neck contrast enhanced CT shows the no narrowing of IJV of both sides. (c, d) Sagittal images of neck contrast enhanced CT show the no narrowing of IJV of both sides (c: right, d: left)

There was significant difference between obstruction side and contralateral normal side with a mean difference of  $3.5 \pm 1.7$  mm ( $p < 0.001$ ). The distance between styloid process and lateral mass of atlas was  $4.1 \pm 2.1$  mm at obstruction side and  $7.8 \pm 3.0$  mm at contralateral normal side on axial CE-CT images with significant difference of  $3.7 \pm 3.2$  mm ( $p < 0.01$ ). Maximum area of lateral mass at obstruction side and contralateral normal side was  $103.4 \pm 25.3$  mm<sup>2</sup> and  $79.2 \pm 21.6$  mm<sup>2</sup>, respectively, which significant difference of  $24.2 \pm 10.5$  mm<sup>2</sup> ( $p < 0.001$ ) (Table 1).

All patients had asymmetry of lateral mass of atlas in obstruction group with significantly larger area at IJV obstruction side than contralateral normal side. The diameter of IJV correlated well with distance between styloid process and lateral mass of atlas ( $R = 0.942$ ,  $p < 0.001$ ) at obstruction side (Fig. 4) in obstruction group. There was no correlation between diameter of IJV and maximum area of lateral mass at obstruction side in obstruction group.



**Fig. 4.** Graph of correlation between IJV diameter and distance between styloid process and lateral mass of atlas at IJV obstruction side in obstruction group. The diameter of IJV correlated well with distance between styloid process and lateral mass of atlas ( $R = 0.942$ ,  $p < 0.001$ ) at obstruction side in obstruction group.

In control group, mean diameter of both IJVs was  $5.9 \pm 1.6$  mm on axial CE-CT and was significantly different from that of obstruction side in obstruction group with a mean difference of  $4.3 \pm 0.5$  mm ( $p < 0.001$ ). The mean distance between styloid process and lateral mass of atlas was  $7.7 \pm 2.7$  mm on axial CE-CT images in control group with significant difference of  $3.6 \pm 0.9$  mm ( $p < 0.001$ ) at obstruction side in obstruction group. The mean maximum area of lateral mass of atlas was  $75.1 \pm 22.4$  mm<sup>2</sup> in control group and was significantly smaller than that of obstruction side in obstruction group with a mean difference of  $28.4 \pm 8.6$  mm<sup>2</sup> ( $p < 0.05$ ) (Table 2). Each parameter was no difference between the both sides in control group.

### Discussion

The use of sitting position during dorsal approach of neurosurgery, turning the head to the side opposite a surgical approach and extending the neck is common practices. During this position, the IJV above the anterior surface of the lateral mass of the atlas on the ipsilateral side of surgical approach cause IJV obstruction (5). Seoane et al. (1) reported compression of the IJV by the lateral mass of the atlas was the cause of cerebellar hemorrhage after supratentorial craniotomy due to neck extension during neurosurgery.

The flow interruption in one IJV at the lateral mass of the atlas with contralateral rotation has been documented angiographically and physiologically in reports dealing with the etiology of tinnitus and cervical venous hum (6, 7). In addition, several studies reported that manual compression of IJV at neutral position resulted in cerebral venous congestion and related to migraine aggravation as well as increasing pressure and volume of the cerebrospinal fluid and especially if it is on the side of the dominant transverse and sigmoid sinuses, may lead to marked increases in intracranial venous pressure (8-10).

**Table 2.** Analysis of the Parameters between IJV Obstruction Side in Obstruction Group and Mean value of Both Sides of Control Group

Parameters	Obstruction Group	Control Group	p Value
IVJ diameter	$1.6 \pm 1.0$ mm	$5.9 \pm 1.6$ mm	$< 0.001$
Distance between styloid process and lateral mass of atlas	$4.1 \pm 2.1$ mm	$7.7 \pm 2.7$ mm	$< 0.001$
Maximum area of lateral mass of atlas	$103.4 \pm 25.3$ mm <sup>2</sup>	$75.1 \pm 22.4$ mm <sup>2</sup>	$< 0.05$

Occasionally, IJV obstruction was seen on venous phase of head and neck CE-MRA. However, the cause of IJV obstruction is not certain. We found that IJV diameter and distance between the styloid process and lateral mass of the atlas at the IJV obstruction side in obstruction group were significantly narrower than those of contralateral normal side in obstruction group and mean value of control group on axial CE-CT. The maximum area of lateral mass of atlas at IJV obstruction side in obstruction group was significantly larger than that of contralateral normal side and control group on axial CE-CT. Consequently, IJV obstruction on venous phase of head and neck CE-MRA result from the narrow space between styloid process and lateral mass of the atlas caused by asymmetry of lateral mass of atlas.

These secondary IJV obstruction caused by asymmetry of lateral mass of the atlas should be distinguish from the primary IJV thrombosis and IJV obstruction by invasion from the head and neck malignancies on head and neck CE-MRA. In five cases of control group, IJVs were not interrupted by the styloid process at the level of maximum area of the lateral mass of the atlas. In these cases, the styloid processes were not reached at the level of lateral mass of the atlas and terminated above the level. In four cases of control group, IJVs were not positioned above the anterior surface of the lateral mass of the atlas and they were passed lateral surface of the lateral mass of the atlas without surrounding bony obstacles.

Our study has some limitations that will be overcome in the future. First, we did not evaluate other factors which can induce the IJV obstruction such as rotation, flexion or extension of neck position and angle or length of the styloid process. Especially, posterior deviation of elongated styloid process may trap the IJV between the styloid process and the lateral mass of the atlas (11, 12). Second, we did not assess the correlation between IJV obstruction and clinical symptom, sign and intracranial pressure. Many patients perform the head and neck CE-MRI and MRA for assessing the cause of neurologic symptoms such as

headache and dizziness. In these cases, there are occasionally no abnormality in brain parenchyma and cerebral vessels. Therefore, the association between IJV obstruction by asymmetry of lateral mass of the atlas and neurologic symptoms should be evaluated because it could be one of the cause of neurologic symptoms.

In conclusion, we found that the cause of high level IJV obstruction on head and neck CE-MRA could be narrow space between the styloid process and lateral mass of the atlas, which was related with asymmetric larger area of lateral mass of the atlas.

## References

1. Seoane E, Rhoton AL Jr. Compression of the internal jugular vein by the transverse process of the atlas as the cause of cerebellar hemorrhage after supratentorial craniotomy. *Surg Neurol* 1999;51:500-505
2. Gabella G. Cardiovascular system. In: Williams P, ed. *Gray's Anatomy*. London: Churchill Livingstone, 1995:1579-1580
3. Tedeschi H, Rhoton AL Jr. Lateral Approaches to the petroclival region. *Surg Neurol* 1994;41:180-216
4. Gooding CA, Stimac GK. Jugular vein obstruction caused by turning of the head. *AJR Am J Roentgenol* 1984;142:403-406
5. Standefer M, Bay JW, Trusso R. The sitting position in neurosurgery: a retrospective analysis of 488 cases. *Neurosurgery* 1984;14:649-658
6. Chandler JR. Diagnosis and cure of venous hum tinnitus. *Laryngoscope* 1983;93:892-895
7. Nehru VI, al-Khaboori MJ, Kishore K. Ligation of the internal jugular vein in hum tinnitus. *J Laryngol Otol* 1993;107:1037-1038
8. Bosnjak R, Kordas M. Circulatory effects of internal jugular vein compression: a computer simulation study. *Med Biol Eng Comput* 2002;40:423-431
9. Doepp F, Schreiber SJ, Dreier JP, Einhaupl KM, Valdueza JM. Migraine aggravation caused by cephalic venous congestion. *Headache* 2003;43:96-98
10. Alperin N, Lee SH, Mazda M, et al. Evidence for the importance of extracranial venous flow in patients with idiopathic intracranial hypertension (IIH). *Acta Neurochir Suppl* 2005;95:129-132
11. Piagkou M, Anagnostopoulou S, Kouladouros K, Piagkos G. Eagle's syndrome: a review of the literature. *Clin Anat* 2009; 22:545-558
12. Ghosh LM, Dubey SP. The syndrome of elongated styloid process. *Auris Nasus Larynx* 1999;26:169-175

## 조영증강 전산화단층촬영술을 이용한 두경부 조영증강 삼차원 자기공명혈관촬영술에서 내경정맥 폐쇄의 원인 평가

연세의대 강남세브란스병원 영상의학과

권혜미 · 정태섭 · 서상현

**목적:** 조영 증강 삼차원 자기공명혈관촬영술에서 관찰되는 내경정맥 폐쇄의 원인을 조영 증강 전산화 단층촬영술을 이용하여 분석하고자 한다.

**대상과 방법:** 2005년부터 2008년까지 두경부 조영증강 자기공명혈관조영술과 조영증강 전산화단층촬영술을 함께 시행한 30명의 환자를 대상으로 하였다. 조영증강 자기공명혈관조영술에서 내경정맥의 폐쇄가 있는 경우 폐쇄군으로 하였고 내경정맥의 폐쇄가 없는 경우 대조군으로 구분하였다. 다음의 지표를 조영증강 전산화단층촬영술에서 분석하였다: 1) 내경정맥의 직경; 2) 경상돌기와 제일경추의 외측돌기와의 거리; 3) 제일경추의 외측돌기의 최대넓이 이후 각각의 지표를 폐쇄군과 대조군에서 비교하였다.

**결과:** 폐쇄군에서 내경정맥의 직경 그리고 경상돌기와 제일경추의 외측돌기와의 거리는 각각  $1.6 \pm 1.0$  mm 그리고  $4.1 \pm 2.1$  mm로 평가되었으며 이는 대조군과 비교하여 유의하게 작게 분석되었다 ( $p < 0.01$ ). 폐쇄군에서 제일경추의 외측돌기의 최대 넓이는  $103.4 \pm 25.3$  mm<sup>2</sup>로 평가되었으며 이는 대조군과 비교하여 유의하게 넓은 것으로 나타났다 ( $p < 0.05$ ).

**결론:** 조영증강 자기공명혈관촬영술에서 보이던 내경정맥 폐쇄의 원인은 제일경추의 비대칭적인 큰 넓이에 의한 것일 수 있다.

통신저자 : 정태섭, (135-720) 서울시 강남구 도곡동 146-92, 강남세브란스병원 영상의학과  
Tel. 82-2-2019-3514 Fax. 82-2-3462-5472 E-mail: tschung@yuhs.ac