

Technical Note

Posterior Cervical Inclinator Foraminotomy for Spondylotic Radiculopathy Preliminary

Jae-Chil Chang, M.D., Ph.D., Hyung-Ki Park, M.D., Ph.D., Soon-Kwan Choi, M.D., Ph.D.

Department of Neurosurgery, College of Medicine, Soonchunhyang University, Seoul, Korea

Posterior cervical foraminotomy is an attractive therapeutic option in selected cases of cervical radiculopathy that maintains cervical range of motion and minimize adjacent-segment degeneration. The focus of this procedure is to preserve as much of the facet as possible with decompression. Posterior cervical inclinator foraminotomy (PCIF) is a new technique developed to offer excellent results by inclinator decompression with minimal facet resection. The highlight of our PCIF technique is the use of inclinator drilling out for preserving more of facet joint. The operative indications are radiculopathy from cervical foraminal stenosis (single or multilevel) with persistent or recurrent root symptoms. The PCIFs were performed between April 2007 and December 2009 on 26 male and 8 female patients with a total of 55 spinal levels. Complete and partial improvement in radiculopathic pain were seen in 26 patients (76%), and 8 patients (24%), respectively, with preserving more of facet joint. We believe that PCIF allows for preserving more of the facet joint and capsule when decompressing cervical foraminal stenosis due to spondylosis. We suggest that our PCIF technique can be an effective alternative surgical approach in the management of cervical spondylotic radiculopathy.

Key Words : Cervical · Posterior · Inclinator · Foraminotomy · Cervical Spondylosis · Radiculopathy.

INTRODUCTION

Cervical spondylotic radiculopathy has been surgically treated either through a posterior or an anterior operative approach. Various anterior and posterior operative approaches for the treatment of cervical diseases have been described. Since the development of posterior cervical disc surgery by Scoville et al.²⁵⁾, several retrospective studies have been published confirming the efficacy of this procedure^{1,12,27)}. Even though the anterior approach has become more popular than the posterior approach, the posterior cervical foraminotomy is an attractive option in selected cases that may maintain cervical range of motion and minimize adjacent-segment degeneration^{5,7,9,27)}. However, the two concerns with posterior foraminotomies are same-level degeneration with kyphosis secondary to partial resection of the facet joint and persistent neck and shoulder pain secondary to muscle stripping with the open procedure⁷⁾. Postoperative degeneration is related to integrity of facet joint. In vitro studies have shown that segmental hypermobility of the cervical spine can result if a foraminotomy involved resection of more than

50% of the facet²⁸⁾. Based on the above, we surmised that if we preserve as much of the facet as possible, we would get a better outcome after posterior cervical foraminotomy.

Therefore, we developed a new technique that offers comparative results by inclinator decompression with minimal facet resection but without bone fusion and immobilization. This surgical technique is accomplished in a manner identical to the conventional posterior cervical foraminotomy. But the differences lie in the use of inclinator drilling out for preserving more of facet joint. We named this technique as posterior cervical inclinator foraminotomy (PCIF). This new surgical technique is reported with illustrations and clinical outcome.

MATERIALS AND METHODS

Preoperative evaluation

Patients were routinely evaluated with anteroposterior, lateral, oblique, and dynamic radiographic views to determine spine alignment, disc space height, foraminal encroachment, and instability. Additional radiographic evaluation included magnetic resonance image(MRI) and computerized tomography (CT) to determine the level of maximal neural compression in patients with multilevel degenerative cervical disc disease.

The radiographic evaluation in conjunction with a thorough clinical history and physical examination determined the operative level involved. Further assessments included diagnostic

• Received : December 16, 2010 • Revised : March 5, 2011

• Accepted : April 19, 2011

• Address for reprints : Hyung-Ki Park, M.D., Ph.D.

Department of Neurosurgery, College of Medicine, Soonchunhyang University, 22 Daesagwan-gil, Yongsan-gu, Seoul 140-743, Korea

Tel : +82-2-709-9268, Fax : +82-2-792-5976

E-mail : phk007@schmc.ac.kr

selective nerve root blocks or electromyography and nerve conduction studies. It is critical to correctly identify the anatomic level to achieve surgical success.

The operative indication for PCIP was radiculopathy from foraminal stenosis (C3-C7; single or multilevel) with persistent or recurrent root symptoms. We excluded cervical disc herniation, and central stenosis.

Surgical technique

The operation is performed after general endotracheal anesthesia. Positioning of the patient is similar to that for the conventional posterior approach to the cervical spine that allows for adequate abdominal relaxation.

A cervical traction device is not used. The entire posterior neck is prepared with antiseptic solution and draped. The operative level is reconfirmed using lateral fluoroscopy while a long K-wire or Steinman pin is held over the lateral side of the patient's neck. A 20mm vertical incision is made approximately 1cm off the midline on the opposite side and the midpoint of the incision is on the upper spinous process of the affected level.

The cervical musculature is then dissected away from the bone, in a careful subperiosteal manner, to expose the lamina-medial facet complex. Monopolar electrocautery is used to avoid excessive bleeding. An anterior cervical discectomy retractor system is

applied with the short blade resting above the spinous process and long blade on the lateral mass of the affected side. At this point, the two adjacent laminae and facet are clearly in view, and the vertebral level is confirmed with fluoroscopy. The resulting trajectory to the facet is a line bisecting the angle formed between the anterior-posterior axis of the spine and angle of lamina (Fig. 1).

Once the facet joint complex of the affected level is exposed, bone removal begins with a high speed drill under magnification through a microscope. This step is performed using a 2 or 3 mm drill bit and micro-curette without Kerrison punch. Drilling away begins from the most latero-inferior portion of the upper lamina and not including lower lamina. Around 3 mm, not exceeding 5 mm, of bone is removed to gain access to the nerve root axilla, and then to the medio-inferior portion of the upper facet, about 3 mm from the lamina-facet border (Fig. 2A). After bone removal from the upper vertebra, the medio-superior articular facet of the lower vertebra is exposed (Fig. 2B). Removal of this portion allows access to the proximal

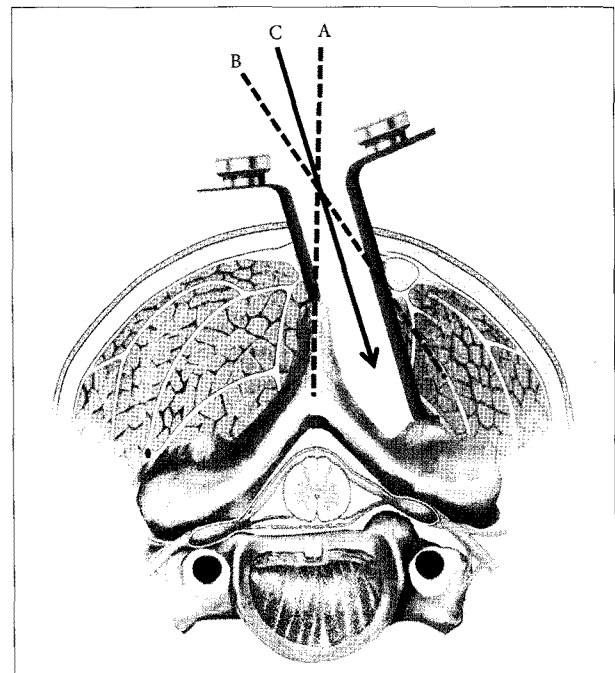


Fig. 1. Anterior cervical retractor system with exposed facet joint. Dotted line (A) is the anterior-posterior axis. Another dotted line (B) is parallel to angle of lamina. Operative trajectory (C) is a line bisecting the angle formed between intersecting lines A and B.

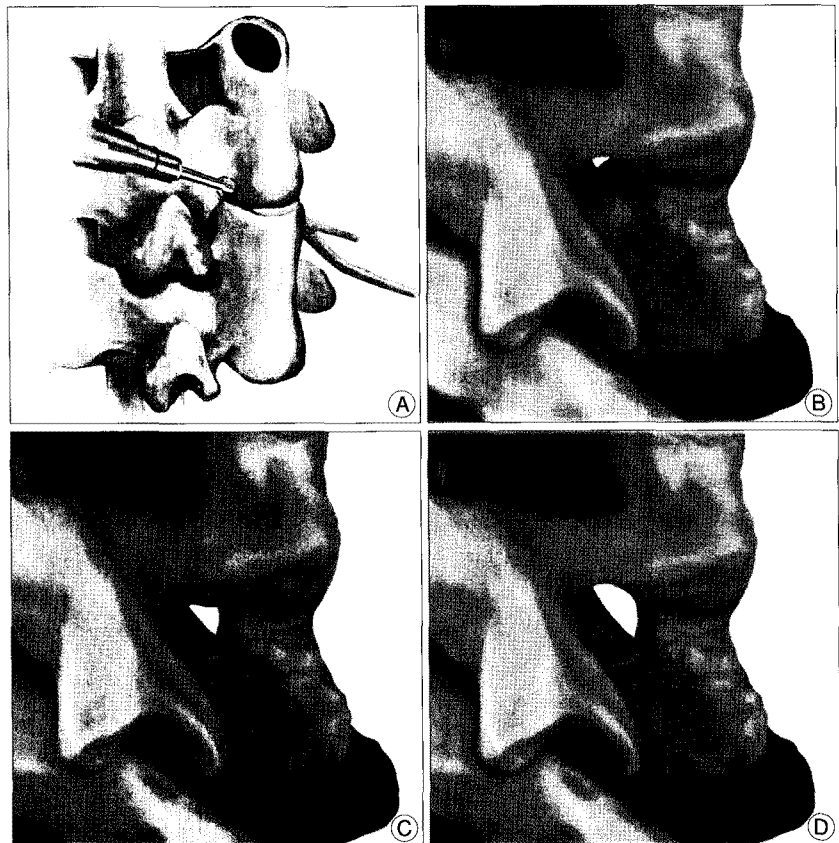


Fig. 2. This illustration shows the sequence of our foraminotomy. A : First, we start drilling at the most latero-inferior portion of upper lamina. B : Medio-superior articular facet of lower vertebra is exposed. C : Removal of this portion allows access to the proximal nerve root. D : unroofing is done dorsally along the nerve root after tilting the patient to the opposite side of the surgeon.

nerve root (Fig. 2C). At this point, tilting the patient to the opposite side of the surgeon provides a superior view of the operative field for dorsal unroofing along the nerve root (Fig. 2D, 3). The decompression is done by removal of the medial portion of the lower facet overlying the nerve root with a 2 mm diamond bit. Diamond bit controls the bleeding from the bone along with frequent saline irrigation. If the sleeve of the nerve root is not opened, any bleeding from the epidural venous plexus is controlled with Gelfoam® and Surgicel®. Drilling is then advanced to the medio-anterior facet along the distal portion of the nerve root dorsally until the freed compressed space is identified by the micro-curette (Fig. 3). A probe can be placed through the foramen without difficulty and gentle manipulation to reveal the loosened nerve root. The wound is closed with subcutaneous suture and Dermabond (Ethicon). After surgery, patients are placed in a soft collar for one week.

Clinical and image studies

Patients were routinely seen for follow-up at 6 weeks, 3 months

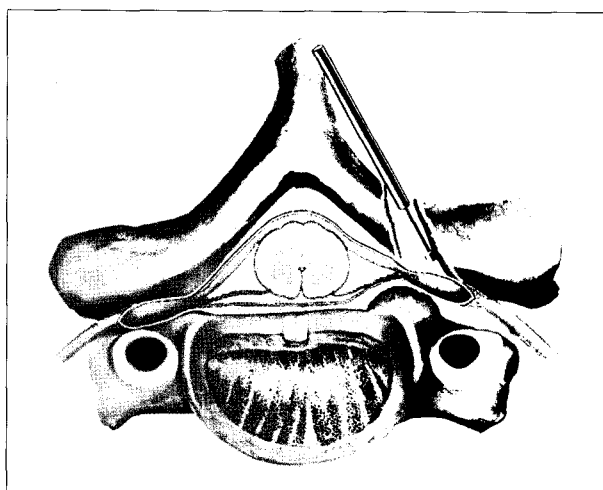


Fig. 3. Drilling is then advanced towards the medio-anterior facet along the distal portion of nerve root dorsally until the free compressed space is identified by the micro-curette.

and then annually. At the time of this study, patients were contacted and symptoms were again assessed using the VAS (visual analogue scale). The results were then compared with their preoperative symptoms.

Preoperative CT and MR images with plain radiographs were obtained in all cases. The most recent neutral and flexion-extension radiographs were used for postoperative changes in focal alignment and disc space. Instability was defined as motion >2 mm at the operative segment or any adjacent segments on dynamic imaging. Focal alignment was defined by the angle that was formed by lines drawn at the superior margin of the superior vertebral body (VB) defining the disc space at the operated level and the inferior margin of the inferior VB on a lateral radiograph obtained with the patient standing¹⁵. Disc-space height was measured from the midpoint of the vertebra below the surgical level to the midpoint of the vertebra above the surgical level on neutral lateral radiographs¹⁵. Focal angle and disc-space were measured three times pre- and postoperatively, with the mean values used for analysis. Statistical analysis was performed using SPSS 14.0 for Windows (SPSS, Inc.).

RESULTS

The PCIF was performed in a patient population whose mean age was 53.6 (range 36-68 years) years. All patients had spondylotic radiculopathy due to foraminal stenosis. Fifteen patients (44%) noted preoperative neck pain (Table 1). There were 26 males and 8 females with 55 levels affected. Twenty-eight operations were performed at the C5/6 levels, 17 at C6/7, eight at C4/5, and two at C3/4 (Table 2). There were two patients with operation on both side of the same level, and nine patients on two levels. Operations were performed between April 2007 and December 2009. The surgery lasted a mean of 37 minutes (range 20-67 minutes) per one lesion and was performed through an incision with a mean length of 2.5 cm (range 2.0-2.8 cm). The mean estimated blood loss was less than 50 mL. The mean duration of hospital stay was 3 days (range 2-8 days). Average follow up was 18 months (range 6-36 months).

Table 1. Presenting Symptoms in 34 patients

Symptom	Preoperative		Postoperative	
	No. of patients (%)	Mean VAS score	No. of patients (%)	Mean VAS score
Radiculopathy	34 (100)	7.3 (5-10)	8 (24)	2.3 (1-4)
Neck pain	15 (44)	3.9 (2-6)	5 (15)	3.1 (2-5)

VAS : visual analogue scale

Table 2. Radiographic alignment and disc height at surgically treated level

Level	No. of Patients (%)	Mean focal angulation (°)		Mean disc space (mm)	
		Preop.	Postop.	Preop.	Postop.
C3-4	2 (4)	2.5 (-3.5-7.4)	2.3 (-3.8-7.1)	4.3 (2.8-5.4)	4.2 (2.7-5.5)
C4-5	8 (14)	3.2 (-2.1-5.6)	3.5 (-3.1-5.4)	3.9 (2.4-4.7)	3.8 (2.3-4.7)
C5-6	28 (51)	4.9 (-1.5-7.8)	4.7 (-1.0-7.1)	4.1 (2.7-5.6)	4.1 (2.8-5.6)
C6-7	17 (31)	3.5 (-2.1-5.6)	3.1 (-3.1-5.4)	4.5 (2.2-5.3)	4.4 (2.0-5.3)

Preop. : preoperative, Postop. : postoperative

Presenting symptoms

Complete improvement in radiculopathic pain was seen in 26 patients (76%). Partial improvement was seen in the remaining 8 patients (24%). Preoperative and postoperative VAS radiculopathy pain scores were 7.3 (5-10), and 2.3 (1-4), respectively. Improvement in neck pain was experienced by 10 (66%) of 15 patients with preoperative neck pain. Five patients (44%) still had mild residual discomfort during the postoperative follow-up periods (Table 1). No postoperative complications developed during the

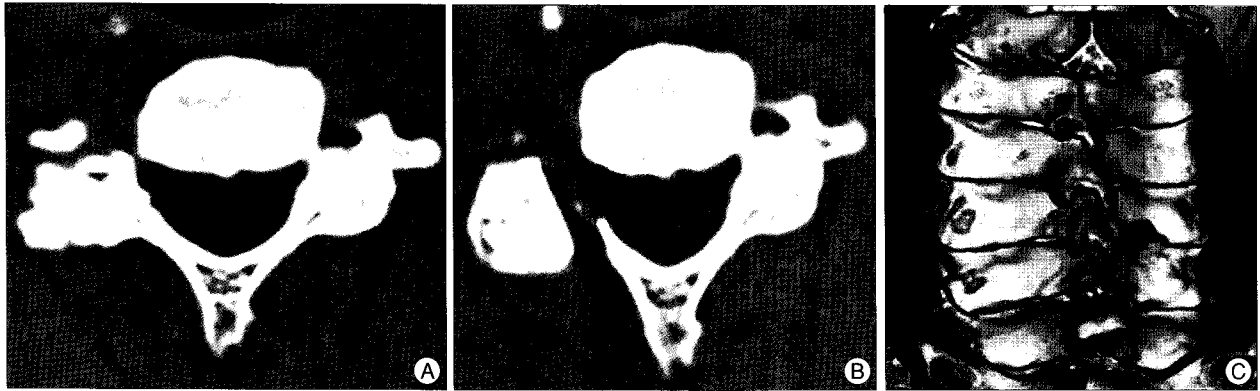


Fig. 4. The preoperative and postoperative computerized tomography (CT). A : Preoperative axial CT shows foraminal stenosis with severe spondylosis in right facet joint. B : Postoperative axial CT shows a widen foramen with preservation of the facet joint after inclinary foraminotomy. C : Postoperative 3-dimensional reconstruction CT shows enough decompression of neural foramen with minimal facetectomy.

study follow up period.

Radiographic alignment and disc height

The mean preoperative and postoperative focal angulations were 3.7° (-3.5 – 7.8), and 3.5° (-3.8 – 7.1), respectively. The mean preoperative and postoperative disc heights were 4.2 mm (2.2–5.6), and 4.0 mm (2.0–5.6), respectively (Table 2). No statistically significant changes in focal angulation or disc-space height were seen at the follow-up period ($p > 0.05$). Preoperative and follow-up images showed no instability even in cases where a bilateral procedure was performed at the same level.

This approach allowed for enough decompression of the neural foramen with less than 30 percent facetectomy compared with conventional procedure that would need about 50 percent facetectomy without injury of facet capsule (Fig. 4).

DISCUSSION

In 1944, Spurling and Scoville²⁶⁾ reported the methods of posterolateral approach for cervical radiculopathy. But since the description of anterior cervical discectomy by Cloward⁶⁾ in 1958, the popularity of the anterior approach has grown as the technique has gradually been made safer and easier to perform^{3,16)}. Although anterior cervical procedures have gained prominence, posterior cervical foraminotomy still provides symptomatic relief in about 90% of patients with radiculopathy from foraminal stenosis at a lower cost than the anterior procedure^{7,27)}. A posterior approach has some advantages compared to an anterior approach, and these include; 1) an ability to avoid damaging of vital structures located in the anterior area of the cervical spine (trachea, esophagus, internal carotid artery, vertebral artery and recurrent laryngeal nerve), 2) an ability to pre-

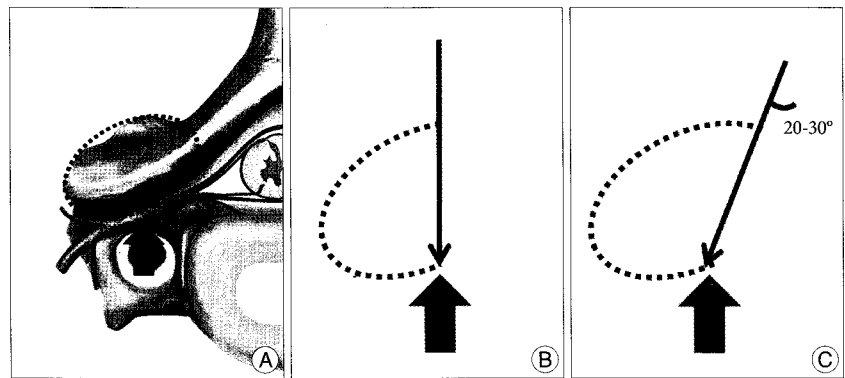


Fig. 5. The simple diagram presents the advantage of our technique. A : The dotted ellipse indicates the outline of facet joint. The arrow indicates the intended point for resecting facet joint. B : The dotted ellipse shows preserved facet joint by conventional posterior foraminotomy technique. C : The dotted ellipse shows preserved facet joint by our inclinary technique. More posterior part of facet joint and capsule can be preserved by our posterior cervical inclinary foraminotomy (PCIF) technique than conventional technique.

vent the structural and biomechanical damage to the remaining vertebral disc by preserving it, 3) without loss of motion segment and 4) reduced occurrence of complications associated with bone graft as well as degenerative changes of the adjacent joint^{7-9,12,14,27)}. Due to the reasons mentioned, posterior decompressive procedures are fundamental tools in the surgical treatment of symptomatic cervical degenerative spine disease^{8,11,12,19,23)}.

However, there are several concerns with posterior foraminotomy; 1) same-level degeneration with kyphosis secondary to partial resection of the facet joint, 2) persistent neck and shoulder pain secondary to muscle stripping with the open procedure^{7,10,13,18)}. Among them, neck pain can be lessened by several minimally invasive techniques^{9,12,23)}. We were not able to find any report regarding efforts to reduce the unavoidable resection of facet joint in decompression procedures.

The cervical facet joints, in contrast with the lumbar facet joints, have a coronal orientation with three-dimensional moving flat-contact surface elements. Zdeblick et al.²⁸⁾ reported that segmental hypermobility of the cervical spine resulted, if a foraminotomy involved resection of more than 50 percent of the facet, but resection of 25 or 50 percent of the facet for forami-

notomy did not appear to lead to acute hypermobility. In fact, if more than 50 percent resection of the facet was needed for adequate decompression, stabilization is required due to segmental hypermobility^{4,20,28}. It would be impractical to always preserve more than 50 percent of the facet joint, especially in unusual cases. These cases include small sized facet and severe foraminal stenosis in need of more resection. For these reasons, a more conservative approach to the amount of facet joint resected is required when performing a posterior foraminotomy.

Postoperative kyphosis is one of the most commonly seen radiographic complications. Jagannathan et al.¹⁵ reviewed a series of 162 cases involving patients with cervical radiculopathy who were treated with a posterior cervical foraminotomy, with a mean follow-up of 77.3 months (range 60-177). Loss of cervical lordosis (defined as segmental Cobb angle $<10^\circ$) was seen in 30 (18.5%) patients. Age over 60 years at the time of surgery and preoperative lordosis of less than 10° have been identified as risk factors for worsening sagittal alignment. In our study, there was no significant difference in pre- and postoperative groups and no progression of kyphosis. However, Jagannathan et al.¹⁵ reported that postoperative deformity and instability developed after 3 years postoperatively. Even though we believe that postoperative focal kyphosis could eventually be decreased with PCIF, additional follow up examinations are required.

Posterior foraminotomy may be associated with a low rate of same- and adjacent-segment disease. Clarke et al.⁵ followed up 303 patients who underwent single-level posterior foraminotomy and demonstrated that the 5- and 10-year risk rates for developing same-segment disease was 3.2 and 5.0%, respectively. The calculated 10-year rate of adjacent-segment disease was 6.7%. Our patients did not display any same- and/or adjacent-segment disease. However, due to the short follow-up study period, we do not know the long term outcome after the PCIF procedure.

Postsurgical neck and shoulder pain have been reported frequently in the literature following laminectomy and laminoplasty. Open posterior approaches to the cervical spine require extensive subperiosteal stripping of the paraspinal musculature. This may lead to postoperative pain, spasm, and dysfunction and can be persistently disabling in 18-60% of patients. Postoperative neck pain and complications have been less of an issue with single-level posterior foraminotomies, which involve less soft tissue dissection. Previous studies reported an incidence of neck pain in to 10-20% following posterior foraminotomy for spondylitic radiculopathy^{5,10}. About 15 percent of our patients complained of neck pain at final follow up. All these patients had previous neck pain, and no patients newly developed after PCIF. We try to reduce postoperative neck pain through meticulous care during soft tissue handling and minimal stripping of soft tissue. Recently, minimally-invasive endoscopic techniques have become more widely used in the surgical subspecialties. Improvements in endoscopic technology have allowed for the surgeon to enter the whole spine including the performance of

posterior cervical foraminotomy^{1,2,8,9,12,20-24}. Another advantage of the PCIF includes its direct three-dimensional screen view with a microscope which is in contrast with the two-dimensional view seen in the endoscopic approach. The PCIF avoids disorientation of the surgeon and overestimation of the actual situation due to magnification. Also, the endoscopic approach requires considerable amount of training and repeated use to master, because endoscopic techniques tend to be unfamiliar procedures for many neurosurgeons^{2,8,21}.

The key point of our PCIF is inclinatory drilling out. The inclinatory angle usually is 20-30 degrees. In cases where half of the facet joint is required to be decompressed, the more posterior aspect of the facet joint and capsule can be preserved by our PCIF technique compared to the conventional technique (Fig. 5). A capsule of facet joint is another matter of great importance to postoperative instability. After posterior foraminotomy, the remaining capsule played a role in the limitation of rotation or flexion²⁸. Therefore, care should be taken to minimize stripping of the facet capsule when the cervical spine is being exposed. Ultimately, our PCIF provided adequate decompression with less than 30 percent resection of the facet dorsal to the nerve root. This minimal facet and capsule resection would reduce the incidence of same level instability and degeneration. Also, this procedure may be indicated in cases with multilevel (greater than two), bilateral pathology, small sized facet and severe foraminal stenosis with a better outcome.

CONCLUSION

We believe that PCIF allows for preserving more of the facet joint and capsule when decompressing cervical foraminal stenosis due to spondylosis. This advantage could lead to a better outcome after posterior cervical foraminotomy. We suggest that our PCIF technique can be an effective alternative surgical approach in the management of cervical spondylotic radiculopathy. Future work should focus on the long-term outcome of this research.

References

1. Adamson TE : The impact of minimally invasive cervical spine surgery. Invited submission from the Joint Section Meeting on Disorders of the Spine and Peripheral Nerves, March 2004. *J Neurosurg Spine* 1 : 43-46, 2004
2. Burke TG, Caputy A : Microendoscopic posterior cervical foraminotomy : a cadaveric model and clinical application for cervical radiculopathy. *Journal of Neurosurgery* 93 : 126-129, 2000
3. Chang JC, Park HK, Bea HG, Cho SJ, Choi SK, Byun PJ : Morphometric measurement of the anatomical landmark in anterior cervical microforaminotomy. *J Korean Neurosurg Soc* 39 : 340-346, 2006
4. Chen BH, Natarajan RN, An HS, Andersson GB : Comparison of biomechanical response to surgical procedures used for cervical radiculopathy : posterior keyhole foraminotomy versus anterior foraminotomy and discectomy versus anterior discectomy with fusion. *J Spinal Disord* 14 : 17-20, 2001
5. Clarke MJ, Ecker RD, Krauss WE, McClelland RL, Dekutoski MB : Same-segment and adjacent-segment disease following posterior cervi-

- cal foraminotomy. *J Neurosurg Spine* 6 : 5-9, 2007
6. Cloward RB : The anterior approach for removal of ruptured cervical disks. *J Neurosurg* 15 : 602-617, 1958
 7. Fehlings MG, Gray RJ : Posterior cervical foraminotomy for the treatment of cervical radiculopathy. *J Neurosurg Spine* 10 : 343-344; author reply 344-346, 2009
 8. Fessler RG, Khoo LT : Minimally invasive cervical microendoscopic foraminotomy : an initial clinical experience. *Neurosurgery* 51 : S37-S45, 2002
 9. Gala VC, O'Toole JE, Voyadzis JM, Fessler RG : Posterior minimally invasive approaches for the cervical spine. *Orthop Clin North Am* 38 : 339-349; abstract v, 2007
 10. Grieve JP, Kitchen ND, Moore AJ, Marsh HT : Results of posterior cervical foraminotomy for treatment of cervical spondylitic radiculopathy. *Br J Neurosurg* 14 : 40-43, 2000
 11. Henderson CM, Hennessy RG, Shuey HM Jr, Shackelford EG : Posterior-lateral foraminotomy as an exclusive operative technique for cervical radiculopathy : a review of 846 consecutively operated cases. *Neurosurgery* 13 : 504-512, 1983
 12. Hilton DL Jr : Minimally invasive tubular access for posterior cervical foraminotomy with three-dimensional microscopic visualization and localization with anterior/posterior imaging. *Spine J* 7 : 154-158, 2007
 13. Hosono N, Yonenobu K, Ono K : Neck and shoulder pain after laminoplasty. A noticeable complication. *Spine (Phila Pa 1976)* 21 : 1969-1973, 1996
 14. Ishihara H, Kanamori M, Kawaguchi Y, Nakamura H, Kimura T : Adjacent segment disease after anterior cervical interbody fusion. *Spine J* 4 : 624-628, 2004
 15. Jagannathan J, Sherman JH, Szabo T, Shaffrey CI, Jane JA : The posterior cervical foraminotomy in the treatment of cervical disc/osteophyte disease : a single-surgeon experience with a minimum of 5 years' clinical and radiographic follow-up. *J Neurosurg Spine* 10 : 347-356, 2009
 16. Krupp W, Schattke H, Mücke R : Clinical results of the foraminotomy as described by Frykholm for the treatment of lateral cervical disc herniation. *Acta Neurochir (Wien)* 107 : 22-29, 1990
 17. O'Toole JE, Eichholz KM, Fessler RG : Minimally Invasive Cervical Foraminotomy and Decompression of Stenosis. in Scuderi GR, Tria AJ, (eds) : *Minimally Invasive Surgery in Orthopedics*. New York : Springer, 2009, pp561-568
 18. Ratliff JK, Cooper PR : Cervical laminoplasty: a critical review. *J Neurosurg* 98 : 230-238, 2003
 19. Raynor RB : Anterior or posterior approach to the cervical spine: an anatomical and radiographic evaluation and comparison. *Neurosurgery* 12 : 7-13, 1983
 20. Raynor RB, Pugh J, Shapiro I : Cervical facetectomy and its effect on spine strength. *J Neurosurg* 63 : 278-282, 1985
 21. Roh SW, Kim DH, Cardoso AC, Fessler RG : Endoscopic foraminotomy using MED system in cadaveric specimens. *Spine* 25 : 260-264, 2000
 22. Roh SW, Rhim SC : Endoscopic Cervical Foraminotomy Using Endoscopic Disectomy (MED) System In Cadaveric Specimens. *J Korean Neurosurg Soc* 28 : 1100-1105, 1999
 23. Ruetten S, Komp M, Merk H, Godolias G : Full-endoscopic cervical posterior foraminotomy for the operation of lateral disc herniations using 5.9-mm endoscopes : a prospective, randomized, controlled study. *Spine* 33 : 940-948, 2008
 24. Saringer WF, Reddy B, Nobauer-Huhmann I, Regatschnig R, Reddy M, Tschabitscher M, et al. : Endoscopic anterior cervical foraminotomy for unilateral radiculopathy : anatomical morphometric analysis and preliminary clinical experience. *J Neurosurg* 98 : 171-180, 2003
 25. Scoville WB, Dohrmann GJ, Corkill G : Late results of cervical disc surgery. *J Neurosurg* 45 : 203-210, 1976
 26. Spurling RG, Scoville WB : Lateral rupture of the cervical intervertebral disc : a common cause of shoulder and arm pain. *Surg Gynecol Obstet* 78 : 350-358, 1944
 27. Tumialán LM, Ponton RP, Gluf WM : Management of unilateral cervical radiculopathy in the military : the cost effectiveness of posterior cervical foraminotomy compared with anterior cervical discectomy and fusion. *Neurosurg Focus* 28 : E17, 2010
 28. Zdeblick TA, Zou D, Warden KE, McCabe R, Kunz D, Vanderby R : Cervical stability after foraminotomy. A biomechanical in vitro analysis. *J Bone Joint Surg Am* 74 : 22-27, 1992