

## Clinical Article

# Technical Considerations to Prevent Postoperative Endocrine Dysfunction after the Fenestration of Suprasellar Arachnoid Cyst

Ki-Young Choi, M.D., Shin Jung, M.D., Ph.D., Sam-Suk Kang, M.D., In-Young Kim, M.D., Ph.D., Tae-Young Jung, M.D., Ph.D., Woo-Yeol Jang, M.D.

Department of Neurosurgery, Chonnam National University Research Institute of Medical Sciences, Chonnam National University Hwasun Hospital and Medical School, Hwasun, Korea

**Objective :** The endocrine dysfunction after the operation for suprasellar arachnoid cysts is not rare. The careful operation to prevent structures can prevent this complication, but it is not enough and effective to prevent it. Authors present technical surgical considerations to prevent this complication with a review of our suprasellar arachnoid cyst patients who had postoperative endocrine dysfunction.

**Methods :** From January 2002 to December 2009, eight patients who had suprasellar arachnoid cysts with visual impairment underwent surgery. The mean age was 57.1 years (range, 33-77). Preoperatively, their endocrine function was clinically normal, and laboratory hormonal levels were within normal ranges. Cyst fenestration was performed by craniotomy (n=6) or by a neuro-endoscopic procedure (n=2), and, simultaneously, along with a cyst wall biopsy.

**Results :** The surgery was uneventful in all eight patients, and there were no neurological morbidities. However, in four patients, endocrine dysfunction occurred postoperatively. We compared these four patients (group A) to the other 4 patients without endocrine dysfunction (group B) with intraoperative findings and with the histopathological findings of the cyst wall biopsy. The group A patients had more abundant vasculature on the cystic wall than the group B patients according to both the intraoperative findings and the histopathological findings.

**Conclusion :** When performing a surgical cyst wall fenestration, surgeons should try to minimize the destruction of the cystic wall vasculature and not to make the fenestration at a site that contains many vascular striae.

**Key Words :** Cyst fenestration · Endocrine dysfunction · Suprasellar arachnoid cyst.

## INTRODUCTION

Arachnoid cysts are congenital lesions which arise from the splitting of the arachnoid membrane (or leptomeninges) during development and make up about 1% of all intracranial mass lesions in adults<sup>10,17,20-22,28</sup>. Because most arachnoid cysts are asymptomatic, these lesions can go undiagnosed until the patients become adults<sup>6,17</sup>. The surgical management for these lesions is not always required if the mass does not cause mass effects or symptoms, regardless of their size and location<sup>3</sup>. Yamauchi et al.<sup>32</sup> reported on the spontaneous disappearance of arachnoid cysts and suggested that surgical indications are controversial for asymptomatic cases.

About 9% of intracranial arachnoid cysts in adults are located in the sellar and suprasellar regions<sup>19</sup>. Lesions with symptoms, such as visual impairment, are rare in adults<sup>17</sup>. After surgical management of the symptomatic lesions, the visual symptoms are usually improved in most cases. However, in some cases, variable postoperative complications can be caused by the operative techniques. Among several complications, the endocrine dysfunction can occur in about 40% of cases that were managed surgically. This complication was reported to be caused by intraoperative injury of hypothalamus, pituitary apparatus and peripituitary vasculature<sup>24</sup>. But cases without significant intraoperative problem often had postoperative endocrine dysfunction. The review for such events has been rare. Herein, we reviewed the intraoperative and histopathologic findings for suprasellar arachnoid cyst patients who underwent fenestration surgery due to visual impairment and with discussion for ways to prevent postoperative endocrine dysfunction after the fenestration of suprasellar arachnoid cyst.

• Received : November 25, 2010 • Revised : March 26, 2011

• Accepted : April 18, 2011

• Address for reprints : Shin Jung, M.D., Ph.D.

Department of Neurosurgery, Chonnam National University Hwasun Hospital and Medical School, 160 Ilim-ri, Hwasun-eup, Hwasun 519-763, Korea

Tel : +82-61-379-7666, Fax : +82-61-379-7673

E-mail : sjung@chonnam.ac.kr

**MATERIALS AND METHODS**

From January 2002 to December 2009, eight patients who suffered from visual impairments were diagnosed with a suprasellar arachnoid cyst. One patient was male and the other 7 were females, and the mean age was 57.1 years (range, 37-77). All patients presented with decreased visual acuity and defects of visual field. On ophthalmologic examination, there were no intraorbital problems. All patients had no endocrine problem preoperatively. Preoperative brain magnetic resonance imaging (MRI) and/or computed tomography (CT) scans showed a cystic lesion on suprasellar region compressing the optic apparatus. The imaging findings included the following : 1) a cystic lesion in the suprasellar region without enhancement in the cavity of the cyst, 2) a low attenuated lesion like that of cerebrospinal fluid on CT, 3) a cystic wall enhancement on MRI, and 4) a cyst which showed low signal intensity on a MRI T1-weighted image (WI) and high signal on a T2-WI (Fig. 1).


All patients underwent simultaneous cyst fenestration and a

cyst wall biopsy. The cyst fenestration was done by a neuroendoscopic procedure through Kocher's point in 2 patients and by an open craniotomy using the subfrontal approach in 6 patients (Table 1).

After the coagulation of the cyst wall, the fenestration and the biopsy were performed with microscissors in order to communicate the cyst contents into the cisternal or ventricular system. A biopsy was performed at the fenestrated cystic wall, and a repeated fenestration to widen the orifice was done in order to prevent adhesion of the cystic wall.

**RESULTS**

In all patients, there were no intraoperative problems such as the injury of nerves and vasculatures and no immediate postoperative neurologic morbidities. The postoperative ophthalmologic examination showed the improvement of visual functions in all patients. However, 4 patients developed postoperative endocrine dysfunctions (Table 1). Among these 4 patients, one

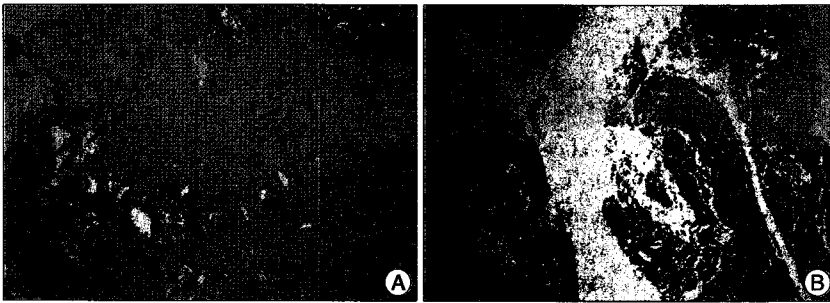


**Fig. 1.** Preoperative radiological images illustrating the cystic lesions of one patient (Case 6). The patient is a 61-year-old female with decreased visual acuity and abnormal visual field. A : On computed tomography (CT), a cystic lesion on suprasellar area is seen. B (sagittal) and C (coronal) on T1WI with enhancement, D (axial) on T2WI : The cystic lesion is detected on brain MRI with enhancement. The suprasellar cystic lesion with enhanced wall compressed optic chiasm. T1WI : T1-weighted image, T2WI : T2-weighted image, MRI : magnetic resonance imaging.

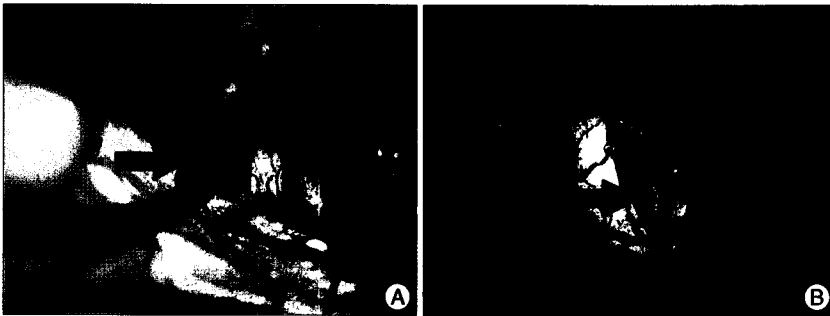
**Table 1.** Clinical summary of the patients with suprasellar arachnoid cyst in this study

Age/Sex	Ophthalmologic exam		Hormonal study <sup>†</sup>		Operation
	Preop.	Postop.	Preop.	Postop.	
37/F	(0.15/0.1)*	Improvement <sup>‡</sup>	W.N.L.	Hypothyroidism, hypogonadism	Craniotomy
66/F	(0.3/0.5)	(0.8/0.7)	W.N.L.	W.N.L.	Craniotomy
43/F	(0.4/0.4)*	(0.9/0.9)	W.N.L.	W.N.L.	Craniotomy
77/F	(0.8/0.08)	(0.9/0.5)	W.N.L.	Panhypopituitarism	Neuro-endoscopy
60/F	(1.0/0.7)*	(1.0/1.0)	W.N.L.	W.N.L.	Craniotomy
61/F	(0.8/0.2)	(1.0/0.5)	W.N.L.	Panhypopituitarism	Craniotomy
62/M	(0.15/0.2)	Improvement <sup>‡</sup>	W.N.L.	W.N.L.	Neuro-endoscopy
51/F	(1.0/1.0)	(1.0/1.0)	W.N.L.	Panhypopituitarism	Craniotomy

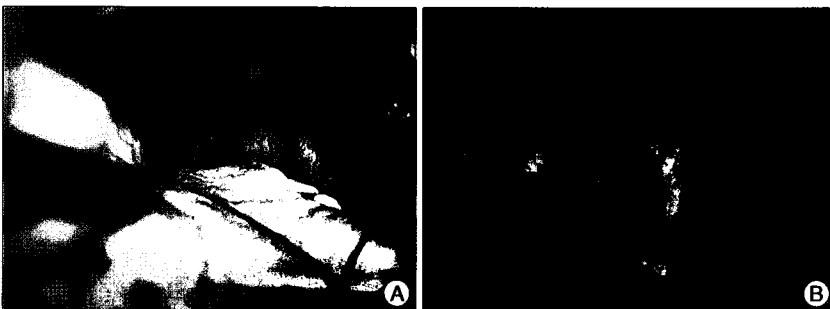
\*The figures about visual fields were lost but made according to the description on the medical records. <sup>‡</sup>Follow up loss but recorded according to the medical records. <sup>†</sup>Preoperative hormone test was basal hormone study except 1 case, which was performed with combined pituitary function test. Postoperative hormone test was combined pituitary function test in all cases. Preop. : preoperative, Postop. : postoperative



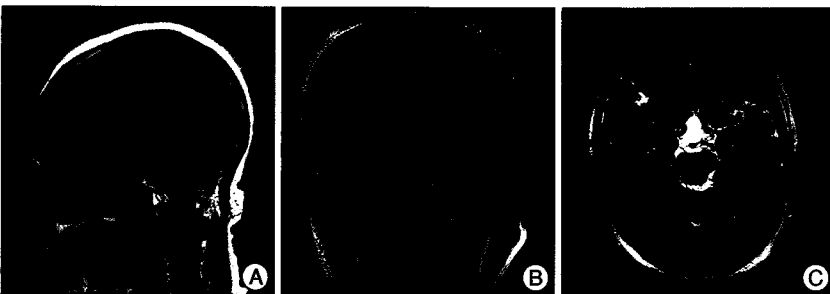**Fig. 2.** Photomicrographs illustrating the histopathological findings of patients. A : The cystic wall component is shown with other tissues, which may be pituitary-related structures, respectively. B : Only the cystic wall component is shown without other tissue which may be pituitary related structures. The figure A is from patient with endocrine dysfunction (group A), and the figure B is from patient without postoperative endocrine dysfunction (group B).



**Fig. 3.** Intraoperative pictures illustrating cysts before fenestration of 2 patients (Two pictures were from each groups). The large arrow on each picture indicates each cystic wall. A : Illustrates a cystic wall with some vasculatures (group A). B : Illustrates a clean cystic wall with no or scanty vasculature (group B).



**Fig. 4.** Intraoperative pictures illustrating cysts after the fenestration (the views for cyst are the same as those in Fig. 3). A : The pituitary structure is not observed and the vasculature on the cystic wall was injured (group A). B : Pituitary structures including the stalk were observed (the large arrow indicates a pituitary stalk) (group B).



**Fig. 5.** Postoperative radiological images were conducted on the same patient as in Fig. 1. The MRI scan shows decreased size of the cyst. A : Sagittal image on T1WI. B : Coronal image on T2WI. C : Axial image on T2WI). MRI : magnetic resonance imaging, T1WI : T1-weighted image, T2WI : T2-weighted image.

patient showed neurological deterioration on 1 week after the surgery. CT and MRI scans were conducted at that time and they showed no abnormal findings which could explain the deteriorated mental state. In addition, basic laboratory findings were within normal ranges. We tentatively managed the patient with intravenous steroid therapy, and, fortunately, the patient recovered in a few days. The patient then underwent a combined pituitary function test and was diagnosed with panhypopituitarism. The other 3 patients with postoperative endocrine dysfunctions had no clinical symptom.

A histopathologic examination of the arachnoid cyst wall was done in all 8 patients. However, the examination did not show only the cystic wall in patients who experienced the postoperative endocrine dysfunction. Rather, the biopsied tissues often contained other tissues such as pituitary structures like a rudiment of the pituitary stalk (Fig. 2). Upon review of the intraoperative finding, there were no visible neural or pituitary structures on the cystic wall at the time of fenestration in all of the patients, but cysts of such cases associated with the postoperative endocrine dysfunction contained many vascular striae on their walls (Fig. 3, 4).

The cysts were decreased in size or stable when examined by imaging (MRI and/or CT) at follow-up (Fig. 5), and the patients' visual symptoms were improved or not aggravated at follow-up (Table 1). The four patients who had endocrine complications postoperatively were managed with hormonal replacement.

**DISCUSSION**

Arachnoid cysts are congenital lesions and mostly asymptomatic, thus, in most cases, the lesions are detected incidentally by a brain CT or go undiagnosed until the patients become adults<sup>17)</sup>. There are a number of general symptoms associated with arachnoid cysts including headache, nausea, vomiting, lethargy,

and/or seizures<sup>4,6,15,22</sup>. Additionally, specific symptoms that can appear include hydrocephalus, delayed development, visual dysfunction, endocrine dysfunction, a low intelligent quotient, and bobble-head doll syndrome etc.

There are no significant differences in the location, histology, and etiology of primary lesions between adults and children<sup>2,14,23,26</sup>. However, about 9% of intracranial arachnoid cysts in adults are located in the sellar and suprasellar region, while the proportion is up to 15% in children<sup>6,10,17,19-21,28</sup>. Symptomatic lesions are relatively rare in adults<sup>14,17</sup>. With respect to surgical procedures, some authors report that a more radical approach is favored in adults, while a cystoperitoneal shunt is favored in children<sup>11,12,14</sup>.

Several controversial hypotheses on the development of symptomatic arachnoid cysts in adults have been reported<sup>2,3,6,8,9,11,12,14,18,25,26,29,32</sup>: 1) valve mechanism and/or an occlusion of the communication between the cyst and the subarachnoid space, 2) splitting of the arachnoid membrane that was caused by trauma, intracranial hemorrhage, or infection, and 3) extension of the membrane of Lilliequist. Williams et al.<sup>31</sup> reported that adults with polycystic kidney disease had a higher incidence of intracranial arachnoid cysts.

Generally, the surgical management of these lesions is not always recommended if the cyst does not cause mass effects or clinical symptoms<sup>1,3,4,13,14,17</sup>. In contrast, for the symptomatic lesions related to their size and location, the surgical management is a possibility, but is controversial<sup>11,4,22,30</sup>. However, the surgery for suprasellar lesions is recommended if the symptoms can be aggravated or if secondary symptoms can occur due to compression of a variety of surrounding structures such as the optic chiasm and/or pituitary structures<sup>10</sup>. Through the surgical management of the cyst, the size of the cyst should be decreased, and consequently, symptoms associated with intracranial hypertension and mass effect by cyst should be improved<sup>7</sup>. However, preoperative endocrine dysfunctions tend to persist even after successful surgical treatment of suprasellar cysts<sup>24</sup>.

Surgical management of suprasellar arachnoid cysts can have several postoperative complications including postoperative intracranial hematomas; cerebrospinal fluid leakage; any surgery related infection; injury of a vessel, nerve, brain parenchyma, or pituitary structure; endocrine or visual dysfunction; cerebral infarction; vasospasms; and complications that are due to general anesthesia. Among several possible postoperative complications, the incidence of endocrine dysfunction was variable and has been reported to be up to 43.2%<sup>24</sup>. Some authors reported a transient postoperative endocrine dysfunction. The transient endocrine complication, which is electrolyte imbalance such as hyponatremia, can resolve in several days. This transient complication can be caused by intraoperative irrigation with normal saline and transient stretch of the hypothalamus by tugging at the cyst during fenestration, without significant structural injury<sup>6,27</sup>. However, a long-lasting postoperative endocrine dysfunction with need of hormone replacement

therapy can occur following intraoperative injury of the pituitary vascular complex, the hypothalamus, and/or the pituitary apparatus<sup>24</sup>. Darach et al.<sup>5</sup> reported that postoperative endocrine dysfunction can occur after successful surgical management without any intraoperative problem in some cases without preoperative endocrine dysfunction. However, the review for this event has not been done and it known be rare.

Upon review of the intraoperative findings, our patients did not have any direct injury of parasellar structures or the brain parenchyma, such as the hypothalamus. However, there were important differences between the 2 groups who were divided based on whether the patient had a postoperative endocrine dysfunction or not.

The group with endocrine dysfunction (group A) had more vascular striae on the cyst fenestration site compared with the group without endocrine dysfunction (Fig. 3). These vascular striae may have been injured at the time of coagulation or during the operation (Fig. 4). Moreover, on the histopathological examination of the cystic wall, some of the group A patients had other tissue which was suspected to be pituitary structures, while group B had only cystic wall components (Fig. 2). In the intraoperative findings, we identified pituitary stalks in all group B patients, but not in group A. We suspect that these vascular striae on the cystic wall were peri-pituitary vascular complexes, severely fanned-out pituitary stalks, and/or stalk-related structures. Injury of peripituitary structures during the fenestration may have been caused by anatomical confusion with the cyst wall and would result in endocrine dysfunctions.

Until now, in order to prevent postoperative endocrine dysfunction, only careful manipulation of the structures around the cysts has been emphasized. However, after review of our patients and the literature, we suggest the following additional important surgical considerations in order to prevent postoperative endocrine dysfunction after suprasellar arachnoid cyst fenestration surgery. First, careful observation of the configuration of the cyst wall must be performed. Sellar and suprasellar cysts may be fanned-out pituitary-related structures or vascular structures such as the hypophyseal plexus. When the cyst fenestration is performed, the fenestrated site must avoid abundant vascular structures or striae patterns on the cyst wall.

## CONCLUSION

In our experience, the surgical management for suprasellar arachnoid cyst presenting visual impairment is essential for the improvement of symptom. However, postoperative endocrine dysfunction can occur on half of patients even without any injury to surrounding structures. We believe that the vasculature of the suprasellar arachnoid cyst wall may contain peripituitary plexuses or fanned-out pituitary stalks. Therefore, surgeons should try to minimize the destruction of the cystic wall vasculature and not to make the fenestration at a site that contains many vascular striae to prevent postoperative endocrine dys-

function, when performing the fenestrations of cyst wall.

### Acknowledgements

This study was financially supported by Chonnam National University, 2004.

### References

- Al-Holou WN, Yew AY, Boomsaad ZE, Garton HJ, Muraszko KM, Maher CO : Prevalence and natural history of arachnoid cysts in children. *J Neurosurg Pediatr* 5 : 578-585, 2010
- Caruso R, Salvati M, Cervoni L : Primary intracranial arachnoid cyst in the elderly. *Neurosurg Rev* 17 : 195-198, 1994
- Choi JU, Kim DS : Pathogenesis of arachnoid cyst : congenital or traumatic? *Pediatr Neurosurg* 29 : 260-266, 1998
- Circillo SF, Cogen PH, Harsh GR, Edwards MS : Intracranial arachnoid cysts in children. A comparison of the effects of fenestration and shunting. *J Neurosurg* 74 : 230-235, 1991
- Crimmins DW, Pierre-kahn A, Sainte-Rose C, Zerah M : Treatment of suprasellar cysts and patient outcome. *J Neurosurg* 105 : 107-114, 2006
- Dagain A, Lepeintre JF, Scarone P, Costache C, Dupuy M, Gaillard S : Endoscopic removal of a suprasellar arachnoid cyst : an anatomical study with special reference to skull base. *Surg Radiol Anat* 32 : 389-392, 2010
- De Bonis P, Novegno F, Tamburrini G, Anile C, Pompucci A, Mangiola A : Teaching Neuroimage : prepontine-suprasellar arachnoid cyst presenting with sign of normal Pressure hydrocephalus. *Neurology* 70 : e26, 2008
- Dyck P, Gruskin P : Supratentorial arachnoid cysts in Adults. A discussion of two cases from a pathophysiologic and surgical perspective. *Arch Neurol* 34 : 276-279, 1977
- Fox JL, Al-Mefty O : Suprasellar arachnoid cysts : an extension of the membrane of Lilliequist. *Neurosurgery* 7 : 615-618, 1980
- Fujimura J, Shima Y, Arai H, Ogawa R, Fukunaga Y : Management of a suprasellar arachnoid cyst identified using prenatal sonography. *J Clin Ultrasound* 34 : 92-94, 2006
- Garcia-Bach M, Isamat F, Vila F : Intracranial arachnoid cysts in adults. *Acta Neurochir Suppl (Wien)* 42 : 205-209, 1988
- Gosalakkal JA : Intracranial arachnoid cysts in children : a review of pathogenesis, clinical features, and management. *Pediatr Neurol* 26 : 93-98, 2002
- Guzel A, Trippel M, Ostertage CB : Suprasellar arachnoid cyst : a 20-year follow-up after stereotactic internal drainage : case report and review of the literature. *Turk Neurosurg* 17 : 211-218, 2007
- Harsh GR 4th, Edwards MS, Wilson CB : Intracranial arachnoid cysts in children. *J Neurosurg* 64 : 835-842, 1986
- Hoffman HJ, Hendrick EB, Humphreys RP, Armstrong EA : Investigation and management of suprasellar arachnoid cysts. *J Neurosurg* 57 : 597-602, 1982
- Isik U, Ozek MM : Endoscopic treatment in utero diagnosed suprasellar arachnoid cyst and development of salt wasting. *Minim Invasive Neurosurg* 50 : 243-246, 2007
- Kandogan T, Olgun L, Gultekin G, Aydar L, Sezgin O : A suprasellar arachnoid cyst destructing the sphenoid sinus : an unusual cause of headache in an elderly female. *Swiss Med Wkly* 134 : 28-29, 2004
- Lodrine S, Lasio G, Fornari M, Miglivacca F : Treatment of supratentorial primary arachnoid cysts. *Acta Neurochir (Wien)* 76 : 105-110, 1985
- Monsalve G, Luque JC : Giant suprasellar arachnoid cyst. A case with severe brain stem compression : an incidental finding in a head trauma. *Pediatr Neurosurg* 43 : 174-176, 2007
- Murali R, Epstein F : Diagnosis and treatment of suprasellar arachnoid cyst. Report of three cases. *J Neurosurg* 50 : 515-518, 1979
- Muthusubramanian V, Pande A, Vasudevan MC, Ravi R : Suprasellar arachnoid cyst with bobble-head doll movements : a management option. *J Pediatr Neurosci* 1 : 24-26, 2006
- Ozek MM, Pamir MN, Erzen C : A combined surgical approach to a suprasellar arachnoid cyst with precocious puberty. *Turk Neurosurg* 2 : 187-189, 1992
- Passero S, Filosomi G, Cioni R, Venturi C, Volpini B : Arachnoid cysts of the middle cranial fossa : a clinical, radiological and follow-up study. *Acta Neurol Scand* 82 : 94-100, 1990
- Pierre-kahn A, Capelle L, Brauner R, Sainte-Rose C, Renier D, Rappaport R, et al. : Presentation and management of suprasellar arachnoid cysts. Review of 20 cases. *J Neurosurg* 73 : 355-359, 1990
- Rappaport ZH : Suprasellar arachnoid cysts : options in operative management. *Acta Neurochir (Wien)* 122 : 71-75, 1993
- Rengachary SS, Watanabe I, Brackett CE : Pathogenesis of intracranial arachnoid cysts. *Surg Neurol* 9 : 139-144, 1978
- Sood S, Schuhmann MU, Cakan N, Ham SD : Endoscopic fenestration and coagulation shrinkage of suprasellar arachnoid cysts. *J Neurosurg* 102 : 127-133, 2005
- Thompson TP, Lunsford LD, Kondziolka D : Successful management of sellar and suprasellar arachnoid cysts with stereotactic intracavitary irradiation : an expanded report of four cases. *Neurosurgery* 46 : 1518-1522; discussion 1522-1523, 2000
- Tsuda T, Ueda S, Matsumoto K : [Clinicopathological study of the arachnoid cyst.] *Neurol Med Chir (Tokyo)* 21 : 501-509, 1981
- Wester K, Gilhus NE, Hugdahl K, Larsen JL : Spontaneous disappearance of an arachnoid cyst in the middle intracranial fossa. *Neurology* 41 : 1524-1526, 1991
- Williams SM, Dean AM : A new lump. *Br J Radiol* 75 : 489-490, 2002
- Yamauchi T, Saeki N, Yamaura A : Spontaneous disappearance of temporo-frontal arachnoid cyst in a child. *Acta Neurochir (Wien)* 141 : 537-540, 1999