

Case Report

Sparganosis in the Lumbar Spine : Report of Two Cases and Review of the Literature

Jin Hoon Park, M.D.,¹ Young Soo Park, M.D.,² Jong Sung Kim, M.D.,³ Sung Woo Roh, M.D., Ph.D.¹

Departments of Neurosurgery,¹ Pathology,² Neurology,³ Asan Medical Center, College of Medicine, University of Ulsan, Seoul, Korea

Sparganosis is a rare parasitic infection affecting various organs, including the central nervous system, especially the lumbar epidural space. This report describes the identification of disease and different strategies of treatments with preoperative information. A 42-year-old man presented with a 2-year history of urinary incontinence and impotence. He had a history of ingesting raw frogs 40 years ago. Magnetic resonance (MR) imaging showed an intramedullary nodular mass at conus medullaris and severe inflammation in the cauda equina. A 51-year-old woman was admitted with acute pain in the left inguinal area. We observed a lesion which seemed to be a tumor of the lumbar epidural space on MR imaging. She also had a history of ingesting inadequately cooked snakes 10 years ago. In the first patient, mass removal was attempted through laminectomy and parasite infection was identified during intra-operative frozen biopsy. Total removal could not be performed because of severe arachnoiditis and adhesion. We therefore decided to terminate the operation and final histology confirmed dead sparganum infection. We also concluded further surgical trial for total removal of the dead worm and inflammatory granulation totally. However, after seeing another physician at different hospital, he was operated again which resulted in worsening of pain and neurological deficit. In the second patient, we totally removed dorsal epidural mass. Final histology and enzyme-linked immunosorbent assay (ELISA) confirmed living sparganum infection and her pain disappeared. Although the treatment of choice is surgical resection of living sparganum with inflammation, the attempt to remove dead worm and adhesive granulation tissue may cause unwanted complications to the patients. Therefore, the result of preoperative ELISA, as well as the information from image and history, must be considered as important factors to decide whether a surgery is necessary or not.

Key Words : Sparganosis · Sparganosis in the lumbar vertebrae · Enzyme-linked immunosorbent assay.

INTRODUCTION

Sparganosis is a rare parasitic infection caused by migrating tapeworm larvae of the genus *Spirometra*, whose first intermediate host is cyclops and second intermediate hosts are freshwater fish, amphibians and reptiles^{4,6}. The definitive hosts are cats, dogs and other wild carnivores⁶. Human infection aberrantly occurs by : 1) drinking untreated water containing larvae or first intermediate hosts, 2) ingesting raw or inadequately cooked flesh of infected snakes or frogs 3) applying the flesh of an infected intermediate host as a poultice to a wound.

Sparganosis usually appears as slowly growing and migratory subcutaneous nodules. This parasite can be found anywhere in the body including central nervous system^{2,9}. However, central nervous system, especially intraspinal, involvement is extremely rare, with only nine cases reported previously^{1,4-6,8,9,11}. We here

describe two patients with spinal sparganosis verified by microsurgical excision. The diagnosis, treatment, and outcome of patients with spinal sparganosis are discussed.

CASE REPORT

Case 1

A 42-year-old man presented with a 2-year history of progressive perianal paresthesia and pain, prominent on defecation. On admission, constipation was so severe that he could not defecate without intermittent self-administered enema. He also complained urinary incontinence and erection failure. The motor power of all extremities was normal, but muscle atrophy was detected in both legs. He also showed decreased Achilles tendon reflexes and anal tone. There were no skin nodules or organomegaly. Blood analysis showed that neutrophils and eosinophils were in the normal ranges. He had a history of ingesting inadequately cooked frogs and snakes 40 years before the onset of perianal paresthesia.

Magnetic resonance (MR) imaging showed multiple nodular mass-like lesions from the conus medullaris to the lower end of the thecal sac, and adhesion of the cauda equine (Fig. 1).

• Received : June 25, 2010 • Revised : August 13, 2010
 • Accepted : March 27, 2011
 • Address for reprints : Sung Woo Roh, M.D., Ph.D.
 Department of Neurosurgery, Asan Medical Center, 86 Asanbyeongwon-gil,
 Songpa-gu, Seoul 138-736, Korea
 Tel : +82-2-3010-3550, Fax : +82-2-476-6738
 E-mail : swroh@amc.seoul.kr

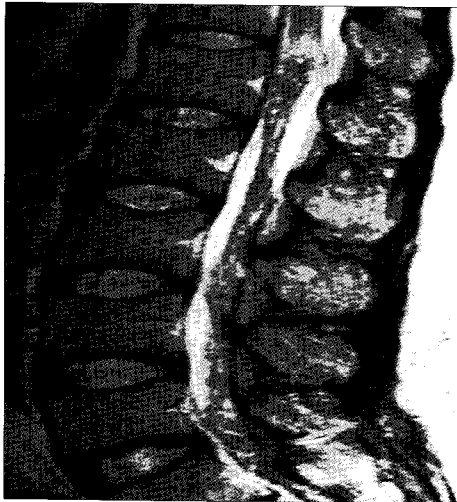

Fig. 1. The preoperative MRI of case 1. T2-weighted magnetic resonance (MR) image shows a nodular-shaped mass (15×10 mm) in the conus medullaris and severe inflammation and adhesion of the cauda equina.

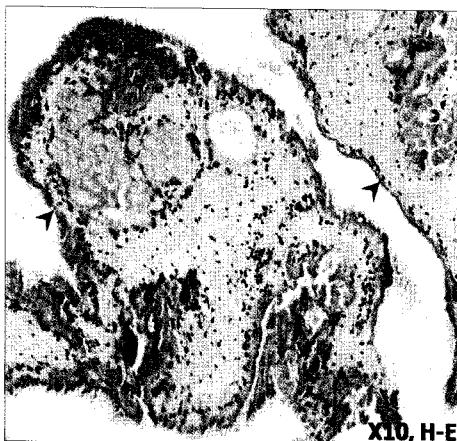


Fig. 2. The histologic finding of case 1. Low powered view shows parasite impaction (arrow) in fibroadipose tissue with granulation tissue. The body of the parasite has been degenerated and calcareous bodies are not readily discerned, but the outer layer of tegument is preserved. These findings indicate a dead worm.

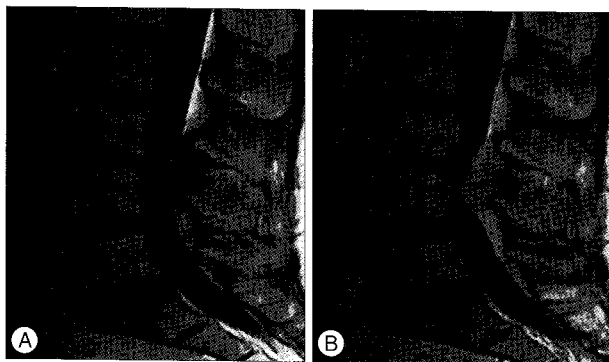


Fig. 3. The preoperative MRI of case 2. A : T1-weighted magnetic resonance (MR) image shows an elongated high- or iso-intensity signal mass compressing the thecal sac at the L3-4 dorsal side. B : MRI with gadolinium enhancement shows that a highly enhanced dorsal side mass is compressing thecal sac and this mass seems to be in the epidural space.

With a goal of acquiring a tissue for histological confirmation, surgery was attempted through L3 total laminectomy. Extradural adhesion and abnormality were absent. However, severe arachnoiditis and adhesion of cauda equina with multiple granulation tissues were noted after opening dura. A yellowish granulation tissue was sent for frozen biopsy, which confirmed parasite infection. Further removal was thought to be very risky because of severe adhesion, thus we decided to terminate the operation. Although we initiated steroid treatment after surgery, expecting a reduction in inflammatory arachnoiditis, it proved to be ineffective. After surgery, we requested enzyme-linked immunosorbent assay (ELISA) with his blood and cerebrospinal fluid (CSF) obtained during operation and the test showed a positive response to a sparganum antibody.

In a high power microscopic view of the parasite, the body of the parasite has been degenerated and calcareous bodies are not readily discerned, but the outer layer of tegument was preserved (Fig. 2). We concluded that these findings supported the evidence of the dead worm and decided to stop further surgical treatments. His perianal pain was aggravated after our surgery that seemed to be caused by irritation of cauda equina.

After visiting another hospital, he underwent a second operation at a different hospital. Although we thought that the second surgery would be ineffective in relieving his pain and neurological deficit, another surgeon seemed to have a different opinion. His pain and neurological function were aggravated after the second surgery. At present, he utilizes regular catheterization and enemas to void and defecate.

Case 2

A 51-year-old woman was admitted with a 1-month history of severe back and left inguinal pain [numeric rating scale (NRS) 9] after a minor trauma. Her neurological examination and blood profile were completely normal. She ate inadequately cooked snakes 10 years ago.

MR imaging showed an elongated and well-enhanced epidural mass at the L3-4 level compressing the dorsal aspect of the thecal sac. The combination of T1-, T2- and enhanced T1-weighted MR imaging findings suggested a vascular originating tumor, such as a vascular malformation, rather than sparganosis (Fig. 3). During operation, we identified a fibrous grayish elongated mass (40×10 mm). The adhesion between mass and dura was so minimal that it was easily detached from the dura. During the operation, we thought the mass might be a tumor, such as a lipoma, and were unaware that it could be a parasite infection, which had been rare even in endemic areas (Fig. 4). Final histology was confirmed as sparganosis. In high power microscopic view of the parasite, tegument covered the outer layer and many calcareous bodies were seen inside the body of the parasite. Fragmented smooth muscles were also observed (Fig. 5). After confirmation of histology, we requested ELISA with her blood and it showed the same conclusion. Removal of the mass led to dramatic pain relief immediately after surgery (NRS 2).

DISCUSSION

Sparganosis is an uncommon disease in humans. It is caused by larvae of the tapeworm genus *Spirometra*, whose definitive hosts are domestic and wild cats and dogs^{1,6,11}. The disease usually involves the subcutaneous tissue or muscle of the chest, abdominal wall, or limbs. Central nervous system involvement is relatively rare, with infection of the spinal system being extremely rare^{2,3}. To date, only nine cases have been reported; in all but one patient, the worm was surgically removed and identified^{1,9}.

Sparganosis occurs more frequently in eastern Asia than in other areas of the world. In this region, human infection develops accidentally by drinking water contaminated with infected copepods, ingesting raw or inadequately cooked snakes or frogs infected with the sparganum, or by applying the flesh of an infected intermediate host as a poultice to the eye or an open wound^{4,9}.

The first male patient had a history of ingestion of inadequately cooked snakes and frogs 40 years ago and had 2 year-history of clinical manifestation. The second female patient ate inadequately cooked snakes 10 years ago, but her symptoms emerged 7 days after a recent trauma.

Considering the ingestion history and life span of sparganum in humans; 5-20 years, we concluded that the worm found in the woman was more likely to be alive and histological findings also supported such a possibility. Her acute manifestation of pain seemed to be related with a inflammatory immune reaction. In contrast, the male patient ate inadequately cooked snakes and frogs 40 years ago, which implies much longer duration than the mean life span of sparganum. In addition, histological confirmation of the dead worm led us to conclude that further surgical attempts for total removal would be ineffective for him². After visiting another hospital, however, he underwent the second operation at that hospital, which resulted in aggravation of neurological deficit and pain. We presumed that it might have been further attempted to reduce severe adhesion between cauda equina and granulation tissue which only caused further worsening of pain and neurologic deficits.

Preoperative diagnosis of cerebral sparganosis mansoni, based on clinical and radiological findings, is difficult⁸. Preoperative diagnosis is rare in human sparganosis, because the condition is very uncommon even in endemic areas. Diagnosis has usually been made after surgical removal of worms^{2,4,8,10,12}. The presence of anti-sparganum antibody in CSF or serum, measured by ELISA, is highly sensitive and specific in the diagnosis of sparganosis^{4,7,9}. However, because it is difficult to suspect this parasitic disease based on clinical and imaging findings, the value of ELISA in preoperative diagnosis is limited.

In the female patient described here, we attempted surgical resection with preoperative wrong diagnosis, and without a preoperative ELISA test. The goals of our surgery were to remove the offending lesion and to confirm a correct diagnosis. Fortunately, the worm was located in the epidural space only without severe inflammation, and thus detachment from the dura

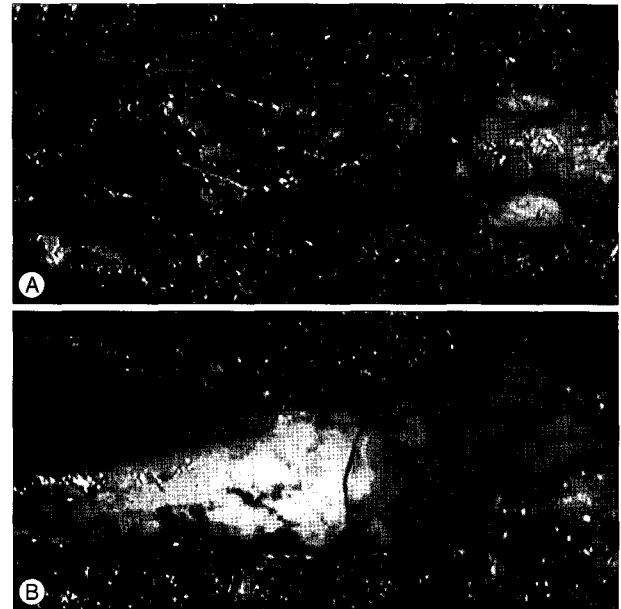


Fig. 4. Operative image of case 2. A : After laminectomy at L3 and L4, an elongated and dark reddish granulation tissue with sparganum is seen. B : Adhesion of the granulation tissue and dura was not so severe that it could be easily detached.

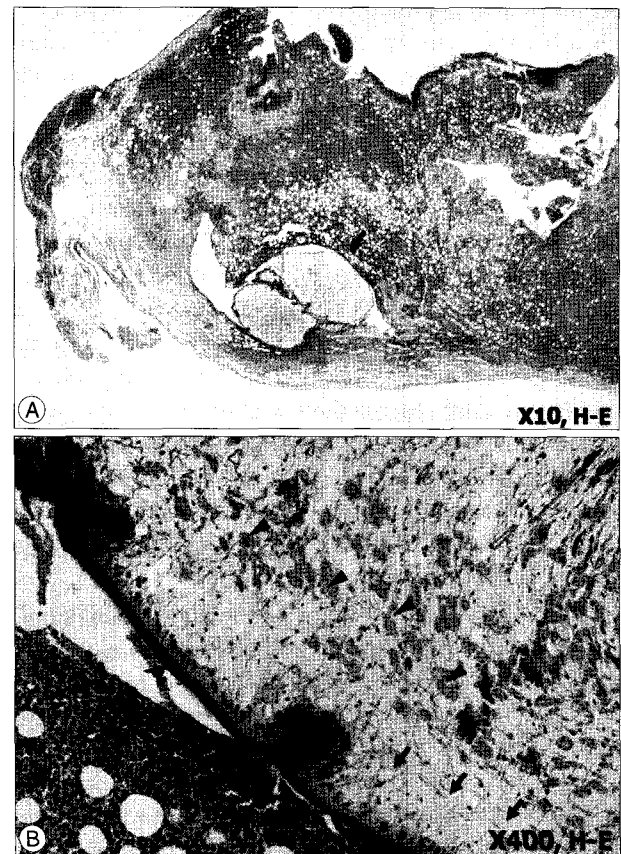


Fig. 5. The histologic finding of case 2. A : Low powered view shows parasite impaction (arrow) in fibroadipose tissue with granulation tissue. B : In the high powered microscopic view of the parasite, Tegument (arrowhead) covers the outer layer and many calcareous bodies (arrows) are seen inside the body of the parasite. Fragmented smooth muscles (triangles) are also observed.

was easily performed. For this reason, total mass removal was easily done and the outcome was excellent without correct preoperative diagnosis. In the male patient, we also did not suspect parasite infection and tried to get a tissue for histological diagnosis. Preoperative image indicated that total removal of mass would be very difficult but we were only able to obtain a small quantity of granulation tissue, because of severe arachnoiditis and adhesion. If we had suspected parasite infection and done ELISA test preoperatively, we would have avoided such an inefficient intradural surgery for biopsy, considering surgical risk, life span of sparganum and the ingesting history of raw foods. His poor neurological function did not improve and became worse than his preoperative state. His poor outcome seems to be resulted from the severe adhesion between cauda equina and granulation tissue, the long duration of his urinary and defecation problem, and the irritation of adhesive cauda equina induced by surgery. The granulation tissue of sparganum is reported to regress slowly after death of worm²⁾. If preoperative correct diagnosis had been made with ELISA, conservative management on this male patient would have been a better choice.

Considering our two cases, we conclude that preoperative ELISA can be helpful for correct diagnosis and treatment of the indistinct spinal mass, especially in endemic areas. In addition, though surgical removal of worm and inflammatory granulation usually has a good prognosis, the attempt to remove the dead worm and adhesive granulation tissue may be the worst option to the patient like our case. With a single imaging study, it is difficult to determine whether the worm is alive^{1,2)}. However, the differences of preoperative MRI between our two cases could give useful presumptive information, which may indicate whether the worm is alive and that the patient is a surgical candidate. If highly enhanced and well localized compressive lesion like case 2 it indicates that the worm is alive and that the patient is a surgical candidate. In contrast, only inflammation without localization which suggests chronic inflammation like case 1 it is an indication that the worm is dead and that the patient is a poor surgical candidate.

As chemotherapy was employed in only 1 of the 10 patients described to date and was not shown to be effective, we did not prescribe any medical treatment to our patients¹⁾.

CONCLUSION

Although extremely rare, lumbar epidural/subdural sparganosis should be considered in the differential diagnosis of lumbar spinal lesions and preoperative ELISA can be helpful, especially in endemic areas. Although the treatment of choice is surgical resection of living worm with inflammation, the attempt to remove the intradural dead worm and adhesive granulation tissue may be detrimental to the patient. Therefore, the result of ELISA as well as the information from image and history, such as the location of lesion (intradural or extradural), the existence of adhesion and inflammation, the interval after ingestion of raw food, the life span of worm, must be considered as important factors to decide whether a surgery is necessary or not.

References

1. Bao XY, Ding XH, Lu YC : Sparganosis presenting as radiculalgia at the conus medullaris. *Clin Neurol Neurosurg* 110 : 843-846, 2008
2. Chang KH, Han MH : MRI of CNS parasitic diseases. *J Magn Reson Imaging* 8 : 297-307, 1998
3. Cho SY, Bae JH, Seo BS : Some aspects of human sparganosis In Korea. *Kisaengchunghak Chapchi* 13 : 60-77, 1975
4. Cho YD, Huh JD, Hwang YS, Kim HK : Sparganosis in the spinal canal with partial block : an uncommon infection. *Neuroradiology* 34 : 241-244, 1992
5. Fung CE, Ng TH, Wong WT : Sparganosis of the spinal cord. Case report. *J Neurosurg* 71 : 290-292, 1989
6. Hughes AJ, Biggs BA : Parasitic worms of the central nervous system: an Australian perspective. *Intern Med J* 32 : 541-553, 2002
7. Kim H, Kim SI, Cho SY : Serological diagnosis of human sparganosis by means of micro-ELISA. *Kisaengchunghak Chapchi* 22 : 222-228, 1984
8. Kudesia S, Indira DB, Sarala D, Vani S, Yasha TC, Jayakumar PN, et al. : Sparganosis of brain and spinal cord : unusual tapeworm infestation (report of two cases). *Clin Neurol Neurosurg* 100 : 148-152, 1998
9. Kwon JH, Kim JS : Sparganosis presenting as a conus medullaris lesion: case report and literature review of the spinal sparganosis. *Arch Neurol* 61 : 1126-1128, 2004
10. Lee CW, Sohn KA : A case of sparganum mansonii in spinal canal. *J Korean Surg Soc* 7 : 155-158, 1965
11. Lo YK, Chao D, Yan SH, Liu HC, Chu FL, Huang CI, et al. : Spinal cord proliferative sparganosis in Taiwan : a case report. *Neurosurgery* 21 : 235-238, 1987
12. Park CK, Ha YS, Huh CW, Song JU : A case of sparganosis in the intradural space of the thoracolumbar spine. *J Korean Surg Soc* 12 : 739-743, 1983