

## Case Report

# Bilateral Visual Loss as a Sole Manifestation Complicating Carotid Cavernous Fistula

Jeong-Keun Yu, M.D.,<sup>1</sup> Gyojun Hwang, M.D.,<sup>2</sup> Seung Hun Sheen, M.D.,<sup>1</sup> Yong-Jun Cho, M.D., Ph.D.<sup>1</sup>

Department of Neurosurgery,<sup>1</sup> Chuncheon Sacred Heart Hospital, Hallym University, Chuncheon, Korea

Department of Neurosurgery,<sup>2</sup> Chuncheon Sacred Heart Hospital, Hallym University and Graduate School of Gangwon University, Chuncheon, Korea

Visual loss is one of the ocular symptoms resulting from a carotid cavernous fistula (CCF), but has rarely been reported as the sole manifestation in CCF. Visual impairment is known to be associated with a poor outcome unless timely intervention is employed. Herein, the authors report a patient with bilateral rapid progressing visual loss as a sole manifestation in CCF. Vision was successfully restored by transarterial embolization. The authors discuss the necessity of urgent fistula obliteration in patients with visual loss.

**Key Words** : Carotid cavernous fistula · Endovascular.

## INTRODUCTION

The incidence of visual loss complicating carotid cavernous fistula (CCF) has been reported to vary between 21 and 63%<sup>6,8,10</sup>. Progressive visual loss is caused by hemodynamic changes, which lead to an elevation in intraocular venous pressure and are usually accompanied by other manifestations, such as, chemosis, proptosis, and diplopia. Visual impairment may also result from secondary glaucoma or corneal exposure. Therefore, visual loss without other symptoms has rarely been reported in CCF. Here, we report a patient with bilateral rapid progressing visual loss as a sole manifestation in CCF, who responded successfully to transarterial embolization.

## CASE REPORT

A 71-year-old man presented with progressive bilateral visual loss of 2 days duration. He had experienced a rollover accident 7 days before presentation, and a craniofacial CT taken at the time was unremarkable. He appeared to have no gross eye abnormality, including chemosis and proptosis. On ophthalmological examination, vision was light-perception in the right and 4/20 in the left eye, and intraocular pressures were 14 and

11 mmHg, respectively. Extraocular movement showed no limitation, and a fundus examination revealed no abnormality. However, magnetic resonance angiography suggested a right CCF (Fig. 1A). The lesion was confirmed by conventional angiography, which showed a laceration at the vertical segment of the cavernous internal carotid artery (Fig. 1B, C). This direct CCF drained into the bilateral the sphenobasal sinus and the ipsilateral inferior petrosal sinus. Furthermore, contrast was visualized in the superior ophthalmic vein until the venous phase of the angiographic run, suggesting occlusion. Otherwise, the choroidal blush was well observed without a delay and no remarkable finding was noted in the ocular drainage veins.

The CCF was urgently obliterated transarterially with a total of 6 bare platinum detachable coils [Fig. 2A, Trufill-DCS (Cordis, Bridgewater, NJ, USA) and MicroPlex (Micro-Vention, Aliso Viejo, CA, USA)]. His vision was improved at 2 weeks after embolization, and recovered to 12/20 in bilateral eyes 6 months after treatment. magnetic resonance anajography (MRA) conducted at his 6-month follow-up showed no detectable fistula (Fig. 2B).

## DISCUSSION

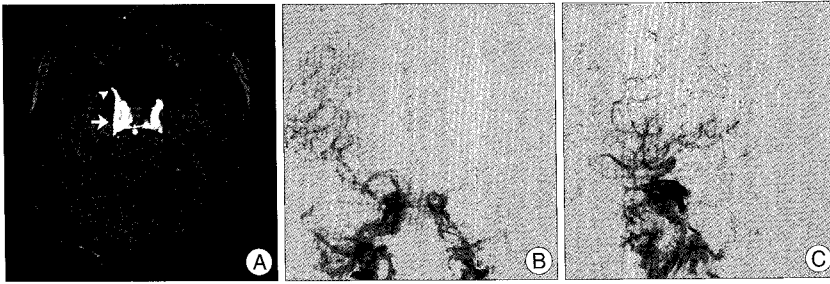
The mechanism of visual loss from a CCF is believed to begin with the generation of venous hypertension and the consequent reduction of perfusion in visual systems<sup>8,9</sup>. During the early phase, visual impairment is initiated by stagnant-flow anoxia leading to ischemia of the optic nerve<sup>2,5</sup>, a mechanical, axonal conduction block of the optic nerve caused by an elevated intraocular pressure<sup>2,5,9</sup>, or compression of the optic nerve or chi-

• Received : August 6, 2010 • Revised : September 6, 2010

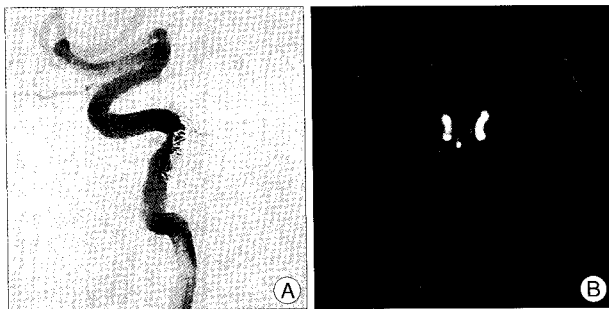
• Accepted : March 27, 2011

• Address for reprints : Gyojun Hwang, M.D.

Department of Neurosurgery, Chuncheon Sacred Heart Hospital, Hallym University and Graduate School of Gangwon University, 153 Gyo-dong, Chuncheon, Gangwon 200-704, Korea  
Tel : +82-33-240-5942, Fax : +82-33-242-9970  
E-mail : storynlemon@gmail.com



**Fig. 1.** Time of flight source magnetic resonance angiographic image (A) shows the right carotid cavernous fistula (arrow) draining into the superior ophthalmic vein (arrow head). The carotid cavernous fistula is observed by conventional angiography (B and C).



**Fig. 2.** Final angiography shows complete obliteration of the carotid cavernous fistula after embolization with 6 detachable coils (A). Six-month follow-up magnetic resonance angiography depicts to fistula reopening (time of flight source image, B).

asm by a distended cavernous sinus<sup>5</sup>. In these settings, the retina appears normal and the visual impairment is reversible. However, if high pressure generated by a fistula continues to impact visual systems, irreversible optic neuropathies, including optic nerve atrophy, infarction, and trauma to the nerve may occur<sup>4,7,8,10,11</sup>. Therefore, in CCF cases with visual impairment, fistula obliteration is urgently required to prevent irreversible change, for when vision worsen to blindness, recovery is not possible despite successful CCF embolization<sup>1-3</sup>.

In case that show only visual loss with no accompanying manifestations, it is difficult to suspect CCF, because of its rarity. However, if a patient has a history of head trauma, CCF should be considered as a cause of visual impairment. Additionally, if a patient has visual loss but a normally appearing retina, the visual symptom is potentially reversible. Therefore, the CCF must be promptly obliterated. The rapid progressive visual loss in our patient is believed to have been caused by stagnant-flow anoxia, and thus, timely intervention resulted in the return of vision.

## CONCLUSION

Although visual loss is rarely the sole manifestation in direct CCF, if visual symptoms occur after head trauma, CCF should be considered as a cause. In cases of CCF with visual loss but a normal retina, urgent intervention is required to improve visual symptoms, because in such cases visual loss may be reversible.

## Acknowledgements

This study was supported by BioGreen 21 Program (200810FTH010103002 and 200810FTH010102001) of Rural Development Administration.

## References

1. Albuquerque FC, Heinz GW, McDougall CG : Reversal of blindness after transvenous embolization of a carotid-cavernous fistula : case report. *Neurosurgery* 52 : 233-236; discussion 236-237, 2003
2. Brodsky MC, Hoyt WF, Halbach VV, Hieshima GB, Higashida RT, Barbaro NM : Recovery from total monocular blindness after balloon embolization of carotid-cavernous fistula. *Am J Ophthalmol* 104 : 86-87, 1987
3. Das S, Bendok BR, Novakovic RL, Parkinson RJ, Rosengart AJ, Macdonald RL, et al. : Return of vision after transarterial coiling of a carotid cavernous sinus fistula : case report. *Surg Neurol* 66 : 82-85; discussion 85, 2006
4. Edwards MS, Chater NL, Stanley JA : Reversal of chronic ocular ischemia by extracranial-intracranial arterial bypass: case report. *Neurosurgery* 7 : 480-483, 1980
5. Hedges TR 3rd, Debrun G, Sokol S : Reversible optic neuropathy due to carotid-cavernous fistula. *J Clin Neuroophthalmol* 5 : 37-40, 1985
6. Leonard TJ, Moseley IF, Sanders MD : Ophthalmoplegia in carotid cavernous sinus fistula. *Br J Ophthalmol* 68 : 128-134, 1984
7. Liang CC, Michon JJ, Cheng KM, Chan CM, Cheung YL : Ophthalmologic outcome of transvenous embolization of spontaneous carotid-cavernous fistulas : a preliminary report. *Int Ophthalmol* 23 : 43-47, 1999
8. Palestine AG, Younge BR, Piepgras DG : Visual prognosis in carotid-cavernous fistula. *Arch Ophthalmol* 99 : 1600-1603, 1981
9. Russell NA, Mangan MA, Pryse-Phillips W, Sharma LK : Treatment of carotid cavernous fistula by intravascular occlusion using a balloon catheter. *Can J Surg* 22 : 452-455, 1979
10. Sanders MD, Hoyt WF : Hypoxic ocular sequelae of carotid-cavernous fistulae. Study of the causes of visual failure before and after neurosurgical treatment in a series of 25 cases. *Br J Ophthalmol* 53 : 82-97, 1969
11. Weinstein JM, Rufenacht DA, Partington CR, Graves VB, Strother CM, Appen RE, et al. : Delayed visual loss due to trauma of the internal carotid artery. *Arch Neurol* 48 : 490-497, 1991