

A Case of Non-alcoholic Steatohepatitis Treated with Herbal Medicine

Chang-Gue Son

Liver and Immunology Research Center, Oriental Medical College in Daejeon University

Objective: To understand the characteristic of non-alcoholic fatty liver disease (NAFLD) and non-alcoholic steatohepatitis (NASH), and study the traditional Korean medicine (TKM)-based strategies or therapeutics for them.

Methods: A male patient with NASH was treated with only Oriental therapies, and then the clinical outcome was evaluated by serum biochemical parameters and radiographs.

Result: The clinical and biochemical values of the patient fluctuated over three years according to the treatments and cessation of herbal medicines.

Conclusion: NASH or NAFLD are now prevalent and these disorders could be targets of TKM, and this case report would provide useful information.

Key Words : non-alcoholic fatty liver disease, non-alcoholic steatohepatitis, traditional Korean medicine, herbal medicine

Introduction

Non-alcoholic fatty liver disease (NAFLD) refers to hepatic disorders which are characterized as fatty liver changes not due to excessive alcohol use¹⁾. This disorder was once rare, but has currently reached epidemic proportions in developed countries²⁾. NAFLD covers a wide range of disease status, from only fatty accumulation to progressive hepatic inflammation in the liver. In general, most patients with NAFLD have few or no symptoms, and a liver can remain fatty without disturbing liver function. However, some patients infrequently progress to outright hepatic inflammation, so called non-alcoholic steatohepatitis (NASH)³⁾.

Over time, NASH may progress into fibrosis,

cirrhosis (20%), liver failure (9%) or hepatocellular carcinoma (1%), so it is regarded as a major cause of cirrhosis of the liver of unknown cause^{4,5)}. According to the change of lifestyle leading to over-nutrition, insulin resistance and a highly disordered metabolic milieu, the prevalence of NASH has been increasing⁶⁾. The etiology of NASH is still unclear and the development of therapeutics is extremely urgent^{7,8)}.

Traditional Korean medicine (TKM) has treated patients with various hepatic diseases for thousands years, and many herbal plants or formulae are being investigated as hepatotherapeutics^{9,10)}. However, the clinical experiences and academic reports on NAFLD or NASH in TKM field are very few. This case report presents a patient with NASH in order to

• Received : 29 March 2011

• Revised : 3 May 2011

• Accepted : 4 May 2011

• Correspondence to : Chang-Gue Son

Liver and Immunology Research Center, Daejeon Oriental Hospital of Daejeon University, 22-5 Daehung-dong, Jung-gu, Daejeon, 301-724, Republic of Korea.

Tel : +82-42-229-6807, Fax : +82-42-257-6398, Email : ckson@dju.ac.kr

provide a clinical characteristic and the possibility of herbal therapeutics.

Report of the case

1. Characteristics of patient and diagnosis

A 33-year-old man visited hepatology department complaining about his chronic fatigue symptoms. He had already recognized his abnormal liver function test from previous medical examination in western hospital. Laboratory data showed elevated serum activity of alanine and aspartate aminotransferase (ALT and AST), gamma-glutamyl transferase (GGT), as 155 IU/L, 118 IU/L, and 278 IU/L respectively. Tests for viral infection and auto-immune hepatitis were negative (HAV-Ig G: positive, HBs Ab: positive, HCV Ab: negative, antinuclear Ab: negative and smooth muscle Ab: negative respectively). The patient has been a smoker but not used alcohol usually. He usually underwent high level of physical activity and psychological stress due to his own business of an indoor driving range. Abdominal ultrasonography and computed topography revealed no abnormal features except moderate fatty liver (Fig. 1). He was slightly obese by 27 body mass index (BMI) without hyperlipidemia (about 124 mg/dl of total cholesterol and 122 mg/dl of triglyceride), and has a positive family history for hepatoma in his father.

2. Herbal drugs and treatments

The patient has been treated both as an outpatient

and inpatient. CGX syrup (three packs per day) and other herbal prescriptions such as *Injinhryungsan* were given to the patient. CGX syrup was composed of 13 herb extracts; 5 g each of *Artemisia capillaris* Herba, *Carapax Trionycis*, *Semen Raphani*; 3 g each of *Rhizoma Atractylodis Macrocephalae*, *Poria*, *Alismatis Rhizoma*, *Atractylodis Rhizoma*, *Salviae Miltiorrhizae Radix*; 2 g each of *Polyporus*, *Amomi Fructus*, *Aurantii Fructus*, and 1 g of *Glycyrrhizae Radix* and *Helenii Radix*. Acupuncture (mainly at HT4, LU9, LR3), moxibustion (CV4, CV8) and pharmacopuncture (CV4 with Yidam) were practiced irregularly. The patient has been recommended to reduce meat intake and exercise regularly.

3. Course of symptoms and lab examination

The patient has been irregularly treated for three years at Daejeon Oriental hospital. He didn't complain of any liver-related symptoms including bleeding tendency, jaundices, edema, or abdomen discomfort while undergoing frequent general fatigue, eye fatigue and sputum in the airway. The patient visited an Oriental hospital whenever he felt severe fatigue. General liver function tests and ultrasonography were performed around every six months, and computed topography yearly. The patient felt a good physical feeling, decrease of fatigue severity along with treatments, while serum levels of AST, ALT and GGT fluctuated between normal and about three-folds of physiological range (Table 1). Other hematological parameters including platelet count, prothrombin time, albumin, alpha fetoprotein (AFP)

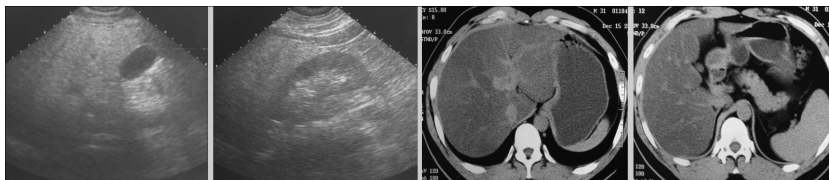


Fig. 1. Images from computed topography and ultrasonography.

There was fatty liver over grade two while no specific feature of hepatic pathologic view such as cirrhotic change or splenomegaly.

Table 1. Change of laboratory and radiological finding

Tested day	AST (IU/L)	ALT (IU/L)	GGT (IU/L)	ALP (IU/L)	T. bilirubin (mg/dl)	Radiology (Sono or CT)
Feb. 22, 2008	155	118	278	384	2.9	Fatty liver grade 2-3
Aug. 25, 2008	28	61	25	61	0.6	-
Oct. 27, 2008	41	114	37	76	0.6	Fatty liver grade 2
Jun 08, 2009	23	42	22	80	0.6	Fatty liver grade 2
Oct. 04, 2010	85	171	4	77	2.1	-
Dec. 23, 2010	30	90	35	83	0.9	Fatty liver grade 2
Feb. 21, 2011	34	81	30	73	0.9	Fatty liver grade 2

The diagnosis of fatty liver is described as grade 0 to 3 based on the increased echogenicity, liver-kidney contrast, vascular blurring and deep attenuation¹¹. No abnormal finding in computed topography except fatty liver.

and PIVKA-II (proteins induced by vitamin K absence or antagonist-II) were maintained within normal level (data not shown).

Discussion and Conclusion

NASH is the most extreme form of NAFLD, which causes inflammation and accumulation of fat and fibrous tissue in the liver. Patients with NASH are most often discovered during routine laboratory tests because of presence of no NASH-specific symptoms except general fatigue¹². The patient of this report complained only of fatigue including eye fatigue and respiratory sputum. NASH has been known to not develop serious liver problems; however some patients progress to liver fibrosis or cirrhosis¹³. Via over-time observation of NASH patients, one study reported that the condition of NASH improved in about 3%, remained stable in 54%, and worsened in 43% of people into fibrosis or cirrhosis¹⁴.

This patient was not diagnosed with NASH before visiting the Oriental hospital, but recognized just as abnormal liver function in western hospitals. Biochemical and imaging tests reveal hepatic damage and fat accumulation in the liver, but cannot differentiate NASH from other causes of liver

disease. Although liver biopsy is required to confirm NASH, it is invasive and has drawbacks in sampling and interpretation error¹⁵. This patient could be diagnosed into NASH based on biochemical results and imaging finding as well as exclusive factors (viral infection, immunological test and none history of alcohol use) without liver biopsy.

Due to his concern about the risk of progress to worse disorders, he stopped cigarette smoking and made an effort at weight control and more vegetarian diet. NASH is strongly associated with metabolic syndrome (diabetes, obesity, combined hyperlipidemia, and hypertension) and insulin resistance, and smoking is associated with histological severity^{16,17}. However, the exact cause of NASH and underlying mechanisms of progress into inflammation from hepatic steatosis are unknown. Oxidative stress is considered as a potential cause of further injury in NASH progress¹⁸. Genetic polymorphisms and genetic mutations for high prevalence of NASH or NAFLD were identified, and are associated with the susceptibility against hyperlipidemia, insulin resistance and oxidative stress¹⁹⁻²¹. The patient had no insulin resistance but hyperlipidemia, and family history of father's hepatoma. The father wasn't an HBV carrier but used to drink alcohol, so the cause of the hepatoma cannot be accurately proposed.

The physical symptoms and laboratory findings generally improved along with treatment; however they frequently fluctuated if the treatment was stopped. The main treatments in Oriental hospital were herbal prescriptions (CGX and others), acupuncture, moxibustion (CV4 and CV8) and pharmacopuncture (CV4 with Yidam). To date, there is no standardized therapy for NASH in western medicine, and lifestyle modifications for metabolic syndrome such as change of diet, weight loss and control of lipid levels are strongly suggested^{6,22)}. Some herbal plants and prescriptions with antioxidant properties have shown positive results in NASH^{23,24)}. CGX prescribed to the patient has also been evidenced to possess potential antioxidant actions^{25,26)}. This patient responded positively to herbal medicine and other treatments in Oriental hospital. For three years, no pathologically progressive signs were observed in consecutive examination of blood tests and radiological findings. However, these therapeutics were not completely curative owing to relapse of the disorder. In fact, NASH is a chronic disease, thus the patient should be treated continuously. This patient showed typical features of NASH.

NAFLD and NASH patients are increasing in number in developed countries worldwide, and now NASH prevalence is estimated to be 2.3% of the general population in India. Owing to the current lifestyle, NASH will be more prevalent and become a serious medical issue, but still no impactful therapeutics exists. Oriental medicine could promise new therapeutics for NASH or NAFLD in the future, and this study provides us useful information using a classical case of NASH.

Acknowledgements

This study was supported by a National Research Foundation of Korea (NRF) grant funded by the Korea government (MEST) (No. 20100028119)

Reference

1. Adams LA, Angulo P. Treatment of non-alcoholic fatty liver disease. *Postgrad Med J*. 2006; 82(967):315-22.
2. Farrell GC, Chitturi S, Lau GK, Sollano JD. Guidelines for the assessment and management of non-alcoholic fatty liver disease in the Asia-Pacific region: executive summary. *J Gastroenterol Hepatol*. 2007; 22(6):775-7.
3. Clark JM, Diehl AM. Nonalcoholic fatty liver disease: an underrecognized cause of cryptogenic cirrhosis. *JAMA*, 2003; 289 (22): 3000-4.
4. Chavez-Tapia NN, Uribe M, Ponciano-Rodríguez G, Medina-Santillán R, Méndez-Sánchez N. New insights into the pathophysiology of nonalcoholic fatty liver disease. *Ann Hepatol*. 2009; 8:S9-S17.
5. Abrams GA, Kunde SS, Lazenby AJ, Clements RH. Portal fibrosis and hepatic steatosis in morbidly obese subjects: a spectrum of nonalcoholic fatty liver disease. *Hepatology*. 2004; 40:475-83.
6. Neuschwander-Tetri BA. Lifestyle modification as the primary treatment of NASH. *Clin Liver Dis*. 2009; 13(4):649-65.
7. Larter CZ, Chitturi S, Heydet D, Farrell GC. A fresh look at NASH pathogenesis. Part 1: the metabolic movers. *J Gastroenterol Hepatol*. 2010 Apr; 25(4):672-90.
8. Golovanova EV, Vinnitskaia EV, Shaposhnikova NA, Petrakov AV, Mel'kina ES. Effectiveness of the new plant hepatoprotector--Ropren in patients with non-alcoholic steatohepatitis. *Eksp Klin Gastroenterol*. 2010; (7):97-102.
9. Jaeschke H, Williams CD, McGill MR, Farhood A. Herbal extracts as hepatoprotectants against acetaminophen hepatotoxicity. *World J Gastroenterol*. 2010; 16(19):2448-50.

10. Chien CF, Wu YT, Tsai TH. Biological analysis of herbal medicines used for the treatment of liver diseases. *Biomed Chromatogr.* 2011; 25(1-2):21-38.
11. Açikel M, Sunay S, Koplay M, Gündoğdu F, Karakelleoğlu S. Evaluation of ultrasonographic fatty liver and severity of coronary atherosclerosis, and obesity in patients undergoing coronary angiography. *Anadolu Kardiyol Derg.* 2009; 9(4):273-9.
12. Newton JL, Pairman J, Wilton K, Jones DE, Day C. Fatigue and autonomic dysfunction in non-alcoholic fatty liver disease. *Clin Auton Res.* 2009; 19(6):319-26.
13. Alazmi WM, Regev A, Molina EG, Schiff ER. Predictors of cirrhosis in Hispanic patients with nonalcoholic steatohepatitis. *Dig Dis Sci.* 2006; 51(10):1725-9.
14. Powell EE, Cooksley WG, Hanson R, Searle J, Halliday JW, Powell LW. The natural history of nonalcoholic steatohepatitis: a follow-up study of forty-two patients for up to 21 years. *Hepatology.* 1990; 11(1):74-80.
15. Adams LA, Feldstein AE. Nonalcoholic steatohepatitis: risk factors and diagnosis. *Expert Rev Gastroenterol Hepatol.* 2010; 4(5):623-35.
16. Marchesini G, Marzocchi R. Metabolic syndrome and NASH. *Clin Liver Dis.* 2007; 11(1):105-17.
17. Tsochatzis EA, Papatheodoridis GV. Smoking is associated with histological severity in nonalcoholic steatohepatitis. *Hepatology.* 2010; 52(4):1522-3.
18. Videla LA, Rodrigo R, Araya J, Poniachik J. Insulin resistance and oxidative stress interdependency in non-alcoholic fatty liver disease. *Trends Mol Med.* 2006; 12(12):555-8.
19. Petersen KF, Dufour S, Hariri A, Nelson-Williams C, Foo JN, Zhang XM, *et al.* Apolipoprotein C3 gene variants in nonalcoholic fatty liver disease. *N Engl J Med.* 2010; 362(12):1082-9.
20. Carulli L, Canedi I, Rondinella S, Lombardini S, Ganazzi D, Fargion S, *et al.* Genetic polymorphisms in non-alcoholic fatty liver disease: interleukin-6-174G/C polymorphism is associated with non-alcoholic steatohepatitis. *Dig Liver Dis.* 2009; 41(11):823-8.
21. Malínská H, Oliyarnyk O, Hubová M, Zídek V, Landa V, Simáková M, *et al.* Increased liver oxidative stress and altered PUFA metabolism precede development of non-alcoholic steatohepatitis in SREBP-1a transgenic spontaneously hypertensive rats with genetic predisposition to hepatic steatosis. *Mol Cell Biochem.* 2010; 335(1-2): 119-25.
22. Caldwell S, Lazo M. Is exercise an effective treatment for NASH? Knowns and unknowns. *Ann Hepatol.* 2009; 8 Suppl 1:S60-6.
23. Haddad Y, Vallerand D, Brault A, Haddad PS. Antioxidant and Hepatoprotective Effects of Silibinin in a Rat Model of Nonalcoholic Steatohepatitis. *Evid Based Complement Alternat Med.* 2009. Epub ahead of print.
24. Kim SH, Lee JH, Jung YJ, Choi MY, Kim YC, Woo HJ. A Case of Nonalcoholic Steatohepatitis in a child patient. *Korean J. Orient. Int.* 2010; 31(2):1106-10.
25. Hu XP, Shin JW, Wang JH, Cho JH, Son JY, Cho CK, *et al.* Antioxidative and hepatoprotective effect of CGX, an herbal medicine, against toxic acute injury in mice. *J Ethnopharmacol.* 2008; 120(1):51-5.
26. Wang JH, Shin JW, Son JY, Cho JH, Son CG. Antifibrotic effects of CGX, a traditional herbal formula, and its mechanisms in rats. *J Ethnopharmacol.* 2010; 127(2):534-42.