

## Clinical Article

# Percutaneous Radiofrequency Thermocoagulation Under Fluoroscopic Image-Guidance for Idiopathic Trigeminal Neuralgia

Byung-Chul Son, M.D., Ph.D., Hyung-Suk Kim, M.D., Il-Sup Kim, M.D., Ph.D., Seung-Ho Yang, M.D., Ph.D., Sang-Won Lee, M.D., Ph.D.

Department of Neurosurgery, St. Vincent's Hospital, The Catholic University of Korea College of Medicine, Suwon, Korea

**Objective :** We retrospectively investigated the long-term results of percutaneous radiofrequency thermocoagulation (RFT) using fluoroscopic image-guidance for treatment of trigeminal neuralgia.

**Methods :** A total of 38 patients diagnosed and treated with RFT as an idiopathic trigeminal neuralgia were investigated. To minimize the risks related to conventional technique based on cutaneous landmarks, and to eliminate the need to frequent reposition of cannula, we adopted a technique of image-guided fluoroscopic cannulation of the foramen ovale. To minimize sensory complication following thermal lesion, our target response was a generation of a lesion with mild to moderate hypalgesia rather than dense hypalgesia.

**Results :** The immediate pain-relief was achieved in all patients underwent RFT. With mean duration of follow-up of 38.2 months (range, 12-72), 11 (28.9%) experienced recurrence of pain. The mean timing of recurrence was 26.1 months (range, 12-46). A 42.7% recurrence rate was estimated by Kaplan-Meier analysis for the 38 patients at 46 months; 20.2% within 2 years, 29.1% within 3 years. In the long-term, 27 patients (71%) and 6 patients (15.8%) showed Barrow Neurological Institute (BNI) score I and BNI score II responses. Three (7.9%) patients was assessed as BNI score III, 2 patients (5.3%) showed BNI score IV response. As a complication, troublesome dysesthesia occurred in 3 of 38 patients (7.9%), however, there was no permanent cranial nerve palsy or morbidity.

**Conclusion :** These results indicates that RFT under fluoroscopic image-guided cannulation of foramen ovale is a safe, effective, and reliable means of treating trigeminal neuralgia.

**Key Words :** Fluoroscopy · Foramen ovale · Radiofrequency · Thermocoagulation · Trigeminal neuralgia.

## INTRODUCTION

Trigeminal neuralgia (TN), also known as tic douloureux, is a sudden, severe, brief, stabbing, recurrent pain in the distribution of the trigeminal nerve<sup>10</sup>. It has an estimated annual incidence of 12.6 per 100000 person-years<sup>18</sup>. Pain typically is in the distribution of the maxillary (V2) or mandibular (V3) divisions of the nerve, with ophthalmic (V1) division of pain alone occurring in less than 5% of patients. It can be either idiopathic or secondary to diseases such as tumors, infarction, and multiple sclerosis<sup>11</sup>. The mechanism of trigeminal pain production remains somewhat controversial. One theory suggests that disease of the post-ganglionic trigeminal nerve results in ephaptic

transmission between unmyelinated or partially demyelinated axons and normal heavily myelinated but damaged axons<sup>6</sup>.

All patients with trigeminal neuralgia preferentially undergo a trial of medical therapy using antiepileptic medication (typically carbamazepine). Among those patients treated medically, long-term relief fails in about 75% because of either pain recurrence or the development of toxic adverse effects. When patients become refractory to or intolerant of medical management, surgical options should be offered. Surgery has a high success rate, and can sufficiently ameliorate pain in most patients so that they will be able to discontinue medical management<sup>22</sup>. Among several means of surgical treatment, percutaneous radiofrequency thermocoagulation (RFT) has proven to be an invaluable innovation with a unique longevity and has high rates of success, acceptable durability, a respected safety profile, and a high level of patient satisfaction<sup>3,24,30,32,35,37,40</sup>.

Conventional puncture of the foramen ovale, which measures 6.5×3 mm in diameter and is located on the greater wing of the sphenoid bone, is based on external landmark. The needle is inserted 1 to 3 cm lateral to the labial commissure and then ad-

• Received : June 20, 2011 • Revised : August 26, 2011

• Accepted : November 21, 2011

• Address for reprints : Byung-Chul Son, M.D., Ph.D.

Department of Neurosurgery, St. Vincent's Hospital, The Catholic University of Korea College of Medicine, 93 Jungbu-daero, Paldal-gu, Suwon 442-723, Korea

Tel : +82-31-249-8206, Fax : +82-31-245-5208

E-mail : sbc@catholic.ac.kr

vanced freehand in the direction of the intersection of a coronal plane (3 cm anterior to the tragus) and a sagittal plane through the ipsilateral pupil under the control of submental X-ray. However this classic technique is not always accurate and, oftentimes, multiple punctures may be needed. Failure rates as high as 4%, as well as inadvertent puncture of the foramen lacerum and carotid artery, inferior orbital fissure, and jugular foramen, have been reported<sup>2</sup>. Needle placement may cause patient annoyance, facial hematoma, and postoperative pain, especially when several attempts are required<sup>2,26,39</sup>.

To facilitate radiological visualization of the foramen ovale, Gerber<sup>8</sup>) proposed a fluoroscopic imaging technique using “zygomatic points”. His finding was that the foramen ovale lies between the anterior border of the mandibular ramus and the lateral edge of maxilla and a line connecting point on the zygoma 2.5 cm anterior to each external meatus passes through both foramen ovale. We adopted this fluoroscopic technique as a routine method for cannulation of the foramen ovale and investigated our long-term results of RFT for idiopathic trigeminal neuralgia.

## MATERIALS AND METHODS

### Selection criteria

All patients from one neurosurgical unit who were diagnosed as primary TN and subsequently treated with RFT of the gasserian ganglion between 2003 and 2010 were evaluated and followed up until March 2011. All patients gave verbal and written informed consents. All patients had previously had drug treatment with carbamazepine and/or phenytoin. RFT was recommended due to lack of efficacy or poor tolerance to drugs. None had undergone any surgical treatment for their trigeminal neuralgia that could have resulted in other types of pain. The patients with secondary trigeminal neuralgia, atypical facial pain, and who had other types of surgery such as radiosurgery or microvascular decompression (MVD) were excluded in this study. Patients with primary TN involving V1 branch were also excluded because gamma knife radiosurgery and peripheral neurectomy were offered primarily.

The diagnostic criteria for primary, idiopathic TN were : 1) pain in the region of the trigeminal nerve., unilateral at any of time; 2) paroxysmal with pain-free periods, abrupt onset; 3) sharp, shooting, electric shock-like pain; 4) provoked by light touch; 5) responded initially to anti-neuralgic therapy. Recurrence was defined as a return of persistent trigeminal pain, which had the same characteristics as pre-operatively, and required regular carbamazepine/phenytoin<sup>40</sup>.

### Demographics

The mean age of the patients with RFT

was 70.61±7.79 (n=38, mean±standard deviation), 18 of whom were female. Twenty patients (52.6%) had their trigeminal neuralgia affecting the right side, 18 (47.4%) on the left side. The most common divisions affected were V3 (44.7%), and V2 and V3 (28.9%), and V2 (26.3%). The mean preoperative VAS was 6.68±0.87 (n=38, mean±standard deviation). The mean duration of follow-up was 38.18±7.79 months (n=38, mean±standard deviation, range, 12-72). Table 1 summarizes the demographics in our series.

### Techniques of cannulation of the foramen ovale and radiofrequency thermocoagulation

The patient lies in supine position with neck slightly extended. The head is rotated 20° away from the ipsilateral side, with the central X-ray beam directed at the foramen ovale at an angle 55° caudal to the orbitomeatal line. With this 55° caudocephalic tilting of fluoroscopy and 20° head rotation, the foramen ovale is just lateral to a line through that lateral wall of the orbit. It is important to keep the central beam angled at least 40° caudal to the orbitomeatal line. With less angulation, the foramen ovale may be superimposed on the petrous bones, thus obscuring the image. If the foramen ovale may be superimposed on the mandibular ramus, decreasing the angle of rotation of the head will place the foramen medial to the anterior ridge of the ramus (Fig. 1).

As a general precaution, it is recommended that the needle be directed at the anterolateral aspect of the foramen ovale and “walked” into the foramen<sup>8</sup>). This decreases the possibility of going too far posteromedially in the proximity of the carotid artery. The image intensifier can then be rotated for a lateral image to permit judgement of the depth of penetration of needles.

After local infiltration of 2% lidocaine along the trajectory of cannulation over the skin and subcutaneous tissue, the cannula was introduced under fluoroscopic guidance. After verification of depth of penetration of foramen ovale, test stimulation was given in 50 Hz and 2 Hz to elicit paresthesia of painful division of trigeminal nerve and to check the threshold of masseter contraction. Paresthesia was elicited with average 0.15 volt in most

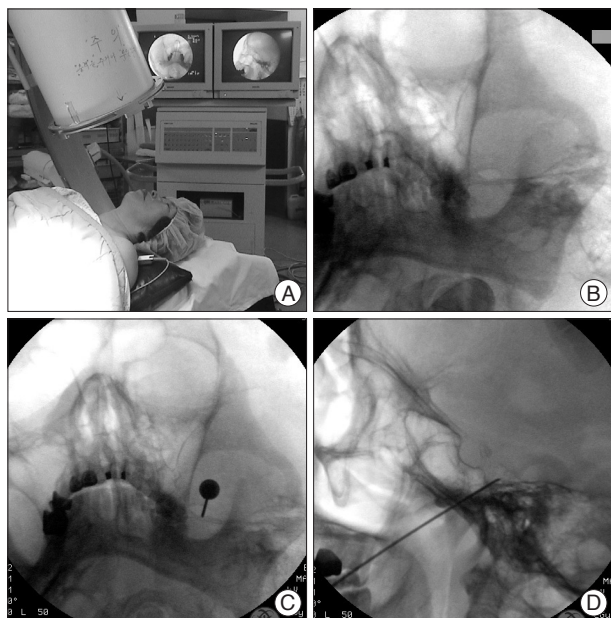
**Table 1.** Demographics of patients with idiopathic trigeminal neuralgia treated with percutaneous radiofrequency thermocoagulation

Characteristics	Patients (n=38)
Age	70.61±7.79 (mean±SD, range, 55-83)
Sex (F : M)	18 (47.4%) : 20 (52.6%)
Duration of symptoms (months)	26.29±14.96 (mean±SD, range, 8-84)
Affected side (R : L)	20 (52.6%) : 18 (47.4%)
Affected division	
V3	17 (44.7%)
V2+V3	11 (28.9%)
V2	10 (26.3%)
Duration of follow-up	38.18±7.79 (mean±SD, range, 12-84) months

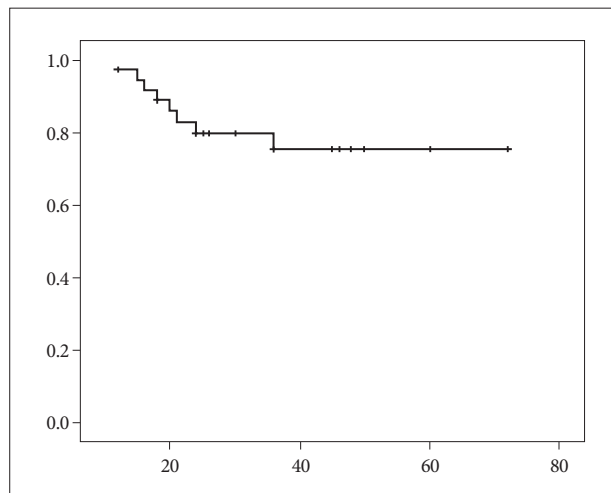
SD : standard deviation, R : right, L : left, V2 : maxillary branch of trigeminal nerve, V3 : mandibular nerve of trigeminal nerve

**Table 2.** Barrow Neurological Institute pain intensity score

Score	
I	No trigeminal pain, no medication
II	Occasional pain, not requiring medication
III	Some pain, adequately controlled with medication
IV	Some pain, not adequately controlled with medication
V	Severe pain/No pain relief



**Fig. 1.** A : A photograph showing an operative scene for percutaneous radiofrequency thermocoagulation under fluoroscopic image-guidance. Note the caudocephalic tilting of X-ray tube. B : A fluoroscopic image showing the foaramen ovale. With 55° caudocephalic tilting of fluoroscopy and 20° head rotation to ipsilateral side, the foramen ovale is just lateral to a line through that lateral wall of the orbit. C : A fluoroscopic image showing a cannula in the foramen ovale. D : A fluoroscopic image of skull lateral view showing a cannula reaching a clival line.



**Fig. 2.** A graph showing Kaplan-Meier analysis of the pain-free survival rate of 38 patients with idiopathic trigeminal neuralgia treated by radiofrequency thermocoagulation. In this graph, x-axis denotes pain-free survival in months and y-axis denotes cumulative survival.

cases (0.05-0.2 volt). After confirming the absence of side effect, radiofrequency heat lesion was made at 70°C, 75°C, and 80°C for 60 seconds each. Careful sensory testing of face was conducted during lesion making, and generating a lesion with mild to moderate, not dense, hypalgesia in the primarily affected division was our target response of thermocoagulation.

**Outcome measure**

The outcome of RFT was assessed in follow-up visits in every 2-3 months after the procedure. Patients were asked to describe their post-RFT pain using Barrow Neurological Institute (BNI) Pain intensity scores as shown in Table 2<sup>28</sup>. Patients were also questioned about facial numbness, medication use, time to pain relief, and duration of relief. Outcome was assessed using BNI pain scale and grouped as good (BNI class I or II, no medication required) and bad (BNI class III, IV, V, medication required or failed).

**Statistics**

Kaplan-Meier analysis of pain-free survival curves were constructed for the 38 patients. Logistic regression was used to assess the relationship of age, affected division, and duration of pain with outcomes. Cox regression was used to assess the influence of age, affected division, and duration of pain to duration of pain-free survival.

**RESULTS**

**Initial pain response**

All of the 38 patients experienced initial pain relief with RFT, BNI score I in 31 (81.6%), II in 4 (10.5%), and III in 3 (7.9%) patients. Thirty-seven out of 38 (97.4%) patients experienced variable degrees of numbness following RFT and facial numbness mostly subsided within 6 months after RFT.

**Rate and timing of pain recurrence**

With mean duration of follow-up of 38.18±7.79 months (n=38, mean±standard deviation, range, 12-72), 11 (28.9%) patients experienced recurrence of pain. The mean timing of recurrence was 26.09±11.49 months (n=11, mean±standard deviation, range, 12-46). A 42.7% recurrence rate was estimated by Kaplan-Meier analysis for the 38 patients at 46 months (Fig. 2); 20.2% within 2 years, 29.1% within 3 years. Of the 11 patients who had pain recurrence after one RFT, 4 patients (36.4%) did not require another surgery. Three of 4 had medical treatment and the remaining one had occasional mild pain that did not require treatment. Of the 7 patients (63.6%) who required further surgical treatment, 2 patients underwent MVD and 5 underwent repeated RFT. After a second RFT, 3 of these patients were pain-free, 2 had a major pain recurrence.

**Outcome**

Table 3 summarizes the outcome of RFT in our series. In the

long-term follow-up of 38 patients, 27 patients (71%) and 6 patients (15.8%) showed BNI score I and BNI score II responses, respectively. Three (7.9%) patients was assessed as BNI score III, two patients (5.3%) showed BNI score IV responses.

### Complications

Eight of 38 patients (21%) complained some degrees of dysesthesia. This facial sensory deprivation was described as “not disturbing and not troublesome” in 4 patients (50%), as “rare and a mild disturbance” in 2 (25%), as “an occasional and moderate disturbance” in 1 (12.5%), and as “a frequent and severe disturbance” in 1 (12.5%). Of 3 patients who had a repeat RFT for pain recurrence, three developed dysesthesia.

After a single RFT, 6 patients (15.8%) developed weakness of the pterygoid or masseter muscles. Weakness resolved completely within 6 months. We did not experience an occurrence of keratitis, paresis of extraocular muscles, and other cranial nerve deficit. There was no mortality and no permanent cranial nerve deficit except dysesthesia.

### Cannulation of the foramen ovale

The number of reposition needed during cannulation of the foramen ovale was 6. Therefore, total number of punctures needed for 38 patients were 44. There was no complication, such as hematoma and inadvertent puncture of other structures which was related to cannulation of foramen ovale. The time needed for cannulation of foramen was mostly within 10 minutes.

## DISCUSSION

### Pathophysiology of trigeminal neuralgia

The mechanism of pain of trigeminal neuralgia remains somewhat controversial<sup>13</sup>. Focusing on the PNS, ever since Dandy<sup>5</sup>) it has been widely believed that sustained (static) or pulsatile microvascular compression demyelinates sensory axons in the trigeminal root, and that this is the primary pathogenic process that causes TN. This presumption was strongly bolstered by Jannetta<sup>12</sup>), who not only documented vascular compression in a high proportion of TN patients, but also showed that prolonged pain relief can be obtained by MVD. Decompression of the root is presumed to relieve pain by facilitating remyelination<sup>1</sup>.

Unfortunately, even if trigeminal root compression is indeed the primary pathology in TN, demyelination alone does not produce a straightforward account of the disease's characteristic symptomatology<sup>6</sup>). Activity in myelinated sensory axons is generally associated with touch and vibration sense, not pain. Furthermore, demyelination per se is expected to block impulse

propagation, and hence yield patches of numbness rather than pain paroxysm. Ephaptic contact between adjacent denuded axons has long been cited as a pain mechanism in TN, if without much specific evidence. Although ephapsis might amplify the sensation evoked by applied stimuli, generating hyperesthesia and even pain, it does not explain why pain paroxysm in TN outlast the triggering stimulus, and why their intensity bears no relation to the intensity of the stimulus<sup>19</sup>).

Rappaport and Devor<sup>27</sup>) proposed the ignition hypothesis held that impulse activity originates in peripheral aspect of the trigeminal system rather than in epileptic foci in the CNS. According to ignition hypothesis, the primary effect of microvascular compression is to induce localized trigeminal root pathology and perhaps trigeminal root ganglion (TRG) pathology. This renders trigeminal afferent neurons, both injured axons and axotomized somata, hyperexcitable. The hyperexcitable afferents, in turn, give rise to pain paroxysms as a result of synchronized afterdischarge activity originating at ectopic pacemaker sites in the root or TRG. Separation of the vessel from the root by MVD should provide instant pain relief and facilitate longer-term repair of the root<sup>6,27</sup>). Ablative root or TRG procedures (partial rhizotomy and glycerol, radiofrequency, and balloon gangliolysis) destroy neurons or their axons, thereby reducing the recruitment of ectopic neural activity. Denervation of trigger points by peripheral neurectomy prevents cutaneous triggering, but may leave a neuroma capable of acting as trigger, and it will not affect spontaneous paroxysms. Carbamazepine and anticonvulsant drugs probably relieve pain in TN by directly suppressing ectopic hyperexcitability in the root and TRG<sup>7</sup>). Anticonvulsants that act synaptically (e.g., barbiturates) are effective against seizure activity in the CNS, but not in TN.

### Radiofrequency thermocoagulation

The field of neurosurgery has a rich history of technological innovations, of which percutaneous stereotactic rhizotomy for TN claims a unique longevity. In fact, there have been only two major modifications to technique since its original description by Kirschner<sup>15</sup>). The first and most substantial advance was made in 1969 when White and Sweet<sup>38</sup>) refined the procedure with the use of a short-acting anesthetic agent, electrical stimu-

**Table 3.** Outcome and complication of radiofrequency thermocoagulation

Characteristics	Patients (n=38)				
Recurrence	11 (28.9%)				
Dysesthesia/Troublesome dysesthesia	8 (21%)/2 (5.3%)				
Mean timing of recurrence	26.09±11.5 (mean±SD, range, 12-46) months				
Immediate pain relief	BNI pain intensity score				
	Score I	Score II	Score III	Score IV	Score V
	31 (81.6%)	4 (10.5%)	3 (7.9%)		
Long-term pain relief	BNI pain intensity score				
	Score I	Score II	Score III	Score IV	Score V
	27 (71%)	6 (15.8%)	3 (7.9%)	2 (5.3%)	

BNI pain intensity score : Barrow Neurological Institute pain intensity score, SD : standard deviation

lation, a reliable radiofrequency current for lesion production, and temperature monitoring of tip of the electrode. The next innovation made by the Tew, van Loveren, and Keller group included both the introduction of the Tew curved-tip electrode (Radionics, Burlington, MA, USA)<sup>37</sup> and the modification of the technique for cannulation of the foramen ovale using image-guided fluoroscopy<sup>34</sup>.

As a mechanism of radiofrequency thermocoagulation, the differential thermocoagulation of trigeminal rootlets has been proposed. This concept proposes that the compound action potentials of A- $\delta$  and C fibers (nociceptive fibers) in a nerve are blocked at a lower temperature than are those of A- $\alpha$  and A- $\beta$  that carry tactile sensations<sup>20</sup>. However, some histologic studies have not documented this selective destruction of pain-sensitive A- $\delta$  and C fibers after thermocoagulation<sup>31</sup>. Thermal rhizotomy, like other percutaneous treatments, may be effective because it reduced the overall sensory input to the demyelinated peripheral site of ephaptic transmission<sup>4</sup>. Ignition hypothesis explains that ablative root or TRG procedures including RFT destroy neurons or their axons, thereby reducing the recruitment of ectopic neural activity<sup>6</sup>.

### Cannulation of the foramen ovale

Since the description of the anterior approach through the cheek to the foramen ovale by Härtel<sup>9</sup> this approach has been used for injection, radiofrequency thermocoagulation, and balloon compression of the gasserian ganglion<sup>8,14,32</sup>. Skin guidelines and needle trajectories for penetrating the foramen ovale have been described by Nugent and Berry<sup>25</sup>, Tew and Keller<sup>33</sup>, and Rovit<sup>29</sup>. Common to their techniques is a skin marker over the ipsilateral zygoma that approximates the lateral projection of the foramen ovale onto the skin. Tew and Keller place this "zygomatic point" 3 cm anterior to the external auditory meatus, Nugent and Berry at a point 2.5 cm anterior to the auditory canal, and Robit at two-thirds of the distance between the lateral canthus and the external auditory meatus. Another skin guideline is located on the medial aspect of the ipsilateral pupil. When used in conjunction with the puncture point adjacent to the second molar described by Härtel<sup>9</sup>, these skin guidelines have permitted surgeons to place needles in close proximity to the foramen ovale to be able to penetrate it with minimal adjustment.

However, Gerber<sup>8</sup> pointed out some limitations inherent in all approaches. Even with ideal positioning of the patient's head, it could be difficult to clearly visualize the foramen ovale. He explained this difficulty for osteoporosis involving a target structure, increased calcification of the skull or dura, and technical difference in imaging equipment. To facilitate radiological visualization of the foramen ovale, he studied the basilar aspects of dried skull and proposed technique of improved fluoroscopic identification of the foramen ovale<sup>8</sup>. After taping of a metal ring (5 mm in diameter) over each zygomatic point (2.5 cm anterior to the external meatus), the head is rotated 20° away from

the ipsilateral side, with the axis of fluoroscopy was tilted at an angle 55° caudal to the orbitomeatal line. With this 55° caudocephalic tilting of fluoroscopy and 20° head rotation, the foramen ovale is just lateral to a line through that lateral wall of the orbit. With this technique of fluoroscopic image-guided cannulation, we did not experience any difficulty during puncture of foramen ovale and could minimize the risk of inadvertent puncture of adjacent structures around the foramen ovale. We feel that this technique is a quite simple, reliable, and technically straightforward means of cannulation of foramen ovale.

While current authors are adopting the fluoroscopic image-guided cannulation to overcome the problem of conventional technique of puncturing the foramen ovale, others have tried to develop new techniques of cannulation using frame-based stereotactic method, frameless stereotactic cannulation with real-time computed tomography (CT) scans<sup>2,16,26,39</sup>. Patil<sup>26</sup> described his experience of 36 RFT procedures using a stereotactic frame and intraoperative CT scans. Bale, et al.<sup>2</sup> described frameless stereotactic cannulation of the foramen ovale and they advocated that frameless technique may enhance patient security and cannulation success, independent of surgeon's experience. However, it is hard to conclude this frame and frameless techniques using intraoperative, real-time CT is more effective and accurate, and safer than current technique of authors, or conventional technique using Hartel's cutaneous landmarks. It is not clear whether this two-stage preparation, stereotactic apparatus on the head or secured with a vacuum mouthpiece might interfere, or enhance, the patient's comfort and concentration to intraoperative physiologic stimulation. Another potential problem with navigation systems based on predetermined linear trajectory is that these assume that the cannula does not bend. However, this may not always be true when one navigates among the bony structures at the cranial base. In addition, when there is a bony prominence around the foramen ovale which can interfere a successful cannulation during conventional technique, this obstacle would probably impede a CT scan navigation-guided procedure as well. Increase of operation time and cost would be the next problem.

### Results of radiofrequency thermocoagulation

When contemplating the most appropriate surgical intervention for a particular patient with trigeminal neuralgia, the advantages and disadvantages of the three primary treatment modalities must be considered. Each technique, percutaneous [thermal rhizolysis, glycerol rhizolysis (GR), and balloon compression (BC)], MVD, and stereotactic radiosurgery (SRS), possesses certain attributes and limitations. Additionally, peripheral neurectomy of any of the three peripheral branches of the trigeminal nerve must still be considered an option by all surgeons who treat this condition.

According to a systematic review of ablative neurosurgical techniques (RFT, GR, BC, SRS) for TN<sup>21</sup>, RFT is superior to GR and SRS in terms of early and late rates of complete pain relief.

However, it is also associated with the greatest number of complications. GR is also superior to SRS in terms of early complete pain relief, although it seems to be the least effective technique after 24 months. A recent, nationwide study of three invasive treatments [RFT, partial sensory rhizotomy (PSR), MVD] for trigeminal neuralgia in Netheland<sup>17</sup>, hospital type was the predominant determinant of procedure type; age, sex and comorbidity were weak predictors. Primary outcome in their study was readmission for repeat procedures for TN or known complication within 1 year. The relative risks (RR) for repeat procedures for PSR was 0.21 and for MVD was 0.13 compared with RFT (RR 1). For complications, the RR of PSR was 5.36 and of MVD was 4.40. Sex, urbanization, and comorbidity did not influence prognosis, but hospital and surgical volume did. They concluded that, although PSR and MVD are associated with a lower risk of repeat procedure than RFT, they seem to be more prone to complications requiring hospital readmission. Thus the result and complications according to treatment modalities seem to vary between studies and surgeons' experiences and preferences.

According to a prospective study of 15-year follow-up of 154 patients treated by RFT<sup>32</sup>, 153 (99%) of the patients obtained initial pain relief after one RFT and pain persisted in one (1%) patient. In our study of 38 patients with idiopathic TN, we could achieve initial pain relief in all patients with RFT, BNI score I in 31 (81.6%), II in 4 (10.5%), and III in 3 (7.9%) patients. There was no technical failure in our series.

Recurrence after treatment is another important issue in the treatment for TN. However, criteria for determining recurrence of trigeminal neuralgia are poorly defined in many surgical series and methods of analysis are not standardized. This makes comparison between different studies very difficult and variable<sup>40</sup>. The criteria used to diagnose return of pain in the present study was probably stricter than those of most other studies where a recurrence is not recorded until the patient undergoes re-operation. In our series, a 42.7% recurrence rate was estimated by Kaplan-Meier analysis for the 38 patients at 46 months (Fig. 2); 20.2 % within 2 years, 29.1% within 3 years, respectively. The mean timing of recurrence was  $26.09 \pm 11.49$  months ( $n=11$ , mean  $\pm$  standard deviation, range, 12-46). This is rather higher than that of a large, prospective report by Taha et al.<sup>32</sup> Their recurrence rate estimated by Kaplan-Meier analysis for 154 patients was a 25% recurrence rare at 14 years; 15% within 5 years, 7% within 5 to 10 years; and 3% within 10 to 15 years. The timing of recurrence varied according to the degree of sensory loss. All pain recurrence in patients with mild hypalgesia had pain recurrences within 4 years after surgery; 10% more of the patients with dense hypalgesia had pain recurrences within the first 10 years compared with patients with analgesia<sup>32</sup>. The median pain-free survival rate was 32 months for patients with mild hypalgesia and more than 15 years for patients with either analgesia or dense hypalgesia. A rather, high recurrence rate of the authors' series is an already expected finding by authors be-

cause the target response of thermal lesion in our RFT is mild hypalgesia instead of dense hypalgesia which was proposed by early authors<sup>32,35</sup>. However, considering that all patients with mild hypalgesia in Taha's series recurred within 4 years after RFT, our recurrence rate (28.9% in 38 months) is considerably low.

The reason why we made a weaker lesion was to minimize sensory complications such as dysesthesia. Though the previous report<sup>32</sup> described 77% of patients with dysesthesia regarded it as "not disturbing and not troublesome" and 15% regarded as "rare and a mild disturbance", we have experienced many of our patients with dysesthesia after RFT perceived dysesthesia as a new kind of pain and suffered from dysesthesia. The second reason for this weaker lesion is that RFT is an easy, safe, and effective means of lesioning even in the treatment of recurrent TN after RFT. Even in authors' series with making a mild analgesic lesion, eight of 38 patients (21%) experienced some degree of dysesthesia. However, 5 out of 8 patients regarded this dysesthesia as insignificant and acceptable. Therefore, troublesome dysesthesia occurred in 3 of 38 patients (7.9%) in our series.

We did not experience the complications from the procedure such as permanent trigeminal motor weakness, cranial nerve palsy, or postoperative morbidity.

Long-term results of RFT in series of at least 100 patients vary from 25 to 95%<sup>23</sup>. However, this low rate of 25% in the long-term pain relief seems to be caused by an extraordinary long follow-up period (14 years)<sup>36</sup>. In most series of RFT with relatively long-term follow-up which ranged between 3 to 6 years, the long-term pain relief rates were about 70 to 90%<sup>23</sup>. If both BNI score I and II are considered as a good outcome, 33 out of 38 patients (86.8%) in our series showed good outcome with 38 months of follow-up. This outcome seems to be comparable to those of previous reports dealing RFT for TN.

## CONCLUSION

Percutaneous radiofrequency thermocoagulation is a safe and effective means for treatment of trigeminal neuralgia. We could achieve an acceptable rate of long-term pain control with a less dense thermal lesion than previously reported. However, the estimated recurrence rate was rather higher than those of previous reports. It seems that a repeat percutaneous radiofrequency thermocoagulation does not pose a significant problem because the procedure is easily repeated with minimal risk. With the aid of fluoroscopic image-guided cannulation of the foramen ovale, we can minimize a complication related to procedure.

## References

1. Adams CB : Microvascular compression : an alternative view and hypothesis. *J Neurosurg* 70 : 1-12, 1989
2. Bale RJ, Laimer I, Martin A, Schlager A, Mayr C, Rieger M, et al. : Frameless stereotactic cannulation of the foramen ovale for ablative treatment of trigeminal neuralgia. *Neurosurgery* 59 : ONS394-ONS401; discussion ONS402, 2006
3. Broggi JA, Franzini A, Lasio G, Giorgi C, Servello D : Long-term results

- of percutaneous retrogasserian thermocoagulation for "essential" trigeminal neuralgia : considerations in 1000 consecutive patients. *Neurosurgery* 26 : 783-786; discussion 786-787, 1990
4. Brown JA : Percutaneous techniques in Winn HR (ed) : *Youmans Neurological Surgery*, ed 5. Philadelphia : Saunders, 2002, pp2996-2999
  5. Dandy WE : The treatment of trigeminal neuralgia by the cerebellar route. *Ann Surg* 96 : 787-795, 1932
  6. Devor M, Amir R, Rappaport ZH : Pathophysiology of trigeminal neuralgia : the ignition hypothesis. *Clin J Pain* 18 : 4-13, 2002
  7. Devor M, Seltzer Z : Pathophysiology of damaged nerves in relation to chronic pain in Wall PD, Melzack R (eds) : *Textbook of pain*, ed 4. London : Churchill Livingstone, 1994, pp129-164
  8. Gerber AM : Improved visualization of the foramen ovale for percutaneous approaches to the gasserian ganglion. Technical note. *J Neurosurg* 80 : 156-159, 1994
  9. Härtel F : Über die intracranielle injektionsbehandlung der trigeminusneuralgie. *Med Klin* 10 : 582-584, 1914
  10. International Association for the Study of Pain in Mersky H, Bokduk N (eds) : *Classification of Chronic Pain*. Seattle : IASP Press, 1994, pp59
  11. International Headache Society Classification Subcommittee : International classification of headache disorders, 2nd edition. *Cephalalgia* 24 : 1-160, 2004
  12. Jannetta PJ : Arterial compression of the trigeminal nerve at the pons in patients with trigeminal neuralgia. *J Neurosurg* 26 : 159-162, 1967
  13. Joffroy A, Levivier M, Massager N : Trigeminal neuralgia. Pathophysiology and treatment. *Acta Neurol Belg* 101 : 20-25, 2001
  14. Kang SB, Son BC, Kim MC, Kang JK : Effect of pain control with percutaneous radiofrequency rhizotomy in secondary trigeminal neuralgia. *J Korean Neurosurg Soc* 29 : 66-71, 2000
  15. Kirschner M : [Elektrocoagulation des ganglion gasserii]. *Zentralbl Chir* 47 : 2841-2843, 1932
  16. Koizuka S, Saito S, Tobe M, Sekimoto K, Obata H, Koyama Y : Percutaneous radiofrequency mandibular nerve rhizotomy guided by high-speed real time computed tomography fluoroscopy. *Anesth Analg* 111 : 763-767, 2010
  17. Koopman JS, de Vries LM, Dieleman JP, Huygen FJ, Stricker BH, Sturkenboom MC : A nationwide study of three invasive treatments for trigeminal neuralgia. *Pain* 152 : 507-513, 2011
  18. Koopman JS, Dieleman JP, Huygen FL, de Mos M, Martin CG, Strukenboom MC : Incidence of facial pain in the general population. *Pain* 147 : 122-127, 2009
  19. Kugelberg E, Lindblom U : The mechanism of the pain in trigeminal neuralgia. *J Neurol Neurosurg Psychiatry* 22 : 36-43, 1959
  20. Letcher FS, Goldring S : The effect of radiofrequency current and heat on peripheral nerve action potential in the cat. *J Neurosurg* 29 : 42-47, 1968
  21. Lopez BC, Hamlyn PJ, Zakrzewska JM : Systemic review of ablative neurosurgical techniques for the treatment of trigeminal neuralgia. *Neurosurgery* 54 : 973-982; discussion 982-983, 2004
  22. Lunsford LD, Niranjana A, Kondziolka D : Surgical management options for trigeminal neuralgia. *J Korean Neurosurg Soc* 41 : 359-366, 2007
  23. Margan CJ, Tew JM : Percutaneous stereotactic rhizotomy in the treatment of intractable facial pain in Schmidek HH, Sweet HH (eds) : *Operative neurosurgical techniques. Indications, Methods and Results*, ed 2. Orlando : Grune & Stratton, 1998, pp1519-1529
  24. Nugent GR : Radiofrequency treatment of trigeminal neuralgia using a cordotomy-type electrode. A method. *Neurosurg Clin N Am* 8 : 41-52, 1997
  25. Nugent GR, Berry B : Trigeminal neuralgia treated by differential percutaneous radiofrequency coagulation of the Gasserian ganglion. *J Neurosurg* 40 : 517-523, 1974
  26. Patil AA : Stereotactic approach to the trigeminal ganglion using a stereotactic frame and intraoperative computed tomography scans : technical note. *Stereotact Funct Neurosurg* 88 : 277-280, 2010
  27. Rappaport ZH, Devor M : Trigeminal neuralgia : the role of self-sustaining discharge in the trigeminal ganglion. *Pain* 56 : 127-138, 1994
  28. Rovit RL : Percutaneous radiofrequency thermal coagulation of the gasserian ganglion, in Rovit RL, Murali R, Jannetta PJ (eds) : *Trigeminal Neuralgia*. Baltimore : Williams & Wilkins, 1990, pp109-136
  29. Rogers CL, Shetter AG, Fiedler JA, Smith KA, Han PP, Speiser BL : Gamma knife radiosurgery for trigeminal neuralgia : the initial experience of The Barrow Neurological Institute. *Int J Radiat Oncol Biol Phys* 47 : 1013-1019, 2000
  30. Siegfried J : Percutaneous controlled thermocoagulation of the gasserian ganglion in trigeminal neuralgia. Experience with 1000 cases in Sami M, Jannetta PJ (eds) : *The Cranial nerves*. New York : Springer-Verlag, 1981, pp322-330
  31. Smith HP, McWhorter JM, Chalia VR : Radiofrequency neurolysis in a clinical model : Neuropathological correlation. *J Neurosurg* 55 : 246-253, 1981
  32. Taha JM, Tew JM Jr, Buncher CR : A prospective 15-year follow-up of 154 consecutive patients with trigeminal neuralgia treated by percutaneous stereotactic radiofrequency thermal rhizotomy. *J Neurosurg* 83 : 989-993, 1995
  33. Tew JM Jr, Keller JT : The treatment of trigeminal neuralgia by percutaneous radiofrequency technique. *Clin Neurosurg* 24 : 557-578, 1977
  34. Tew JM Jr, Keller JT, Williams DS : Application of stereotactic principles to the treatment of trigeminal neuralgia. *Appl Neurophysiol* 41 : 146-156, 1978
  35. Tew JM Jr, Taha KM : Percutaneous rhizotomy in the treatment of intractable facial pain (trigeminal, glossopharyngeal, and vagal nerve) in Schmidek HH, Sweet WH (eds) : *Operative Neurosurgical Techniques : Indications, Methods and Results*. Philadelphia : W.B. Saunders Co, 1995, pp1469-1484
  36. Tronnier VM, Rasche D, Hamer J, Kienle AL, Kunze S : Treatment of idiopathic trigeminal neuralgia : comparison of long-term outcome after radiofrequency rhizotomy and microvascular decompression. *Neurosurgery* 48 : 1261-1267; discussion 1267-1268, 2001
  37. van Loveren H, Tew JM Jr, Keller JT, Nurre MA : a 10-year experience in the treatment of trigeminal neuralgia. Comparison of percutaneous stereotactic rhizotomy and posterior fossa exploration. *J Neurosurg* 57 : 757-764, 1982
  38. White JC, Sweet WH : *Pain and the Neurosurgeon*. Springfield : Charles C Thomas, 1969, pp594-621
  39. Xu SJ, Zhang WH, Chen T, Wu CY, Zhou MD : Neuronavigator-guided percutaneous radiofrequency thermocoagulation in the treatment of intractable trigeminal neuralgia. *Chin Med J (Engl)* 119 : 1528-1535, 2006
  40. Zakrzewska JM, Jassim S, Blum JS : A prospective, longitudinal study on patients with trigeminal neuralgia who underwent radiofrequency thermocoagulation of the Gasserian ganglion. *Pain* 79 : 51-58, 1999