

Clinical Article

Minimally Invasive Multi-Level Posterior Lumbar Interbody Fusion Using a Percutaneously Inserted Spinal Fixation System : Technical Tips, Surgical Outcomes

Hyeun Sung Kim, M.D.,¹ Keun Ho Park, M.D.,² Chag Il Ju, M.D.,³ Seok Won Kim, M.D.,³ Seung Myung Lee, M.D.,³ Ho Shin, M.D.³

Department of Neurosurgery,¹ Daejeon Hurisarang Hospital, Daejeon, Korea

Department of Orthopedic,² Jeonju Korea Hospital, Jeonju, Korea

Department of Neurosurgery,³ College of Medicine, Chosun University, Gwangju, Korea

Objective : There are technical limitations of multi-level posterior pedicle screw fixation performed by the percutaneous technique. The purpose of this study was to describe the surgical technique and outcome of minimally invasive multi-level posterior lumbar interbody fusion (PLIF) and to determine its efficacy.

Methods : Forty-two patients who underwent mini-open PLIF using the percutaneous screw fixation system were studied. The mean age of the patients was 59.1 (range, 23 to 78 years). Two levels were involved in 32 cases and three levels in 10 cases. The clinical outcome was assessed using the visual analog scale (VAS) and Low Back Outcome Score (LBOS). Achievement of radiological fusion, intra-operative blood loss, the midline surgical scar and procedure related complications were also analyzed.

Results : The mean follow-up period was 25.3 months. The mean LBOS prior to surgery was 34.5, which was improved to 49.1 at the final follow up. The mean pain score (VAS) prior to surgery was 7.5 and it was decreased to 2.9 at the last follow up. The mean estimated blood loss was 238 mL (140-350) for the two level procedures and 387 mL (278-458) for three levels. The midline surgical scar was 6.27 cm for two levels and 8.25 cm for three level procedures. Complications included two cases of asymptomatic medial penetration of the pedicle border. However, there were no signs of neurological deterioration or fusion failure.

Conclusion : Multi-level, minimally invasive PLIF can be performed effectively using the percutaneous transpedicular screw fixation system. It can be an alternative to the traditional open procedures.

Key Words : Posterior lumbar interbody fusion · Percutaneous · Minimally invasive surgery.

INTRODUCTION

Posterior lumbar interbody fusion (PLIF) is a widely performed surgical procedure for the management of pain and spinal instability resulting from various degenerative lumbar spine diseases where the anterior column support is inadequate^{2,13}. Posterior instrumentation is frequently used to augment interbody fusion, and pedicle screws with rods are commonly employed for this purpose. However, traditional open PLIF for instrument implantation requires a large midline incision and extensive dissection of the paraspinal muscles that can in-

crease the risk for complications both in the short and long term^{5,6,10}. In contrast, minimally invasive lumbar fusion using percutaneous screw fixation significantly diminishes the risk for complications such as iatrogenic soft-tissue damage and postoperative back pain^{1,4}. However, the use of minimally invasive mini-open PLIF using the percutaneous screw fixation system for multi-level degenerative spine disease has not been previously described. The difficulty with rod insertion has been a major technical limitation for the use of percutaneous screw fixation involving multiple levels. The current study describes the surgical technique and feasibility of using the mini-open PLIF procedure for multi-level using percutaneous screw fixation with a vertical axis and detachable screw extender (Fig. 1).

MATERIALS AND METHODS

Patient population

During a period ranging from January 2006 to March 2008,

• Received : December 7, 2010 • Revised : August 9, 2011

• Accepted : November 14, 2011

• Address for reprints : Seok Won Kim, M.D.

Department of Neurosurgery, School of Medicine, Chosun University,
365 Pilmun-daero, Dong-gu, Gwangju 501-717, Korea

Tel : +82-62-220-3126, Fax : +82-62-227-4575

E-mail : ns64902@hanmail.net

Table 1. The low back outcome scale of Greenough and Fraser

Parameter	Finding	Points
Current pain	7 to 10 cm VAS	0
	5 to 6 cm VAS	3
	3 to 4 cm VAS	6
	0 to 2 cm VAS	9
Employment	Unemployed because of back pain	0
	Part time	3
	Full time lighter	6
	Full time original	9
Domestic chores odd jobs	None	0
	A few but not many	3
	Most or all but more slowly normally	6 9
Sport or active social activities	None	0
	Some but much less than before Back to previous level	3 9
Resting	Resting more than half the day	0
	Little rest needed occasional	4
	No need rest	6
Treatment or consultation	More than once per month	0
	About once per month	2
	Rarely	4
	Never	6
Analgesia	Several times each day	0
	Almost every day	2
	Occasionally	4
	Never	6
Sex life	Severely affected impossible	0
	Moderately affected difficult	2
	Mildly affected	4
	Unaffected	6
Sleeping	Severely affected impossible	0
	Moderately affected difficult	1
	Mildly affected	2
	Unaffected	3
Walking	Severely affected impossible	0
	Moderately affected difficult	1
	Mildly affected	2
	Unaffected	3
Sitting	Severely affected impossible	0
	Moderately affected difficult	1
	Mildly affected	2
	Unaffected	3
Travelling	Severely affected impossible	0
	Moderately affected difficult	1
	Mildly affected	2
	Unaffected	3
Dressing	Severely affected impossible	0
	Moderately affected difficult	1
	Mildly affected	2
	Unaffected	3
	Total	75

VAS : visual analog scale



Fig. 1. Percutaneous transpedicular screw fixation system characterized by detachable screw extender system (white arrow : extender holding bar, black arrow : detachable screw extender fixed by extender holding bar).

42 consecutive patients who underwent mini-open PLIF were included in this study. The inclusion criteria were : 1) no previous lumbar surgery, 2) instability accompanying spinal stenosis or spondylolisthesis at more than two levels, 3) followed up for more than 12 months, and 4) no severe osteoporosis (the lowest T-score on DEXA bone mineral density ≥ 3.0). The study group included 14 men and 28 women. The mean follow-up period was 25.3 months (12 months to 43 months) and the mean age was 59.1 (range, 23 to 78 years). The clinical outcome was assessed using the visual analog scale (VAS) and Low Back Outcome Score (LBOS) (Table 1). In addition, the presence of radiological fusion, intra-operative blood loss, the postoperative midline surgical scar and procedure related complications were evaluated.

Surgical technique

All patients underwent surgery in the prone position. Following a midline skin incision, an expandable tubular retractor of appropriate length (X-tube, Medtronic Sofamor Danek, Memphis, TN, USA) was inserted at each level. This was followed by central decompression. On the contralateral side, a foraminal decompression was carefully performed, minimizing the muscle retraction. Not only central decompression but also foraminal decompression could be sufficiently performed through the X-tube, minimizing the damage to facet joint. Next, the percutaneous pedicle screws with a vertical axis and detachable extender (Apollon system[®], Solco medical, Korea) were inserted without additional skin incision. After dissection of the subdermal plane, the percutaneous screws were inserted following retraction of the skin (Fig. 2). At this time, in cases where the alignment was not well fitted, the rod insertion may be obstructed. In these cases, using the detachable screw extender of the Apollon system, the screw extender holder bar should be removed (Fig. 3). Then, by adjusting the trajectory of the screw head, the rod is manually controlled for insertion. Thus, the rod could be inserted with ease. After distraction of the instrumented vertebrae, the interbody peek cages filled with local bone chips harvested from the lamina and facet joints were inserted at each level. Finally, the

screws were compressed into each other to create a lumbar lordosis. In all patients, sitting and walking were allowed two days after surgery. The patients were instructed to wear a thoraco-lumbo-sacral orthosis when out of bed until three months after surgery.

Statistical analysis

Statistical analysis, including mean values and standard deviations, was performed using SAS 6.12 (SAS institute, Inc., Cary, NC, USA). Comparisons between different points in time were performed using the paired Student's t-test. Differences were considered statistically significant at $p < 0.05$.

RESULTS

Forty-two patients were included in this study. There were no cases to be converted into open surgery due to technical difficulty. The number of levels operated on was two levels in 32 patients and three levels in 10 patients. The mean follow-up period was 25.3 months and all patients were followed for a minimum of 12 months. The mean estimated blood loss was 238 mL (140-350) for two levels and 387 mL (278-458) for three levels. There were no cases required a blood transfusion. The mean LBOS prior to surgery was 32.5, which improved to 53.1 at the last follow-up ($p = 0.037$). From a preoperative average of 7.5, the VAS score was decreased significantly to 3.0 at 7 days postoperatively and 2.9 at the final follow-up ($p = 0.015$). At a minimum of 12 months follow-up, all cases appeared to have solid fusions as judged by the presence of a trabecular bony bridge and less than 5° on dynamic flexion-extension views. The postoperative midline surgical scars were a mean of 6.27 cm for two levels and 8.25 cm for three levels. Complications included two cases of medial penetration of the pedicle border without neurological deficits and one case with a deep wound infection. However, there were no signs of neurological aggravation or fusion failure at the final follow up. Moreover, there were no neurological sequelae as a result of misplaced pedicle screws (Fig. 4).

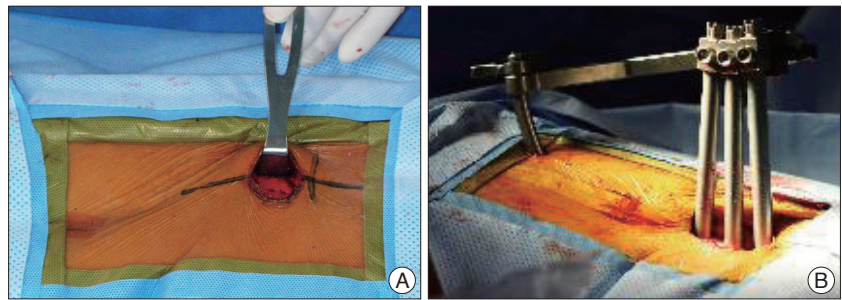


Fig. 2. Percutaneous transpedicular screw inserted with same skin incision line after full paraspinal subdermal dissection. A : Paraspinal subdermal dissection. B : Percutaneous transpedicular screw insertion using same skin incision.

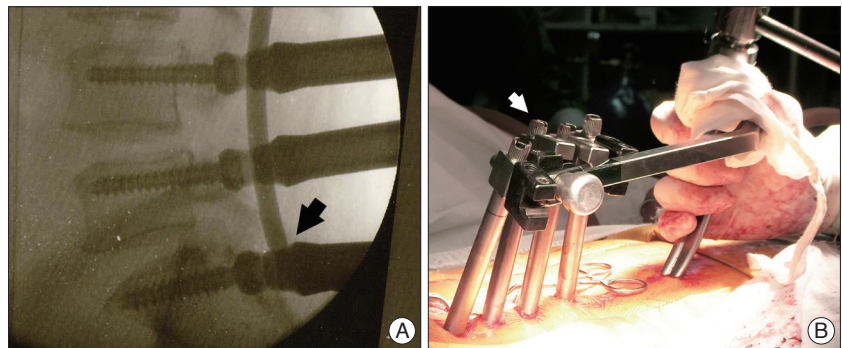


Fig. 3. Intraoperative photographs of multi-level percutaneous transpedicular screwing. A : In multi-level screwing, the rod insertion sometimes blocked due to misalignment (black arrow). B : In such cases, the extender holder bar can be removed (white arrow).

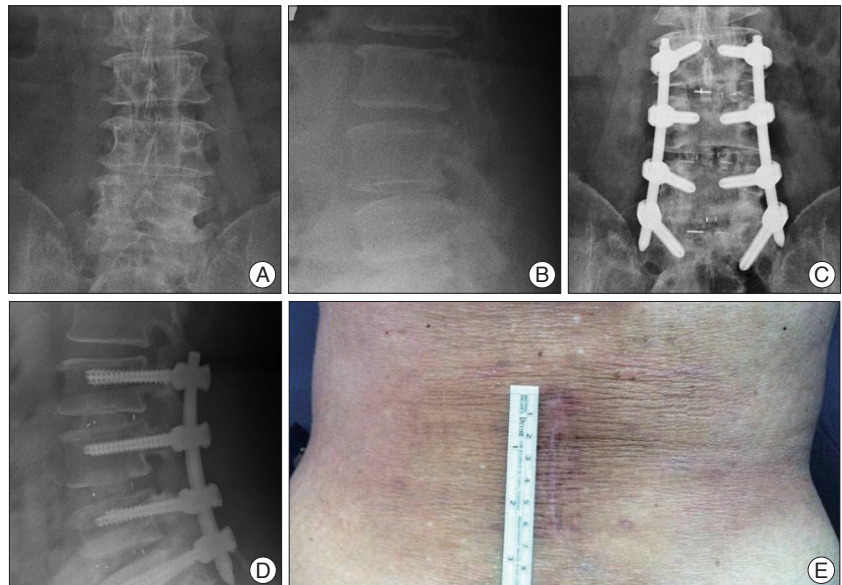


Fig. 4. A case of 3 level mini-open PLIF with percutaneous transpedicular screw fixation. A and B : Preoperative simple radiographs. C and D : Simple lumbar radiographs show bony trabeculae beyond the cages at 15 months after surgery. E : The operation was performed by only 8 cm skin incision. PLIF : posterior lumbar interbody fusion.

DISCUSSION

The PLIF has been associated with the improvement of the fusion rate while restoring disc height and maintaining vertebral alignment³. Since the anterior and middle spinal columns

support 80% of the spinal load, placing the bone graft in this load-bearing position makes it subject to compressive forces that enhance bone fusion as predicted by Wolff's law. In addition, the vertebral body represents 90% of the osseous surface area and receives a more generous vascular supply than the posterolateral elements, which further improve the fusion potential⁸). However, despite the advantages of the satisfactory fusion rate, PLIF procedure itself has some drawbacks. It is known that postoperative back pain is caused by muscle injury during surgery and is directly related to the operation time and external compression force from the retractor⁴). Due to the massive skin incision, the risk for intraoperative blood loss and postoperative back pain are increased. In addition, for the conventional midline approach for screw fixation for multiple levels, forceful retraction of the paraspinal muscles is required to achieve the proper lateral-to-medial screw trajectory because of coronal plane angle of pedicle. Subsequent prolonged wide retraction may result in denervation of the paraspinal musculature⁹). Moreover, the procedure can potentially injure the medial branches of the dorsal ramus at adjacent levels and at the level of fusion; this is because these branches are relatively fixed as they run beneath the fibro-osseous mamilloaccessory ligament^{2,12}). On the contrary, percutaneous pedicle screw fixation permits a safe application while preserving soft tissues without relevant blood loss and persisting sequelae, such as muscular denervation, atrophy, and pain^{7,11}). Percutaneous screws can be inserted in the appropriate direction without forceful retraction of the muscles^{1,4}). Due to the technical problems of rod insertion however, the percutaneous transpedicular screw procedure is usually performed at a single level. With multiple levels, percutaneous screw fixation is difficult to perform.

The goal of minimally invasive spinal surgery is to achieve the satisfactory results as comparable open procedure with reduced iatrogenic injury. In the current study, a minimally invasive mini-open PLIF was performed at multiple levels in 42 patients using a vertical axis and detachable screw system; the results were satisfactory. Surgical devices used in percutaneous pedicle screw fixation are classified into two major types depending on the rod insertion method. The first type is the geometrical coordinating device called the 'Sextant' (Medtronic) and 'Apollon' (Solco) that facilitates pedicle screw fixation by following the circular margin of the arc during rod insertion. The other device is the open screw head type used for direct insertion of the rod (J&J's 'Viper system' and 'Path-Finder system'). For the multi-level percutaneous pedicle screwing, the initial alignment of the vertebroplasty needle is essential. Despite the use of a ruler guide, the direction of a needle may be altered during passage through the pedicle. The rod cannot be easily inserted, in case of initial misalignment of screws. However, the vertical axis and detachable screw extender system has made this more feasible. If surgeons become accustomed to the percutaneous screw fixation, the alignment with ruler guide would not be needed. Under surgical observation, the alignment of the vertebroplasty needle

should be well adjusted. Following this, with the alignment of the needle consistently maintained a needle at all segments was inserted to the desired depth. However, if the rod insertion is obstructed, the screw extender holder bar should be removed. Misalignment of the screw head leads to the difficulty of rod insertion and the primary cause of this may be the difference in each of its depth and failing to keep them in perfect alignment. Removing the extensor bar offers possibility of controlling the angle of the screw head due to its polyaxial characteristics. It enables controlling the axis of rod insertion which facilitates the process of it additionally, and this is what we supplemented to this content. Then, the screw extender could be detached. Following a re-adjustment of the screw head alignment, the rod could be manually inserted with ease. The technical limitations of multi-level posterior pedicle screw fixation by percutaneous techniques that were present with previous sextant systems have been overcome with this method. Although there are potential benefits with the minimally invasive mini-open procedure, the technique also has some of its own drawbacks and limitations. There is a learning curve that must be achieved before the technical skills are acceptable. However, the minimally invasive mini-open PLIF used for multiple levels can provide many potential advantages compared to the conventional PLIF, although technically demanding.

CONCLUSION

The vertical axis and detachable screw extender system for multi-level interbody fusion makes rod manipulation easier to perform. This technique can reduce the size of the midline skin incision as well as the risks for iatrogenic muscle injury. Accordingly, a prompt recovery and a good clinical outcome can be expected even in cases with multiple levels.

• Acknowledgements

This study was supported by grant from Chosun University research institute of medical science (2010). This study was supported by grant from Chosun University 2010.

References

1. Anand N, Baron EM, Thaiyananthan G, Khalsa K, Goldstein TB : Minimally invasive multilevel percutaneous correction and fusion for adult lumbar degenerative scoliosis : a technique and feasibility study. *J Spinal Disord Tech* 21 : 459-467, 2008
2. Bogduk N, Wilson AS, Tynan W : The human lumbar dorsal rami. *J Anat* 134 : 383-397, 1982
3. Greenough CG, Fraser RD : Assessment of outcome in patients with low-back pain. *Spine (Phila Pa 1976)* 17 : 36-41, 1992
4. Kawaguchi Y, Matsui H, Tsuji H : Back muscle injury after posterior lumbar spine surgery. A histologic and enzymatic analysis. *Spine (Phila Pa 1976)* 21 : 941-944, 1996
5. Khoo LT, Palmer S, Laich DT, Fessler RG : Minimally invasive percutaneous posterior lumbar interbody fusion. *Neurosurgery* 51 : S166-S181, 2002
6. Kim KH, Park JY, Chin DK : Fusion criteria for posterior lumbar inter-

- body fusion with intervertebral cages : The significance of traction spur. *J Korean Neurosurg Soc* **46** : 328-332, 2009
7. Lowery GL, Kulkarni SS : Posterior percutaneous spine instrumentation. *Eur Spine J* **9 Suppl 1** : S126-S130, 2000
 8. Mummaneni PV, Haid RW, Rodts GE : Lumbar interbody fusion : state-of-the-art technical advances. Invited submission from the Joint Section Meeting on Disorders of the Spine and Peripheral Nerves, March 2004. *J Neurosurg Spine* **1** : 24-30, 2004
 9. Ota M, Neo M, Fujibayashi S, Takemoto M, Nakamura T : Advantages of the paraspinous muscle splitting approach in comparison with conventional midline approach for s1 pedicle screw placement. *Spine (Phila Pa 1976)* **35** : E452-E457, 2010
 10. Wang JC, Mummaneni PV, Haid RW : Current treatment strategies for the painful lumbar motion segment : posterolateral fusion versus interbody fusion. *Spine (Phila Pa 1976)* **30** : S33-S43, 2005
 11. Wang MY, Anderson DG, Poelstra KA, Ludwig SC : Minimally invasive posterior fixation. *Neurosurgery* **63** : 197-203, 2008
 12. Wetzel FT, LaRocca H : The failed posterior lumbar interbody fusion. *Spine (Phila Pa 1976)* **16** : 839-845, 1991
 13. Yashiro K, Homma T, Hokari Y, Katsumi Y, Okumura H, Hirano A : The Steffee variable screw placement system using different methods of bone grafting. *Spine (Phila Pa 1976)* **16** : 1329-1334, 1991