

## 유두 유륜 복합체 주변의 미용적 유방 재건을 위한 주머니끈 봉합의 유용성

송정윤 · 진웅식 · 장 학 · 민경원

서울대학교 의과대학 성형외과학교실

### Usefulness of the Purse-string Suture Technique for Aesthetic Breast Reconstruction Surrounding the Nipple-areolar Complex

Jung Yoon Song, M.D., Ung Sik Jin, M.D., Hak Chang, M.D.,  
Kyung Won Minn, M.D.

Department of Plastic and Reconstructive Surgery, Seoul  
National University Collage of Medicine, Seoul, Korea

**Purpose:** In cases of breast reconstruction with a free transverse rectus abdominis musculocutaneous (TRAM) flap after skin-sparing mastectomy with nipple-areolar complex (NAC) removal, the flat contour of the flap's skin paddle can easily look unnatural and dissatisfying. Reconstructed NAC on the flap surface lacks the elevated contour that the normal areola possesses, resulting in an unnatural final result. Therefore, we would like to introduce a novel method to improve this problem and report the satisfactory results we obtained.

**Methods:** Operations were conducted on 19 patients who underwent immediate breast reconstruction with a free TRAM flap and skin-sparing mastectomy from January 2009 to January 2010, with a mean follow-up of nine months. While the TRAM free flap was being inset, a purse-string suture was carried out on the dermal layer of skin flap to create a slight protrusion with Gore-Tex<sup>®</sup> sutures.

**Results:** The elevated mound surrounding the NAC was well maintained for an average follow-up period of nine months. Nipple projection was also well maintained. There was no complaint about breast contour or nipple height reduction. In addition, there was no reported incidence of other complications.

**Conclusion:** The purse-string suture technique presents a more natural breast silhouette around the NAC and helps to maintain nipple projection. Furthermore, it does not require any supplementary incisions or complicated

skills. There has been no report of additional complications using this technique.

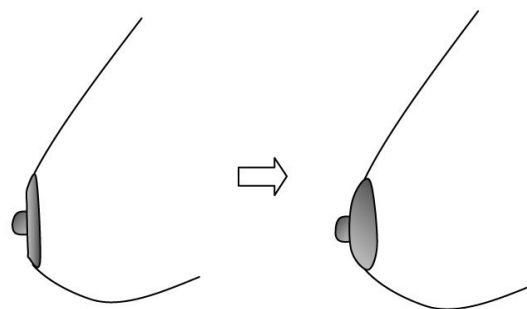
**Key Words:** Purse string suture, Nipple-areolar complex reconstruction, Breast reconstruction

## I. INTRODUCTION

The nipple-areolar complex (NAC) is the most projected portion, and therefore is the most highlighted part, of the whole breast. Thus, the breast contour surrounding the NAC significantly enhances its aesthetic outcome.<sup>1</sup> After breast reconstruction with a TRAM flap in post-skin-sparing mastectomy patients, the contour of the breast at the flap inset site is relatively flat and the natural round breast contour is lost. This is especially apparent from the lateral views of the reconstructed breast (Fig. 1). Furthermore, the flat mound affects nipple projection, so that the nipple can be seen to be flatter. To solve this problem, the authors devised a new idea to improve three-dimensional shape of the periareolar area and to achieve a more natural look by using the purse-string suture technique.

## II. IDEAS AND INNOVATIONS

From January 2009 to January 2010, 19 patients received



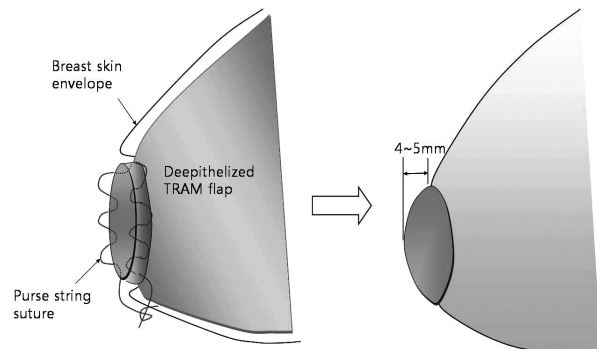
**Fig. 1.** (Left) Relatively flat skin of the inset TRAM flap can disrupt the natural breast contour. (Right) The skin around the NAC must protrude slightly to achieve a natural contour.

Received April 26, 2011

Revised July 25, 2011

Accepted July 28, 2011

**Address Correspondence:** Kyung Won Minn, M.D., Ph.D., Department of Plastic and Reconstructive Surgery, Seoul National University Hospital, 101 daehak-ro, Jongno-gu, Seoul 110-744, Korea. Tel: 02) 2072-3642/Fax: 02) 2072-3680/E-mail: minnkw@snu.ac.kr

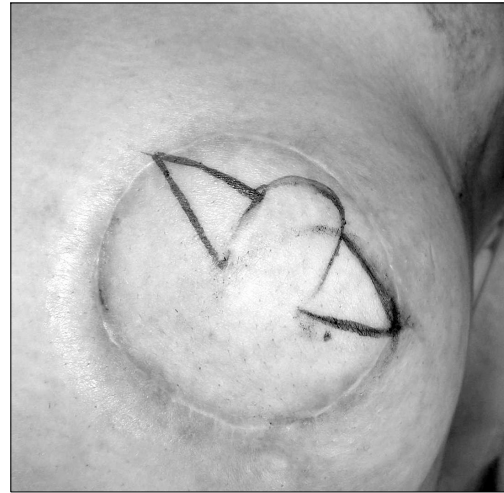

**Fig. 2.** (Left) A purse-string suture was done at the dermis of the flap skin margin with Gore-Tex<sup>®</sup> CV-3 sutures. (Right) Skin flap was protruded about 4~5mm.

skin-sparing mastectomy that included NAC resection. This technique is indicated in patients who have undergone skin-sparing mastectomy with excision of the NAC complex and surrounding skin. Flap inset was performed after de-epithelization of the superfluous skin. The diameter of the skin paddle area was a little longer than the resected breast skin, considering the reduction of diameter after purse-string suturing. During the inset, purse-string suturing was carried out on the dermal layer of the skin paddle margin to create a slight protrusion (4~5 mm) of the skin flap with Gore-Tex<sup>®</sup> CV-3 sutures (W. L. Gore & Associates, Inc., Flagstaff, Arizona; expanded polytetrafluoroethylene [ePTFE], 0.3 mm diameter) (Fig. 2). The protruding skin paddle was sutured with an envelope made out of the remained skin aligning with the edge. Technically, if the purse-string suture is too tight, a groove may form, and as a result, an unnatural contour will be produced. Thus, it is essential to suture with the appropriate strength and tension. Overprojection is not necessary, so sutures should be done with the appropriate tension when the lateral and oblique views offer the most natural contour intraoperatively.

After an average of six months, NAC reconstruction with the C-V flap method was carried out, and lastly, tattooing was done three months after NAC reconstruction. A C-V flap is used for NAC reconstruction, but if the skin flap is too small, the purse-string suture may break during elevation of the V flap. Therefore, we measured the diameter of the contralateral nipple and designed the C-V flap on the affected side, and applied this technique only in cases where the inset skin flap length was longer than the total length of the C-V flap (Fig. 3).

The elevated mound surrounding the NAC was well maintained for an average follow-up period of 12.2



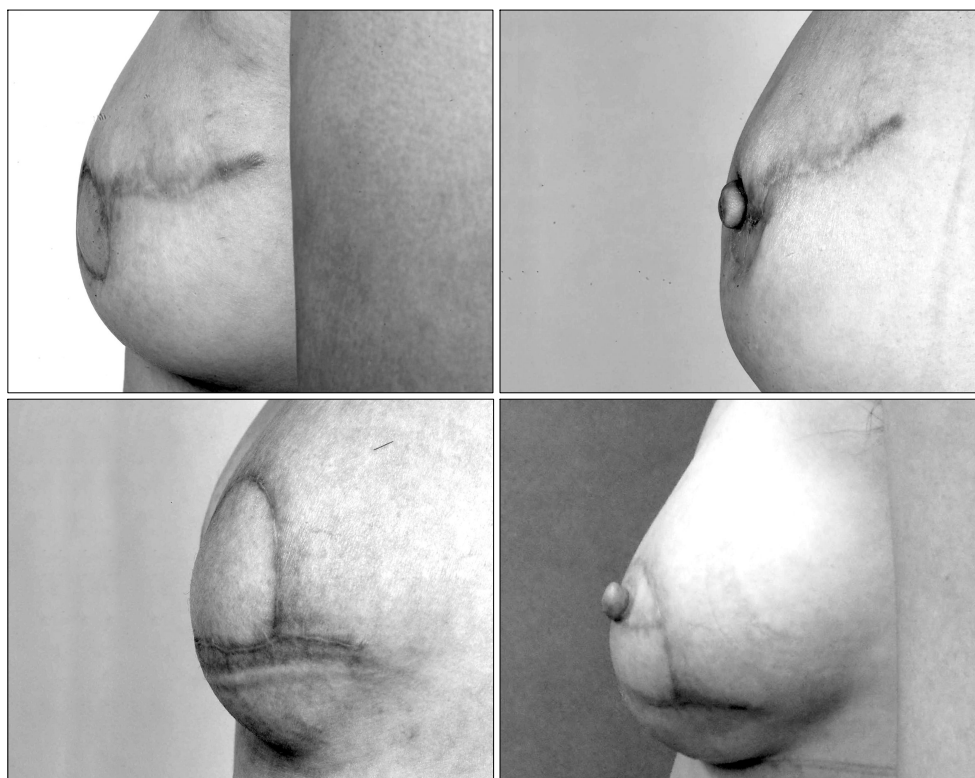**Fig. 3.** Intraoperative design: inset skin flap length was longer than the total length of the C-V flap.

months. Nipple projection was also well maintained (Fig. 4). There was no complaint about breast contour or nipple height reduction. Furthermore, there was no reported incidence of other complications such as wound infection, NAC skin loss, or suture material exposure.

### III. DISCUSSION

A flat contour of the breast surrounding the NAC disturbs aesthetic breast satisfaction. After skin-sparing mastectomy including NAC, the skin paddle must protrude more than any other area. However, a simple suture with a skin paddle and envelope can hardly form an elevated mound. A purse-string suture during inset was able to form the mound contour easily and consecutively. Moreover, its protrusion was well maintained after the nipple formation operation. This was because the scar contraction force relating to nipple formation does not affect protrusion. The authors used a permanent, nonabsorbable Gore-Tex<sup>®</sup> suture on the periareolar skin paddle area to attain the projection.<sup>2</sup>

Flat skin paddle appearance also affects nipple projection, and a protruded periareolar mound can help nipple projection. Eng<sup>3</sup> and Weinfeld<sup>4</sup> devised nipple areolar reconstruction techniques using purse-string sutures, but the simultaneous centrifugal wound contraction force played a key role in overall projection loss.<sup>5</sup> Scar contraction force relating to protruded mound formation with a circular purse-string suture does not affect nipple projection because of the time difference. Furthermore, a well-maintained mound contributes greatly to nipple projection.



**Fig. 4.** (Above, left) Postoperative photo after breast reconstruction with a TRAM free flap on a 32-year-old woman where the proposed technique was not used. Flat flap brake periareolar contour. (Above, right) Postoperative photo after nipple reconstruction using a C-V flap in the same patient. (Below, left) A 43-year old woman's postoperative photo after using the purse-string suture technique four months later. The breast contour is maintained. (Below, right) Postoperative view six months after the nipple reconstruction operation.

In breast reconstruction after skin-sparing mastectomy including periareolar resection, more favorable results that carry less surgical stigma compared to previous conventional methods can now be achieved using this concept. The technique requires no supplementary incisions or complicated skills, so surgeons can apply this method easily.

**REFERENCES**

1. Goh SC, Martin NA, Pandya AN, Cutress RI: Patient satisfaction following nipple-areolar complex reconstruc-

tion and tattooing. *J Plast Reconstr Aesthet Surg* 64: 360, 2011  
 2. Hammond DC, Khuthaila DK, Kim J: The interlocking Gore-Tex suture for control of areolar diameter and shape. *Plast Reconstr Surg* 119: 804, 2007  
 3. Eng JS: Bell flap nipple reconstruction-a new wrinkle. *Ann Plast Surg* 36: 485, 1996  
 4. Weinfeld AB, Somia N, Codner MA: Purse-string nipple areolar reconstruction. *Ann Plast Surg* 61: 364, 2008  
 5. Shestak KC, Gabriel A, Landecker A, Peters S, Shestak A, Kim J: Assessment of long-term nipple projection: a comparison of three techniques. *Plast Reconstr Surg* 110: 780, 2001