

## 이차 구순비 변형 환자에서 Spacer Graft를 이용한 콧방울뒤당김 (retracted ala)의 교정

한규석 · 최현곤 · 신동혁 · 김순흠 · 황은아 · 엄기일

건국대학교 의학전문대학원 성형외과학교실

### Correction of Retracted Ala Using Spacer Graft in Secondary Cleft Lip and Nose Deformity

Kyu Seok Han, M.D., Hyun Gon Choi, M.D.,  
Dong Hyeok Shin, M.D., Soon Heum Kim, M.D.,  
Eun A Hwang, M.D., Ki Il Uhm, M.D., F.A.C.S.

Department of Plastic and Reconstructive Surgery, School of Medicine, Konkuk University, Seoul, Korea

**Purpose:** In patients with unilateral cleft lip and nose deformity, alar retraction is commonly seen on the non-cleft side after cleft side is corrected. Spacer graft was used to drag down the inferior border of the alar cartilage of the non-cleft side so as to match the cleft side. By performing spacer graft and septal extension graft together, symmetry and cosmetic improvements were achieved.

**Methods:** Seven unilateral cleft lip and nose deformity patients underwent surgery for alar retraction correction. The median age was 24 years (ranged from 15 to 34 years), and the median follow-up period was 7.4 months (ranged from 6 to 12 months). The perpendicular length from the longitudinal axis of the nostril to the alar rim, the nasolabial angle and the ala-labial angle were measured in the lateral view photo. The longest perpendicular length from the cephalic border of the alar rim to the parallel line of the alar base was measured in the frontal view photo.

**Results:** Improvement in alar retraction was seen after the surgery. There were no specific complications during the follow-up and the symmetry of both nostrils was satisfactory. No increase in the nasolabial angle or exposure of the nostrils was seen after the tip projection via tip plasty.

**Conclusion:** The fundamental factor in correcting alar retraction with secondary cleft lip and nose deformity is

repositioning the alar rim with spacer graft, which seems to be more physiologic than other methods. The method combining spacer graft with septal extension graft will bring symmetry as well as more cosmetic improvement in correction of alar retraction with secondary cleft lip and nose deformity.

**Key Words:** Secondary cleft lip and nose deformity, Alar retraction, Spacer graft, Septal extension graft

### I. INTRODUCTION

As correction of unilateral cleft lip and nose deformity is performed, alar retraction, presented with nostril exposure of the non-cleft side that is set relatively higher than the cleft side, is often seen. The major causes of alar retraction in Asians are skin-growth insufficiency on the alar cartilage or the alar rim, or cephalic malpositioning of the lateral portion of the alar cartilage.<sup>1</sup> Unlike patients without cleft lip and nose deformity, however, the alar retraction phenomenon on the non-cleft side, which is seen in secondary cleft lip and nose deformity, appears to be due to the malpositioning of the alar cartilage on the cleft side to the caudal side because of drooping. In this case, if the cleft side is corrected to match the non-cleft side, the alar retraction on the non-cleft side would aggravate (Fig. 1).

Although, diverse alar retraction correction methods that had shown good outcomes have been introduced, it is thought that the natural alar cartilage should be saved to obtain a more natural-looking and stable alar rim. Thus, spacer graft is performed to achieve symmetry by repositioning the non-cleft side of the alar cartilage to the caudal side.<sup>2</sup>

In addition, since a typical Asian with cleft lip and nose deformity has shortage of projection of the nasal tip, has supratip deformity that displaces the nasal tip toward the cephalic side, and has short nose with a large nasolabial angle and a short vertical length of the nasal dorsum, tip plasty with septal extension graft was done in all the patients as the secondary cleft lip and nose

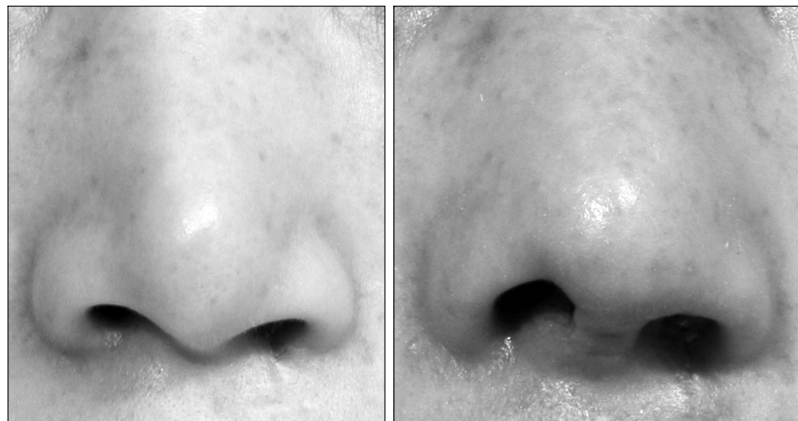Received November 1, 2010

Revised April 28, 2011

Accepted May 23, 2011

**Address Correspondence:** Ki Il Uhm, M.D., F.A.C.S., Department of Plastic and Reconstructive Surgery, School of Medicine, Konkuk University, 4-12 Hwayang-dong, Gwangjin-gu, Seoul 143-729, Korea. Tel: (02) 2030-5235/Fax: (02) 2030-5249/E-mail: kiumps@hanmail.net

\* 본 논문은 2009년 제6회 대한성형외과학회 코성형연구회와 제67차 대한성형외과학회 추계학술대회에서 구연 발표되었음.



**Fig. 1.** Photographs of problematic patient with secondary cleft lip and nose deformity on left side. (Left) Preoperative photograph. (Right) At 4 weeks after surgery, alar retraction was aggravated on right side.

**Table I.** Summary of Patients

	Sex/ Age	Previous secondary cheiloplasty & CLN* correction	Type of secondary CLN* deformity	Spacer graft	Septal extension graft	Augmentation rhinoplasty	Tip plasty
1	F/28	O	Unilateral (left)	Bilateral with conchal cartilage	O	O (silicone)	Dermis onlay
2	M/20	O	Unilateral (right)	Bilateral with conchal cartilage	O	O (silicone)	Conchal cartilage onlay
3	F/28	O	Unilateral (right)	Right with conchal cartilage	O	O (Alloderm)	X
4	F/19	O	Unilateral (right)	Bilateral with conchal cartilage	O	O (silicone)	X
5	F/15	O	Unilateral (left)	Right with septal cartilage	O	X	Dermis and septal cartilage
6	F/34	O	Unilateral (left)	Right with conchal cartilage	O	O (silicone)	Dermis onlay
7	M/24	O	Unilateral (left)	Bilateral with conchal cartilage	O	O (silicone)	Dermis onlay

\*CLN, cleft lip and nose

deformity correction was performed.

Since the method of using both spacer graft and septal extension graft not only achieved symmetry in a patient with both secondary cleft lip and nose deformity and alar retraction, but also yielded aesthetically satisfying outcomes, these results are reported in this paper.

## II. MATERIALS AND METHODS

### A. Patients

The study was carried out with seven patients who had unilateral cleft lip and nose deformity with alar retraction and who visited the out-patient department of the authors' hospital from October, 2008 to April,

2009. Alar retraction was defined by a distance longer than 2 mm from the long axis of the nostril to the superior point of the alar rim on the lateral profile.<sup>3</sup> Among the patients, there was one with potential alar retraction that was confirmed by lifting the nostril with a stick before surgery. The average age of the patients was 24 years (range 15 to 34 years), and all of them had stopped growing. This was assessed before each operation with a wrist x-ray, which verified that none of the growth plates was open. All seven patients underwent cheiloplasty but not rhinoplasty. The average period of their postoperative follow-up was 7.4 months (ranged from 6 to 12 months) after the surgery (Table I).

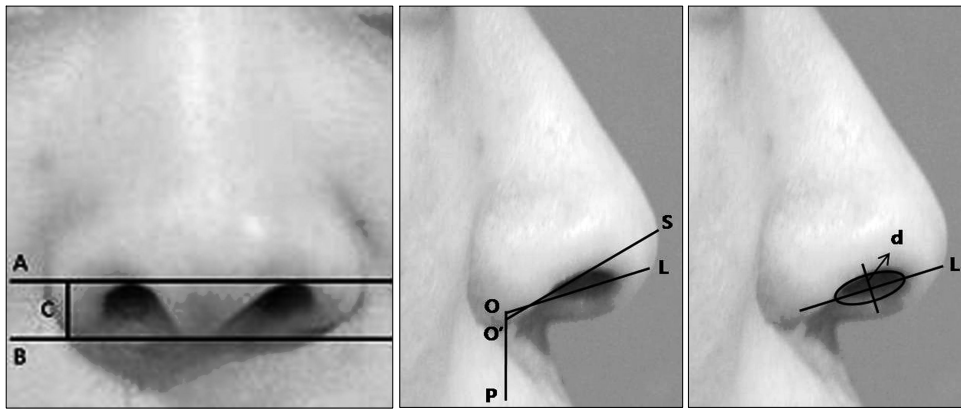
**B. Assessment Method**

From the photos taken, the perpendicular distance (d) from the long-axis of the nostril (L) to the superior alar rim (d), the nasolabial angle<sup>4</sup> or the ala-labial angle were measured from the lateral view; and, the longest perpendicular distance (C) from the horizontal line of the alar base to the cephalic side of the alar rim was measured on the frontal view (Fig. 2). All the photos were taken by only one operator. Adobe Photoshop CS3 was used to enlarge the photos upto their actual size. Then, the same single operator repeated the measurement five times recording while each result to one decimal place (Table II).

**C. Surgical Technique**

All the operations were performed under general anesthesia. Secondary cheiloplasty was performed for upper lip deformity, correction of alar base deformity was done on the cleft side, and rhinoplasty followed. The

rhinoplasty was achieved through transcolumella and marginal incisions to the plane above the cartilage to elevate the skin flap. As the skin flap was elevated, feasible and wide dissection was done to prevent the development of tension. The anterior septal angle was exposed for harvesting of the septal cartilage for the graft. Dissection was extensively performed below the perichondrium to expose the septal cartilage. Approximately 1 cm of the dorsal and caudal sides of the cartilage was left intact and the rest of the septal cartilage was harvested for septal extension graft (Fig. 3). The septal cartilage or the conchal cartilage was used as the autogenous cartilage in the graft. Since a substantial amount of the septal cartilage was used for the septal extension graft, there was a shortage of the remaining cartilage, and thus, the conchal cartilage was used. Then interdomal or transdomal suture was performed with a 6-0 non-absorbable suture material onto the cartilage of the septal extension graft to elevate the projection of the



**Fig. 2.** Method of alar retraction measurement. (Left) C, the longest vertical distance between alar base (B) and superior point of alar rim (A). (Center)  $\angle$ LOP, nasolabial angle; SO'P, ala-labial angle; L, long axis of nostril; S, slant of ala rim. (Right) d, the longest vertical distance from long axis of nostril (L) to superior alar rim.

**Table II.** Clinical Datas for Patients

Case No.	C (mm)		d (mm)		NL/AL (°)	
	Pre-op	6 months	Pre-op	6 months	Pre-op	6 months
1	2.6	1.5	5.6	4.7	115/121	109/110
2	2.2	1.3	9.1	5.2	113/120	105/113
3	2.7	1.5	5.1	3.8	102/124	105/117
4	2.3	1.3	3.0	1.7	118/115	107/104
5	1.2	1.7	3.7	5.1	106/113	98/107
6	2.5	1.7	5.4	5.2	115/119	103/113
7	2.5	1.6	5.5	3.6	108/114	102/105

NL, nasolabial angle; AL, ala-labial angle.

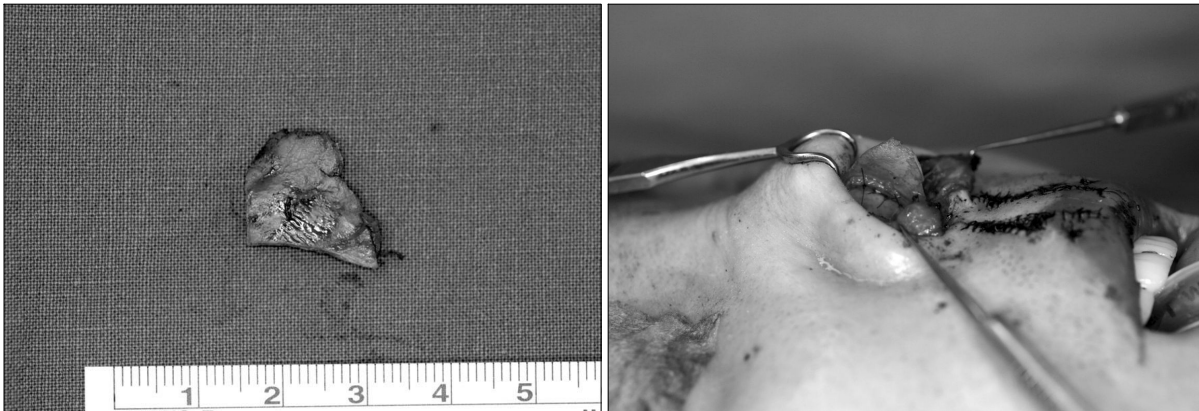


Fig. 3. Intraoperative photographs of septal extension graft.

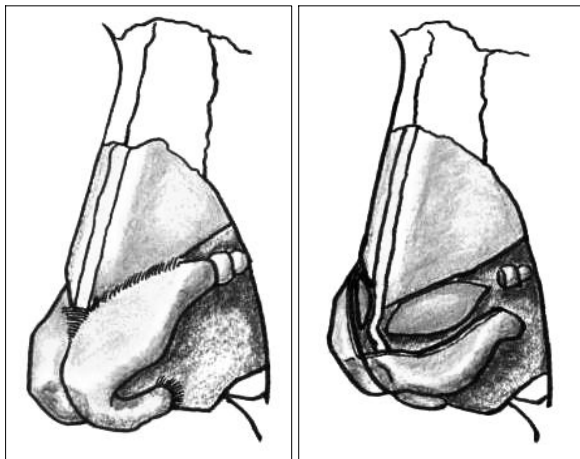


Fig. 4. Schematic illustration of spacer graft between the alar and upper lateral cartilage.

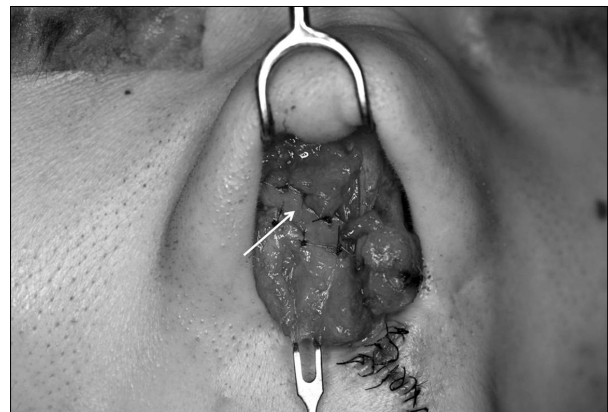

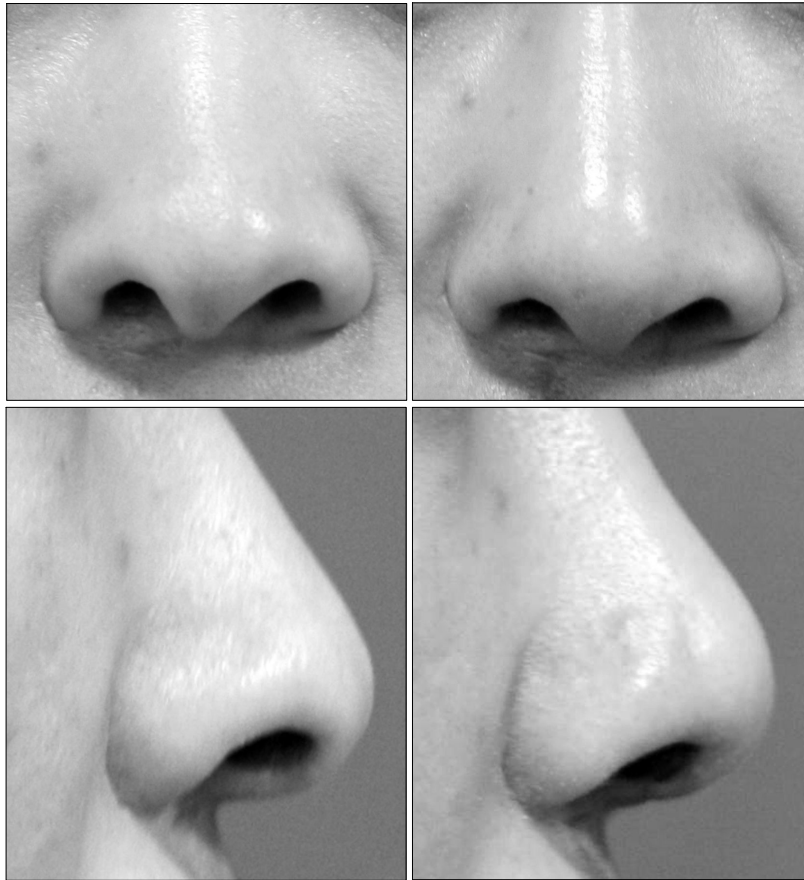Fig. 5. Intraoperative photo. Fixation of the spacer graft between the alar and upper lateral cartilage. It shows sufficient mobility of the alar cartilage.

nasal tip and to achieve symmetry of the nostrils by repositioning the deformed lower lateral cartilage of the cleft side. Despite these procedures, the parts where alar traction remained or was aggravated were corrected with spacer graft. After the extensive skin flap was elevated, the alar cartilage was pulled toward the caudal side and the fibrous connection between the upper lateral cartilage and the lower lateral cartilage was meticulously dissected for effective correction of the alar retraction. Even after the complete detachment of the upper lateral cartilage was achieved by separating the space between the upper lateral cartilage and the alar cartilage from the medial to the lateral side, the dissection was extended to separate the soft tissue, which connects the alar cartilage and the piriform abutment, from the sesamoid cartilage. Through this process of dissection, the alar cartilage was completely separated from the upper lateral cartilage, the septal cartilage, the piriform aperture

and the accessory cartilage, and became freely movable. The alar cartilage was moved to the caudal side and located near the caudal side of the septal extension graft. Then an approximately 5 × 10 mm portion of the elliptical autogenous cartilage was grafted to the empty space between the upper lateral cartilage and the alar cartilage. The grafted cartilage was fixed with a 6-0 non-absorbable suture material to the alar cartilage and the upper lateral cartilage (Fig. 4, 5). When it was needed, onlay graft was also carried out using the dermis from the sacral area or leftover cartilage to project the nasal tip.

### III. RESULTS

The condition of the alar retraction before the surgery was compared with its condition after the surgery using the same photo measurement method that was earlier used. It was found that the alar retraction improved



**Fig. 6.** Case 3. A 28-year-old female patient with secondary cleft lip and nose deformity on right side. Septal extension graft with septal cartilage and spacer graft between right upper lateral and alar cartilage with conchal cartilage was performed. Secondary cheiloplasty and augmentation rhinoplasty with Alloderm® was performed concomitantly. (Left) Pre-operative photo. (Right) 6 months after surgery.

(Table II). During the post-operative follow-up, buckling<sup>5</sup> of the spacer graft, or bilateral repositioning of the alar cartilage, did not occur. Both sides of the nostrils showed satisfactory symmetry without major complications. Even after the protrusion of the nasal tip augmentation through rhinoplasty or tip plasty, no increase in the ala-labial angle and no exposure of the nostril were observed.

#### Case 3

A 28-year-old female patient who had a two-time history of cheiloplasty due to secondary cleft lip and nose deformity was presented to the authors with alar retraction. Cheiloplasty and correction of the cleft lip and nose deformity were performed simultaneously. Septal extension graft was performed with the septal cartilage during rhinoplasty. Augmentation rhinoplasty using Alloderm® and spacer graft on the right side using the conchal cartilage were carried out. During the post-operative follow-up, symmetry of the nostrils and improvement of the alar retraction were observed (Fig. 6).

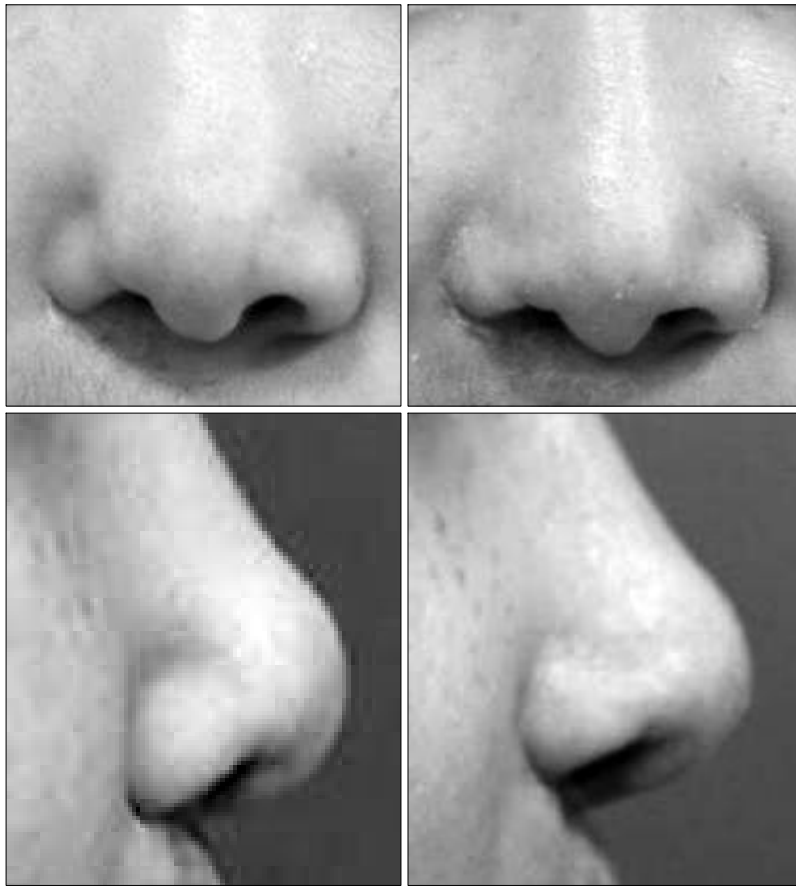
#### Case 4

A 19-year-old female patient who had a two-time history of cheiloplasty due to secondary cleft lip and nose deformity

was presented to the authors with alar retraction. Cheiloplasty and correction of the cleft lip and nose deformity were performed simultaneously. Septal extension graft was performed with the nasal septal cartilage during rhinoplasty, and augmentation rhinoplasty with a silicone implant, and bilateral spacer graft were performed with the conchal cartilage. Because of the shortage of the projection of the nasal tip, onlay graft was carried out for the remaining cartilage. During the post-operative follow-up, the symmetry of the nares was preserved. The highest point of the nasal tip, which showed cephalic malpositioning in the preoperative photo with a lateral view, moved toward the caudal side after the operation. A decrease in the ala-labial angle was also observed (Fig. 7).

## IV. DISCUSSION

To correct a short nose, the columella and the nasal dorsum must be elongated perpendicularly and vertically, respectively, to lengthen the outer lining (skin, subcutaneous tissue), the skeletal framework, and the inner lining (the mucosa).<sup>6,7</sup> Similar to correction of a short nose, augmentation rhinoplasty and tip plasty to project the nasal tip also require the forementioned



**Fig. 7.** Case 4. A 19-year-old female patient with secondary cleft lip and nose deformity on right side. Septal extension graft with septal cartilage and spacer graft between bilateral upper lateral and alar cartilage with conchal cartilage was performed. Secondary cheiloplasty and augmentation rhinoplasty with silicone was performed concomitantly. (Left) Pre-operative photo. (Right) 6 months after surgery.

factors. To extend the outer lining, redraping through extensive dissection must be performed. In some circumstances, an additional full-thickness skin graft on the columella may be needed. The cantilever bone, cartilage graft, strut graft and more are required to extend the skeletal framework, but septal extension graft,<sup>8</sup> batten graft, spreader graft are mainly used. A skin graft or a composite graft on the internal nares can be used to extend the inner lining. The extension can also be made by dissecting the fibrous connective tissue between the upper and lower lateral cartilages.

When the correction of the short nose was performed with the aforementioned method, the extension and projection of the columella and the nasal tip were formed well, but the outer part of the ala showed relatively aggravated cephalic retraction. To solve this problem, the fibrous connective tissue between the upper lateral and the lower lateral cartilage was dissected, sesamoid cartilage around the piriform abutment was fully dissected. This dissection made it possible for lower lateral cartilage to be pulled freely toward the caudal side to sufficiently extend the inner lining.<sup>5</sup> Additional dissection of the mucosa below the cartilage when dissecting the connec-

tive tissue between the upper lateral and the lower lateral cartilage had been suggested to increase the mobility.<sup>5</sup> Since this process increases the risk of the perforation of the nasal mucosa and can cause problems with survival and engraftment of the grafted cartilages, however, it was not performed. Moreover, sufficient dissection of the lateral portion of the alar cartilage alone could already produce enough mobility. In addition, to prevent the inner lining that was pulled caudally from returning to its and to lengthen the skeleton around the alar area, the alar retraction was corrected with cartilage graft between the upper and lower lateral cartilage.<sup>2</sup> The septal cartilage was used for the graft. The conchal cartilage can produce a more natural-looking result, however, along with the alar cartilage, due to its appropriate curvature, and it is also readily manipulable during the surgery.

Alar retraction can be classified into three categories: alar retraction only, alar retraction with short nose, and alar retraction with a potential short nose that is recognized only after augmentation rhinoplasty. In the case of a potential short nose, the alar retraction is trivial pre-operatively but can aggravate post-operatively, and

the likelihood of the aggravation is difficult to predict. Therefore, a proper decision is required during the surgery. Alar rim graft<sup>9</sup> and alar contour graft<sup>10</sup> can be used to correct the retracted ala. Alar rim graft is less invasive but the site of the grafting may not be precise. On the other hand, in alar contour graft, the site of the grafting may be more precise due to the use of the open approach method. It is difficult to maintain the site of the grafting in both methods, though. Besides these two methods, composite graft<sup>11</sup> or V-Y advancement flap<sup>9</sup> could be considered for lengthening the inner lining. Composite graft has been long used to correct the alar retraction using a composite tissue composed of conchal cartilage and skin, or septal cartilage and nasal mucosa. It has been blamed, however, for nodule formation on the graft, buckling, atrophy, etc. V-Y advancement flap is a unique method that has an advantage in its ability to correct a wide range of cases of alar retraction without using a graft. Prediction of the postoperative outcome is uncertain, however, and it is difficult to come across with alar retraction longer than 5 mm in clinical practice.<sup>11</sup>

Since spacer graft requires open rhinoplasty, it is difficult for both the patient and the surgeon to use solely to correct alar retraction without rhinoplasty. In such a case, outer lining extension with local flap or with composite graft could be considered. The method that was used in this study, together with septal extension graft, sufficiently balances a low nasal tip in Asians who want to have rhinoplasty to elevate their nasal tip. The significance of this study, compared to previous studies, is that the outcome of the correction of the alar retraction was assessed objectively with standardized evaluation: via pre-operative and post-operative measurements. In addition, more long-term follow-up and studies based on cases should ensue.

## V. CONCLUSION

Correction of alar retraction is being actively performed, but the correction itself is not easy and the mechanism of alar retraction in patients with secondary

cleft lip and nose deformity differ from that in the general population, so it is difficult to apply the same procedure on such patients without modification. Therefore, the most fundamental factor in the correction of alar retraction in people with secondary cleft lip and nose deformity is repositioning of the alar cartilages, and spacer graft is considered a more physiological method. If patients with secondary cleft lip and nose deformity and alar retraction and who desire rhinoplasty are properly selected, spacer graft, together with septal extension graft, could be used not only to effectively produce symmetry but also to yield an aesthetically satisfactory outcome.

## REFERENCES

1. Kim HS, Roh SG: The alar extension graft for retracted ala. *J Korean Soc Plast Reconstr Surg* 36: 66, 2009
2. Koh KS, Kim EK: Management of unilateral cleft lip nose deformity with retracted ala of the noncleft side. *Plast Reconstr Surg* 118: 723, 2006
3. Gunter JP, Rohrich RJ, Friedman RM: *Importance of the alar-columellar relationship*. In Dallas Rhinoplasty, ST. Louis Missouri, Quality Medical Publishing, Inc., 2007, p 401
4. Gunter JP, Hackney FL: *Clinical assessment and facial analysis*. In Dallas Rhinoplasty, ST. Louis Missouri, Quality Medical Publishing, Inc., 2007, p 105
5. Gruber RP, Kryger G, Chang D: The Intercartilaginous graft for actual and potential alar retraction. *Plast Reconstr Surg* 121: 288e, 2008
6. Ko HW, Han SK, Lee BI, Kim WK: Effects of release of tip supporting fibrous tissues for short nose correction. *J Korean Soc Plast Reconstr Surg* 30: 275, 2003
7. Hobar PC, Adams WP, Mitchell CA: Lengthening the short nose. *Clin Plast Surg* 37: 327, 2010
8. Byrd HS, Andochick S, Copit S, Walton KG: Septal extension grafts: a method of controlling tip projection shape. *Plast Reconstr Surg* 100: 999, 1997
9. Guyuron B: Alar rim deformities. *Plast Reconstr Surg* 107: 856, 2001
10. Rohrich RJ, Ranieri J Jr, Ha RY: The Alar contour graft: correction and prevention of alar rim deformities in rhinoplasty. *Plast Reconstr Surg* 109: 2495, 2002
11. Hirohi T, Yoshimura K: Surgical correction of retracted nostril rim with auricular composite grafts and anchoring suspension. *Aesthetic Plast Surg* 27: 418, 2003