

## 전신성 홍반성 루푸스 환자에서 발생한 괴사성 근막염의 치험례

조혜인 · 장 학

서울대학교 의과대학 성형외과학교실

### Necrotizing Fasciitis in a Patient with Systemic Lupus Erythematosus

Hye In Cho, M.D., Hak Chang, M.D.

Department of Plastic and Reconstructive Surgery, Seoul National University, College of Medicine, Seoul, Korea

**Purpose:** Necrotizing fasciitis is a life-threatening, destructive soft tissue infection with a very high rate of mortality that needs early diagnosis and aggressive treatment. Systemic Lupus Erythematosus (SLE) is a systemic, autoimmune disease and its major cause of mortality is an infection. But necrotizing fasciitis in SLE is very rare and there have been only 22 cases reported in the literatures. We reported a patient of necrotizing fasciitis with SLE and reviewed 22 others from literature research.

**Methods:** A 40-year-old female patient with a history of SLE for 6 years came to the emergency room. The patient complained of severe pain and swelling on her right leg. She was diagnosed as necrotizing fasciitis and underwent emergency fasciotomy. As wound cultures showed variable organisms, she was treated with broad-spectrum antibiotics and underwent several surgical debridements. Then, the wound was treated with the V.A.C (Vacuum Assisted Closure) device and split thickness skin grafting was performed two times.

**Results:** Skin graft was well taken within 2 weeks after operations and the patient was discharged to outpatient follow up. There was no complication related with surgery and she could walk without cane after 3 months.

**Conclusion:** We treated a necrotizing fasciitis in a patient with SLE and reviewed 22 others from literature research. The case presented here suggests that necrotizing fasciitis is a rare disease in SLE patients, but should

be considered in the differential diagnosis of soft tissue infection in SLE patients. A high index of suspicion is needed for early diagnosis and proper management in these patients.

**Key Words:** Necrotizing fasciitis, Systemic lupus erythematosus

### I. INTRODUCTION

Necrotizing fasciitis is a severe, life-threatening soft tissue infection involving subcutaneous tissues and fascia. It is caused by a variety of bacteria and a number of predisposing factors such as diabetes mellitus, liver disease, alcohol abuse, malignancy, malnutrition and immunocompromised status. It may involve any part of the body, but the most common is the lower extremities. The clinical presentation of necrotizing fasciitis entails progressive skin changes. But in the early stages of infection, only tenderness, swelling and erythema are present and therefore, early clinical recognition of necrotizing fasciitis may be difficult. It is a rapidly progressing infection characterized by extensive necrosis and can lead to fatal conditions such as acute compartment syndrome, sepsis and multiple organ failure. The high mortality rate of necrotizing fasciitis (ranging from 15 to 73%) suggests that early diagnosis and rapid treatment are essential and will likely determine the prognosis of necrotizing fasciitis.<sup>1,7</sup>

Systemic lupus erythematosus (SLE) is a chronic, autoimmune disease with numerous immunological and clinical manifestations. Pathogenic autoantibodies and accompanying cells of inflammation are the causes of tissue damage in patients with SLE. It is well known that patients with SLE are prone to infection because of their intrinsic immunocompromised state. And the susceptibility to infection is augmented by drugs such as corticosteroids or other immunosuppressant medications. Infectious diseases have emerged as one of the leading causes of morbidity and mortality, accounting for 20~50% of all deaths in these patients. But necrotizing fasciitis in the setting of SLE has been reported in at least 22 cases in

Received August 14, 2010  
Revised November 22, 2010  
Accepted December 3, 2010

**Address Correspondence:** Hak Chang, M.D., Ph.D., Department of Plastic and Reconstructive Surgery, Seoul National University, College of Medicine, 101 Daehangno, Jongno-gu, Seoul 110-744, Korea. Tel: 02) 2072-3086 / Fax: 02) 747-3076 / E-mail: hchang@snu.ac.kr

\* 이 논문은 2008년도 정부 (교육과학기술부)의 재원으로 한국연구재단의 지원을 받아 수행된 연구임 (No. R11-2005-065)

the medical literature.<sup>1-3</sup>

In this report, we described a case of necrotizing fasciitis on SLE patient with literature review. This patient recovered from the fatal condition as a result of prompt diagnosis and treatment, such as broad antibiotics, surgical debridements and vacuum-assisted closure.

## II. CASE

A 40-year-old woman was diagnosed as SLE in 2003 when she presented with severe thrombocytopenia, hemolytic anemia, arthritis, glucose intolerance, ANA (+) and dsDNA (+). She was subsequently diagnosed with diabetes mellitus and Cushing syndrome. She had been treated with methylprednisolone 16 mg daily and the disease was under control. In April 2009, the patient visited an emergency room and presented with pain and swelling of the right lower leg. She recalled sustaining a right ankle injury by a book at the library 1 week ago. Physical examination showed ecchymosis and multiple bullous lesions on her right foot and swelling, warmth and erythema which extended to her right lower leg. She also complained of severe pain caused by plantar flexion. Initial laboratory studies showed Hemoglobin 13.0 g/dL (12.0~16.0 g/dL), WBC count 40,600/mm<sup>3</sup> (4,000~10,000/mm<sup>3</sup>), platelet count 55,000/mm<sup>3</sup> (130,000~400,000/mm<sup>3</sup>), ESR 5 mm/hr (0~20 mm/hr), C-reactive protein 33.89 mg/dL (0.00~0.50 mg/dL). Sodium was 142 mmol/L (135~145 mmol/L), creatinine was 0.8 mg/dL (0.7~1.4 mg/dL) and glucose was 187 mg/dL (70~110 mg/dL). ANA was weakly positive and antidouble stranded DNA antibodies were 5.97 IU/mL (1~12 IU/mL). C3 54 mg/dL (90~180 mg/dL) and C4 7.7 mg/dL (10~40 mg/dL) were both low. The total LRINEC score was 8, so she was strongly suspected as high risk group of necrotizing fasciitis according to LRINEC (laboratory risk indicator for necrotizing fasciitis) score (Table I).<sup>4</sup>

She complained of increasing pain and swelling of her right lower leg, so she was taken promptly to the operating room for emergency fasciotomy and surgical debridement on the next day. This procedure revealed necrotized subcutaneous fat, fascia and muscle tissue and a significant amount of muscle edema.

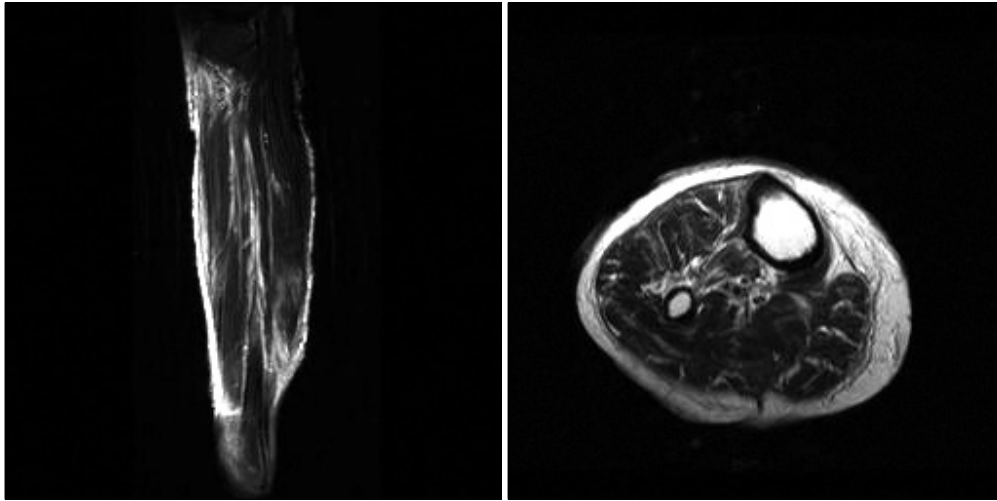
MRI revealed marked inflammatory stranding and a hypertense T2W signal mainly on the tibialis anterior muscle, extensor digitorum muscle, and deep fascia. On MRI, suggestive features were found such as deep fascial thickening, fluid collections along the deep fascia and edematous subcutaneous tissues and muscles (Fig. 1).

Two days later, she complained of chest discomfort and respiratory difficulty. Echocardiography revealed mitral and tricuspid regurgitation. Ejection fraction was 34.6%, so stress-induced cardiomyopathy was highly suspected. She was treated with beta-blockers and furosemide. Laboratory studies showed levels of Hemoglobin to be 9.2 g/dL, WBC count 27,800/mm<sup>3</sup>, and platelet count 1,000/mm<sup>3</sup>. She was treated with intravenous gamma globulin 400 mg/kg/day for 5 days due to thrombocytopenia. Her initial wound cultures were positive for Group A *Streptococcus pyogenes* and 18 days later, wound cultures were positive for *Acinetobacter baumannii*,

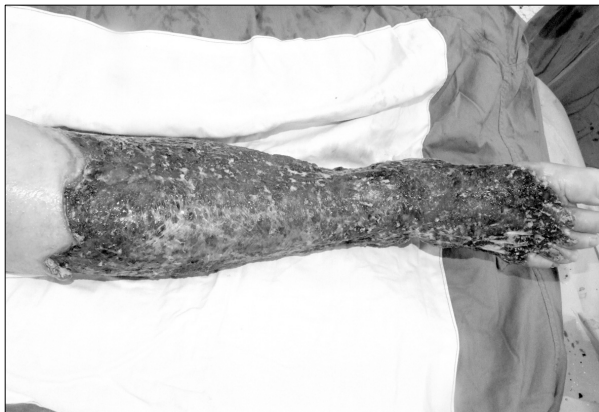**Table I.** The LRINEC (laboratory risk indicator for necrotizing fasciitis) score<sup>4</sup>

Variable	Score
C-reactive protein (mg/L)	
< 150	0
150 or more	4
Total white cell count (per mm <sup>3</sup> )	
< 15	0
15~25	1
> 25	2
Hemoglobin (g/dL)	
> 13.5	0
11~13.5	1
< 11	2
Sodium (mmol/L)	
135 or more	0
< 135	2
Creatinine (mg/dL)	
1.6 or less	0
> 1.6	2
Glucose (mg/dl)	
10 or less	0
> 10	1

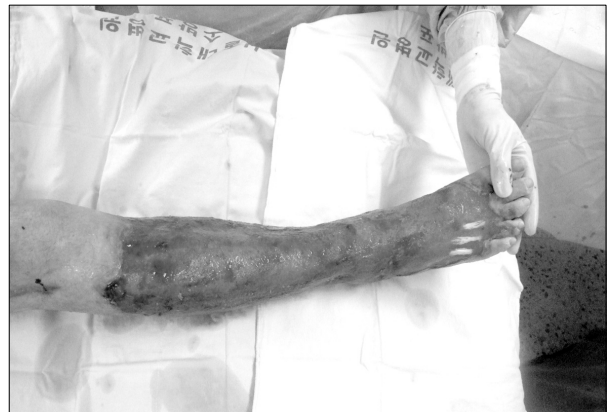At a cutoff of a LRINEC score of 6 or greater, the model has a positive predictive value of 92.0% (95% CI 84.3-96.0) and negative predictive value of 96% (95% CI 92.6-97.9). A score of eight or more is strongly predictive of necrotizing fasciitis (positive predictive value 93.4%, 95% CI 85.5-97.2).



**Fig. 1.** (Left): T2-weighted coronal MR image shows diffuse increased signal intensity of right lower leg. (Right) T2-weighted axial MR image shows diffuse thickening and enhancement of deep fascia and muscle of right lower leg.



**Fig. 2.** Intraoperative picture of first surgical debridement of right lower leg.

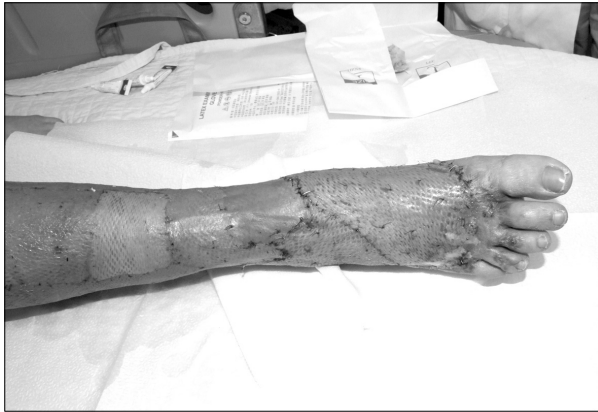

**Fig. 3.** Intraoperative picture of right lower leg before split thickness skin graft. The first split thickness skin graft was performed above the right ankle on the 87th day.

Group A *Streptococcus pyogenes* and Gram positive bacilli. She was treated with Ampicillin. 38 days after surgery, Wound cultures result showed *Acinetobacter baumannii* and Methicillin resistant *Staphylococcus epidermidis*. She was managed with imipenem and levofloxacin, but the patient presented allergic reactions such as urticaria and thrombocytopenia. The patient's antibiotics were changed to Vancomycin and 20 days later, wound cultures turned negative.

The patient underwent several surgical debridements and aseptic dressings (Fig. 2). The last surgical debridement was performed on the 52nd day. Then, a Vacuum Assisted Closure device was applied to the open wound for a period of 22 days. The VAC dressing consisted of an aseptic sponge pad, a Barovac<sup>®</sup> drain and a surgical

drape. Negative pressure of approximately 125 mmHg, supplied by the wall suction, was applied to the wound and dressings were changed twice a week. There were no complications, such as allergies, infection, periwound maceration and pain with application of the negative pressures. The first split thickness skin graft was performed above the right ankle on the 87th day (Fig. 3). After coverage of the partially exposed extensor digitorum longus tendon with granulation tissue, second split thickness skin graft was performed on the 98th day (Fig. 4). The patient was discharged from the hospital after 119 days of in hospital stay. On the 3 months follow up, she had full range of motion in her right lower leg and able to walked without a cane.



**Fig. 4.** After coverage of the partially exposed extensor digitorum longus tendon with granulation tissue, second split thickness skin graft was performed on the 98th day.

### III. DISCUSSION

Necrotizing fasciitis is a rare infection of subcutaneous tissue and superficial fascia, which results in 15~73% of mortality. The prognostic factors of necrotizing fasciitis are streptococcal toxic shock syndrome, immunocompromised state and advanced age. Among these factors, streptococcal toxic shock syndrome is the most severe risk factor for mortality from necrotizing fasciitis. Golger et al. reported that an immunocompromised state accompanied by streptococcal toxic shock syndrome increased the mortality rate up to 40 times, and the predicted mortality of the patient who is over twenty years old with these two risk factors together is almost 100%.<sup>5</sup>

Our patient was a 40-year-old woman who had SLE, diabetes mellitus and treated with high dose steroids for a long time. She was on the immunocompromised state because of her underlying disease and required treatment. Her initial wound cultures were positive for Group A *Streptococcus pyogenes*, which placed her in a high risk group for streptococcal toxic shock syndrome. In this case, early diagnosis and initial treatment of necrotizing fasciitis is very important to improve prognosis.<sup>4</sup>

Infection is the main complication of SLE and a major cause of hospitalization, morbidity and mortality, accounting for 20~50% of deaths in SLE patients. The risk factors of infection are disease activity, proteinuria, hypoalbuminemia and immunosuppressives. However, among the SLE patients, concurrence of necrotizing fasciitis is very rare and there have been only 22 cases reported in the literature (Table II), which implying the presence of specific risk factors related with necrotizing

fasciitis in the patient with SLE. More refined case studies are needed to reveal the factors predisposed to necrotizing fasciitis in the SLE patients, including comparative studies of SLE patients without necrotizing fasciitis.<sup>1,2</sup>

We searched for patients diagnosed as both SLE and necrotizing fasciitis using English literature search. Table II shows the clinical features, treatment and outcome of our patient and 22 others reported in the literatures. It is interesting that 18 of 23 patients had arthritis or nephritis. The extremities were most commonly involved (n=14) followed by abdomen (n=3), genital region (n=2), neck (n=1) and back (n=1).  $\beta$ -hemolytic streptococcus was the most common organism, mostly streptococcus pyogenes (n=8). Surgical operation was done in most of them (n=20) and the mortality rate was almost 35%.

The diagnosis of necrotizing fasciitis is confirmed by biopsy, wound culture, and presence of gas on simple X-ray and CT. Recently, MRI has been preferred because of its possibility to make a differential diagnosis between cellulitis and necrotizing fasciitis. Furthermore, the extent of the involved area can be seen which helps to determine the area of surgical resection. Differential diagnosis between cellulitis and necrotizing fasciitis is crucial, since initial symptoms are similar but the treatment protocols are different.

In our case, a hypertense T2W signal in the deep fascia, subcutaneous gas and thickened skin over the lesion are confirmed necrotizing fasciitis. Without the involvement of deep fascia, necrotizing fasciitis can be excluded. However the treatment of necrotizing fasciitis should not be delayed depending upon MRI findings merely. Over 24 hours of delay, significantly increases on the mortality rate, thus intensive early initial treatment is essential in case of clinically suspicious necrotizing fasciitis.<sup>5,6</sup>

The modalities of treatment for necrotizing fasciitis are administration of antibiotics, fasciotomy, debridement and hyperbaric oxygen therapy. If early debridement or surgical treatment resulted in a defect of the skin and/or tissues, secondary reconstruction is necessary. In most cases, the defect is so broad and repeated surgical treatments such as skin grafts and free flap operations are needed. However, a patient's underlying disease and poor general status frequently forbid immediate reconstruction. Thus, plastic surgeons must choose the proper management of the lesion and determine the effective reconstructive modality. In our department, Vacuum Assisted Closure (VAC) was used twice a week. VAC decreases edema, increases microcirculation, controls bacterial growth, promotes growth of granulation tissue, and thus aids in effective wound healing. The VAC

**Table II.** Summary of SLE Patients Complicated by Necrotizing Fasciitis

No.	Sex/ age	Major manifestations	Site	Cause	Culture	Antibiotics	Operation	Result
1	F/40	Arthritis Thrombocytopenia Hemolytic anemia	Lt. leg	Contusion	<i>Streptococcus pyogenes</i> <i>Acinetobacter baumannii</i> Gram positive bacilli <i>Staphylococcus epidermidis</i>	Ampicillin Imipenem Levofloxacin Vancomycin	Fasciotomy Debridement Split thickness skin graft	Recovered
2	F/34	Arthritis, Seizure	Rt. leg	Unknown	<i>Streptococcus pyogenes</i>	Penicillin	Debridement Split thickness skin graft	Recovered
3	F/43	Arthritis, Nephritis	Rt. leg	Unknown	<i>Escherichia coli</i>	Broad-spectrum antibiotics	Above knee amputation	Died
4	F/53	Arthritis, Nephritis	Rt. hip Abdomen	Unknown	<i>Pseudomonas aeruginosa</i>	Broad-spectrum antibiotics	Debridement	Died
5	M/12	Arthritis, Vasculitis Hemolytic anemia	Lt. neck	Unknown	<i>Streptococcus pneumoniae</i>	Broad-spectrum antibiotics	Debridement	Recovered
6	F/20	Vasculitis, Nephritis	Not available	Not available	<i>Streptococcus pyogenes</i>	Not available	Not available	Recovered
7	F/30	Arthritis, Rash	Not available	Not available	Not available	Not available	Not available	Recovered
8	M/38	Nephritis, Arthritis Cerebritis	Not available	Not available	Negative	Not available	Not available	Recovered
9	F/57	Nephritis, Arthritis Thrombocytopenia	Not available	Not available	<i>Streptococcus pyogenes</i>	Not available	Not available	Died
10	F/42	Cerebral lupus, Nephritis Arthritis	Rt. leg	Cut by fish fins	<i>Aeromonas sobria</i>	Amoxicillin- clavulanate Ofloxacin	Debridement Split thickness skin graft	Recovered
11	F/35	Arthritis	Rt. leg Genital region	Skin scratching	<i>Streptococcus pyogenes</i> <i>Serratia marcescens</i> <i>Aeromonas hydrophila</i> <i>Aeromonas caviae</i> <i>Morganella morganii</i>	Amoxicillin- clavulanate Ofloxacin	Debridement Split thickness skin graft	Recovered
12	F/38	Not available	Back	Unknown	<i>Salmonella enteritidis</i>	Cloxacillin Gentamicin Ceftriaxone	Debridement	Died
13	F/47	Alopecia, Oral ulcers	Not available	Not available	<i>Streptococcus pyogenes</i>	Not available	Above knee amputation	Recovered
14	F/46	Nephritis	Lt. thigh	Unknown	<i>Streptococcus pneumoniae</i>	Metronidazole Sulbactam Cefoperazone	Debridement	Died
15	F/35	Not available	Rt. thigh	Unknown	<i>Salmonella</i> serogroup C	Cefperazone Sulbactam	Fasciotomy Debridement	Recovered
16	F/66	Nephritis	Rt. leg Abdomen	Unknown	<i>Streptococcus pyogenes</i>	Cefotaxime metronidazole	Laparotomy	Died
17	M/40	Not available	Lt. foot	Skin biopsy	<i>Serratia marcescens</i>	Ceftazidime	Debridement	Recovered
18	F/58	Not available	Lt. leg	Unknown	<i>Staphylococcus aureus</i> <i>Serratia marcescens</i>	Fosfomicin Sultamicillin	Debridement	Died
19	F/46	Pleuritis, Arthritis	Lt. leg	Arthrocentesis	Gram-positive cocci	Cefotaxime metronidazole Nafcillin Gentamycin	Debridement	Recovered
20	F/21	Nephritis	Genital region	Bartholin abscess	Polymicrobial: 5 anaerobes 3 aerobes	Broad-spectrum antibiotics	Debridement	Recovered
21	F/34	Nephritis Anti-phospholipid syndrome	Lt. leg Abdomen	Skin sore	<i>Streptococcus pyogenes</i>	Penicillin Cindamycin	Debridement	Recovered
22	F/31	Nephritis	Lt. arm	Unknown	<i>Salmonella crepitant</i>	Meropenem Metronidazole Levofloxacin	Fasciotomy Debridement	Recovered
23	F/17	Nephritis, Arthritis	Both arm and leg	Unknown	<i>Haemophilus influenzae</i> type E	Ceftriaxone Vancomycin Nafcillin Clindamycin Cefotaxime	Fasciotomy Debridement	Died

technique could reduce the admission period and decrease the morbidities associated wound care. The cost of VAC device is high, but we minimized the cost using a wall suction to supply the negative pressure followed by two series of successful STSGs.<sup>8</sup> Among the 22 cases in the literatures, there was no mention of VAC as a treatment modality. We believe that VAC is an effective modality of treatment for SLE patients to reduce the period between presentation and reconstruction.

The case of concurrent necrotizing fasciitis in SLE patients is very rare. However, the clinical course is rapid and the mortality rate is high, which makes close observation and early intensive treatment necessary for suspicious cases of necrotizing fasciitis. With literature review, we report a successful treatment of necrotizing fasciitis using wide-spectrum antibiotics, debridement, VAC and STSGs.

## REFERENCES

1. Kamran M, Wachs J, Putterman C: Necrotizing fasciitis in systemic lupus erythematosus. *Semin Arthritis Rheum* 37: 236, 2008
2. Mok MY, Wong SY, Chan TM, Tang WM, Wong WS, Lau CS: Necrotizing fasciitis in rheumatic disease. *Lupus* 15: 380, 2006
3. Mendez EA, Espinoza LM, Harris M, Angulo J, Sanders CV, Espinoza LR: Systemic lupus erythematosus complicated by necrotizing fasciitis. *Lupus* 8: 157, 1999
4. Wong CH, Wang YS: The diagnosis of necrotizing fasciitis. *Curr Opin Infect Dis* 18: 101, 2005
5. Golger A, Ching S, Goldsmith CH, Pennie RA, Bain JR: Mortality in patients with necrotizing fasciitis. *Plast Reconstr Surg* 119: 1803, 2007
6. Jung HS, Kim DC, Cho SH, Han BK, Kang SY: Consideration of necrotizing fasciitis. *J Korean soc Plast Reconstr Surg* 34: 383, 2007
7. Park SH, Noh BK, Kim ES, Hwang JH, Kim KS, Lee SY: Analysis of necrotizing fasciitis patient by causative pathogens. *J Korean soc Plast Reconstr Surg* 34: 319, 2007
8. Huang WS, Hsieh SC, Hsieh CS, Schoung JY, Huang T: Use of vacuum- assisted wound closure to manage limb wounds in patients suffering from acute necrotizing fasciitis. *Asian J Surg* 29: 135, 2006