

전안면골 골절에서의 변형된 아래턱밑 삽관

최상문 · 송승한 · 강낙헌

충남대학교 의과대학 성형외과학교실

Modified Submental Intubation in Panfacial Bone Fracture Patients

Sangmun Choi, M.D., Seung Han Song, M.D.,
Nak Heon Kang, M.D.

Department of Plastic & Reconstructive Surgery, College of
Medicine, Chungnam National University, Daejeon, Korea

Purpose: Nasotracheal or oral intubation procedure is widely used for facial bone fractures. However, during the operation intubated tube can interfere or obstruct the view of the operator. We authors used a modified submental intubation method in panfacial bone fracture patients for intact airway and the operation view.

Methods: After intravenous induction of anaesthesia, traditional orotracheal tubation was done. A horizontal incision was made 2 cm from the midline, 2 cm medial to and parallel with the mandible in the submental region.¹ In order to approach to the floor of the oral cavity, a haemostat was pushed through the soft tissues. A chest tube front cover was applied to the intubation tube and the tube was inserted through the submental tunnel. Orotracheal tube was disconnected and pulled back through the soft tissue and secured with a suture.

Results: The procedure took about 30 minutes and there were no problems during the intubation. Intraoral manipulation and occlusal checks were free without any interference. Extubation was also easily done without any complications such as lung aspiration, infection, hematoma, or fistula.

Conclusion: Submental endotracheal intubation is fast, safe, easy to use and free from the concern about the tube being pull back again. Conventional submental intubations are being held without any coverage of the tip. We authors applied the modified method to the trauma patients and obtained satisfactory results. From the above advantages,

modified submental intubation can be widely available not only in fractured patients, but also in aesthetic or orthognathic surgeries.

Key Words: Submental endotracheal intubation, Panfacial bone fractures

I. INTRODUCTION

During general anesthesia, endotracheal intubation, which can be done through oral or nasal pathway, is usually done for head and neck surgeries. Because of its simplicity and safety of the procedure, it is widely used. An operation for panfacial bone fractures requires a definite surgical view, however the tube may block the surgeon's view and interfere the surgeon's manipulations. Furthermore, the tube has to be moved to the opposite side of the face in order to operate whole fracture sites. Also, the tube may be pushed back from the insertion and may delay the operation time.¹ Also, tracheostomy may be held for a panfacial bone fracture patient, however infection, hematoma, subcutaneous emphysema and injury of recurrent laryngeal nerve may arise.² To overcome the above limitations submental endotracheal intubation can be an alternative way to solve the problems. We authors revised the traditional method of submental intubation by using the chest tube cover and applied to the patients with panfacial bone fractures.

II. IDEAS AND INNOVATIONS

For prevention of infection, preoperative antibiotic medication with amoxicillin and clavulnic acid was done through the intravenous line. Oral endotracheal tube was intubated after injecting propopof and muscle relaxant rocuronium positive-pressure ventilation with mask, positive-pressure ventilation was carried out with 50% oxygen inhalation anesthetics. With patient properly anesthetized, antiseptic solution (Betadine) was applied on submental incision site and operation was carried out following '222 rule' described by Nyarady et al. 2 cm

Received August 3, 2010
Revised October 8, 2010
Accepted October 20, 2010

Address Correspondence: Nak Heon Kang, M.D., Department of
Plastic & Reconstructive Surgery, Chungnam National
University Hospital, 640 Daesa-dong, Jung-gu, Daejeon 301-
721, Korea. Tel: 042) 280-7385/Fax: 042) 280-7384/E-mail:
nhk488@yahoo.com

transverse incision was made in a direction 2 cm inferior from the margin of mentum and 2 cm lateral from the midline.¹ After reaching the oral base by dissection in the oral soft tissue using hemostat in order to protect important structures of soft tissue from damage, fortified tracheal tube (diameter 7.0~7.5 mm) inserted with stylet was covered with 32F chest tube cap (Fig. 1), it was inserted into oral cavity and then chest tube cap was removed with Magill forceps. And by extubating already inserted tube, fortified tracheal tube was intubated into trachea using Magill forceps. After confirming proper depth of intubation, incision site and tube were firmly fixed to incision are with 4-0 silk suture (Fig. 2).

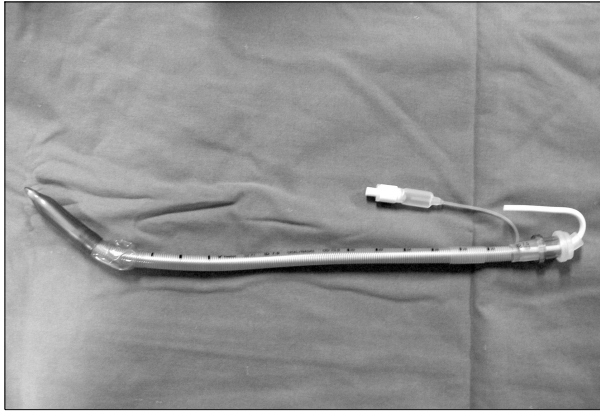


Fig. 1. A 34 F chest tube cap is covered on an intubation tube. It enabled the tube to be inserted smoothly and safely.

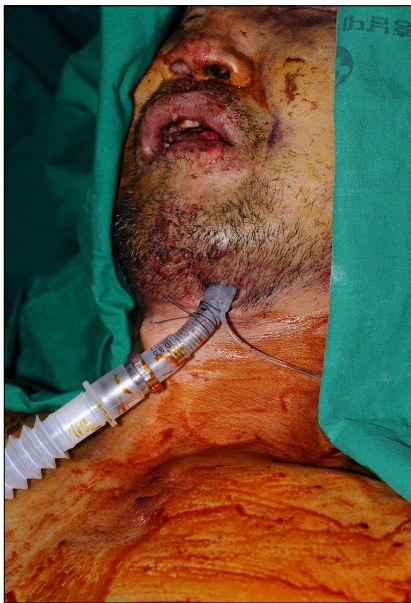

Fig. 2. A 60-year-old male patient prepared for operation after submandibular intubation.

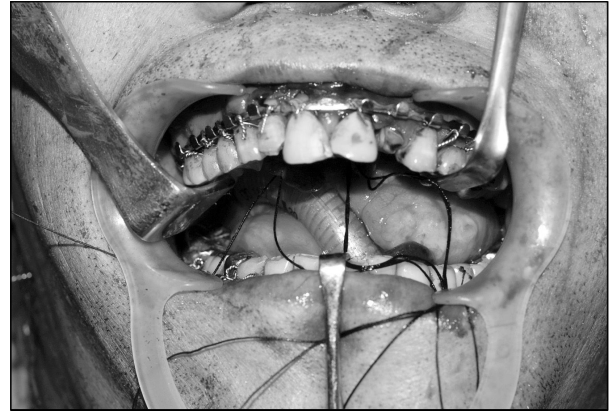


Fig. 3. Intraoral manipulation was free in all procedures and intermaxillary occlusion could be easily checked.

III. DISCUSSION

The time required for submental intubation in panfacial fracture patients was about 20 minutes and there were no decrease in oxygen saturation during the procedure. There was no interrupting anatomical structure during dissection with hemostat from the incision to intraoral site. Also there was no damaged structure during the intubation.

It enabled intermaxillary fixation with free dental interlocking in every patient including precise fracture reposition. The operator was able to carry out without the hindrance of the tube (Fig. 3), and there was no leaking of inhalation anesthetics during the operation.

The tube was extubated easily right after the operation, and there were no hematoma, bleeding, fistula or damage of the glands. In some cases with severe complications such as respiratory problem or mental disorders, the tube was kept for more several days. Delayed extubation was held at intense care unit with the anesthesia team cooperation. The subcutaneous layer of insertion site was sutured with 5/0 Vicryl and the skin layer was repaired with 6/0 Mersilk. The opening of the oral cavity was closed with 5/0 vicryl. Daily simple dressing was done at the insertion site. There was no sign of nerve damage and the mucosa of the oral cavity healed without any disruption. Even though the scar of submental area existed in some cases, none of the patients complained about it.

During the general anesthesia, oral or nasal airway intubation can be precisely and easily done. However, if the patient has a skull base fracture, leakage of the CSF can be a real danger and the mid-portion of the multiple fracture sites can be difficult to access.³ When

Hernandez Altemir first attempt the submental intubation in 1986 all patients had trauma history, but later on other surgeons reported that it can be good results to orthognathic operations.^{4,5} Submental intubation has the same advantages that oral or nasal airway intubation don't have; oral occlusion can be effortlessly estimated during the surgery and can freely access the nasal bone fractured area. It can avoid the meningitis and skull base fracture. Other complications that might occur after tracheostomy, tracheostenosis, cervical vessel damage can be avoided.³

The foremost benefit of this procedure is that the operator do not need to mind the tube during the surgery, because the tube do not disturb the operator's hand. Meyer insisted submental intubation procedure in all panfacial bone fracture patients who need intermaxillary fixation. Bogi and Incze stated that submental intubation is also valuable during osteotomy, Nwoku reported 10 cases of operations using submental intubation and 2 of them were orthognathic surgery.¹

Many authors used submental intubation method described by Altemir. In our study we used a similar way that Nyarady devised; covering a nylon tube at the head of the intubation tube in order to avoid soft tissue damage during the insertion. We modified the Nyarady method by using the cap of the 32F chest tube which is inserted when pneumothorax or hemothorax occur. Because of the cap, soft tissue injury was lower than the traditional method (Fig. 1). However, the submental intubation procedure takes 20 minutes more than the oral or nasal method, and the learning curve is relatively long. The practitioner should know the anatomical structures thoroughly with the intension with not harming normal structures. The operator should explain to the patient, that there can be infection, fistulas, bleeding, and a hypertrophic scar.⁴ When incising the chin, marking the

definite line should be made and proper dissection is preferred. During the procedure the patient has to be observed carefully, so discussion and cooperation with the anesthesia team is necessary.⁶

Covering the intubation tube with the cap of the chest tube can be simply done, and the risk of the procedure decreases. Currently, submental intubations are being held without any coverage of the tip. Since the approach to the mouth floor is blunt dissection it might cause tissue damage and leave a remnant complication. We authors modified and applied the method to the trauma patients. With the advantages of the newly revised submental intubation method, we should also apply to aesthetic operations, such as orthognathic surgeries or osteotomies. The surgeon can perform the operation more precisely and the estimation can be done anytime during the operation. This will give a satisfying aesthetical and functional result to the patients.

REFERENCES

1. Nyarady Z, Sari F, Olasz L, Nyarady J: Submental endotracheal intubation in concurrent orthognathic surgery: a technical note. *J Craniomaxillofac Surg* 34: 362, 2006
2. Kim KJ, Lee JS, Kim HJ, Ha JY, Park H, Han DW: Submental intubation with reinforced tube for intubating laryngeal mask airway. *Yonsei Med J* 46: 571, 2005
3. Caubi AF, Vasconcelos BC, Vasconcellos RJ, de Morais HH, Rocha NS: Submental intubation in oral maxillofacial surgery: review of the literature and analysis of 13 cases. *Med Oral Patol Oral Cir Bucal* 13: E197, 2008
4. Chandu A, Witherow H, Stewart A: Submental intubation in orthognathic surgery: initial experience. *Br J Oral Maxillofac Surg* 46: 561, 2008
5. Altemir FH, Montero SH, Pena MM: About submental intubation. *Anaesthesia* 58: 496, 2003
6. MacInnis E, Baig M: A modified submental approach for oral endotracheal intubation. *Int J Oral Maxillofac Surg* 28: 344, 1999