

Case Report

Disseminated Cysticercosis

Soo Yong Park, M.D., Min Ho Kong, M.D., Jung Hee Kim, M.D., Kwan Young Song, M.D.

Department of Neurosurgery, Seoul Medical Center, Seoul, Korea

Disseminated cysticercosis is a rare form of cysticercosis in which the cysticerci spread out through the whole body. We report the first case of a 39-year-old Mongolian with disseminated cysticercosis. He visited our hospital with generalized tonic-clonic seizure. After extensive investigation from brain computed tomography (CT), spine magnetic resonance imaging (MRI), whole body MRI and pathologic biopsy, he was diagnosed as having cysticercosis involving the brain, subcutaneous tissue, and skeletal muscles through the whole body. We treated him with the albendazole in which case the followed MRI showed that numbers of cystic lesions were copiously decreased. We report an unusual case of disseminated cysticercosis treated with medical therapy.

Key Words : Disseminated cysticercosis · Neurocysticercosis.

INTRODUCTION

Neurocysticercosis is the most common parasite disease of the central nervous system^{3,5,6,9,11,12,15}. However, disseminated cysticercosis is a very rare manifestation of the neurocysticercosis and fewer than 50 cases of disseminated cysticercosis have been reported in the world²⁷. Government medical college in India mentioned that among 450 cases of cysticercosis, only one case of disseminated cysticercosis was seen in their study². Also, we underwent several cases of the neurocysticercosis in our institution but this case of disseminated cysticercosis was the first time we had treated in Korea.

Although, the regimen for the treatment of neurocysticercosis is reported, there is no therapeutic regimen for the disseminated cysticercosis established in Korea.

CASE REPORT

A 39-year-old young man from Mongol presented with generalized tonic-clonic seizures and headache. He had not taken anti-epileptic drugs and any other medications before this seizure attack. He complained of a headache, not depend on time but any time throughout the day. He did not have any medical diseases or operation in the past. In his childhood, he enjoyed to eat uncooked pigs, yaks, cows and horses. Additionally, he grew up at

the mountain in Mongol where there were close contacts with animals, contaminated water, lack of sewage system and poor personal hygiene. He grew up and mostly lived in Mongol. He has migrated to Korea and it has been only 6 months in Korea. His consciousness was alert and his appearance looked to be normal. There were no neurologic deficits seen on physical examinations.

He was admitted to our hospital and investigated with routine hematology that showed normal complete blood count, erythrocyte sedimentation rate and C-reactive protein were normal range. Human immunodeficiency virus-antibody test using enzyme-linked immunosorbent assay (ELISA) was negative. Cerebrospinal fluid (CSF) routine exam of spinal tapping revealed pleocytosis, predominant polymorphonuclear leukocytes, and acid fast bacilli stain and culture were negative. However, in ELISA investigation, serum and CSF parasite antibody immunoglobulin G for cysticercosis were positive. The electrocardiogram was normal sinus rhythm and three dimension echocardiography showed normal wall motion.

The x-ray for the skull did not reveal abnormal appearance. Brain CT revealed multiple cystic lesions, which appeared as starry-night appearance, in the brain parenchyma (Fig. 1). Brain MRI showed numerous cystic lesions in the brain parenchyma and the lesions were also founded in temporalis muscle, around optic nerve and tongue (Fig. 2). On the spine MRI and whole body MRI, there were numerous cysticerci in subcutaneous tissue, skeletal muscles and the other organs (Fig. 3, 4). Therefore, we thought that cysticerci were disseminated throughout the whole body.

The open biopsies were taken from the brain. Incision was made on the skin and the temporalis muscle was exposed with a whitish yellow egg. After Fronto-temporal craniotomy, another

• Received : May 3, 2010 • Revised : July 2, 2010

• Accepted : February 6, 2011

• Address for reprints : Min Ho Kong, M.D.

Department of Neurosurgery, Seoul Medical Center, 171-1 Samseong-dong, Gangnam-gu, Seoul 135-740, Korea

Tel : +82-2-3430-0645, Fax : +82-2-557-8207

E-mail : davidmhkong@gmail.com

er whitish yellow egg shaped lesion was exposed in the sub-arachnoid space as soon as the dura was opened and it was easily separated from the parenchyma (Fig. 5). The biopsies from the temporalis muscle and the brain both were defined as cysticercus on pathologic examination (Fig. 6).

The patient was treated with dexamethasone 0.1 mg/kg of body weight and albendazole 400mg twice a day for 8 days. After 8 days later, the steroid was tapered and albendazole was stopped. While the treatment was applying, the patient did not complain of a headache and the seizure did not occur. In addition, the followed brain CT and MRI proved that the cystic lesions were markedly decreased after the treatment (Fig. 7). The patient was discharged and is seen regularly in out-patient clinic.

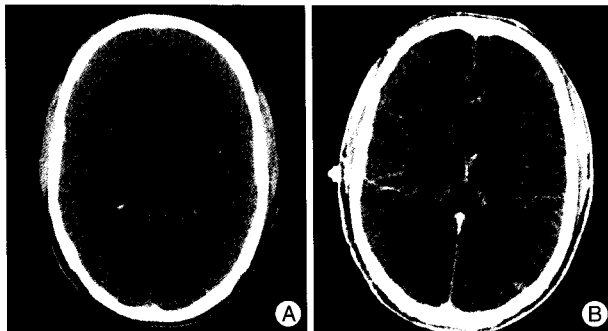


Fig. 1. Brain CT scan at admission. A : Non-contrast of axial CT scan reveals innumerable cysts with hyperdense "dot" in the brain parenchyma. B : Contrast of axial CT scan demonstrates numerous cysticerci with vesicular stage.

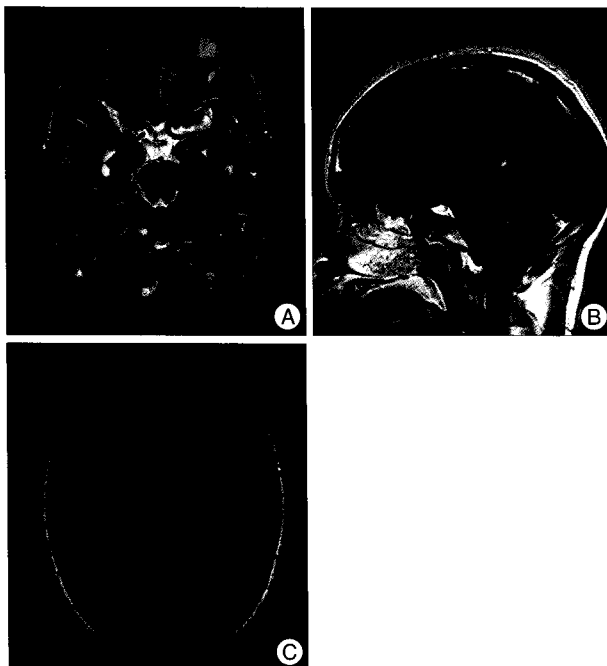


Fig. 2. Brain MRI at admission. A : Brain axial, T2-weighted MR image without gadolinium shows that the numerous hyperintense cysts are in brain parenchyma, left optic lesion and temporalis muscle. B : Brain sagittal, post-gadolinium MR image reveals eccentric cyst in the tongue. C : Brain axial, T1-weighted MR image shows innumerable cysts with hyperintense eccentric lesions in the brain parenchyma.

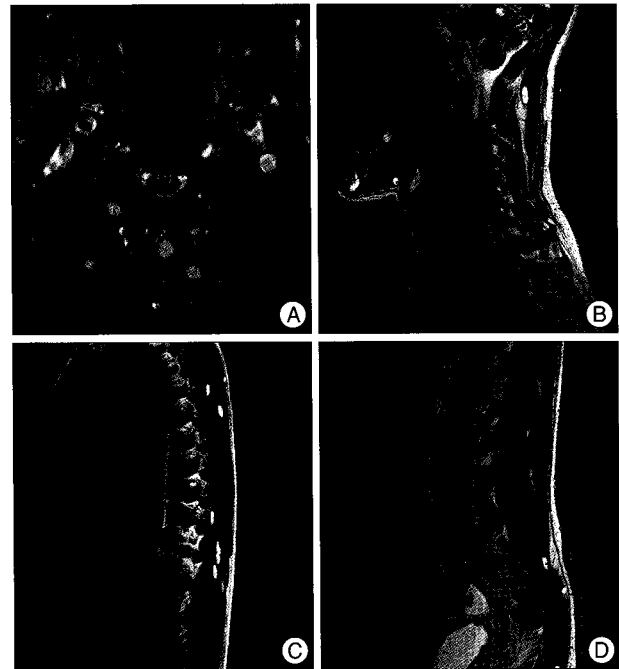


Fig. 3. Spine MRI at admission. A and B : Spine axial and sagittal T1-weighted MR images without gadolinium show multiple cystic lesions in paraspinal muscle and cysticercus is seen in subarachnoid space on T3 body level. C and D : Spine sagittal, T2-weighted MR images without gadolinium show that numerous cystic lesions are also found in thoracolumbar spine muscle.



Fig. 4. On whole body MRI, T2-weighted image without gadolinium revealing numerous cysticerci on the whole body.

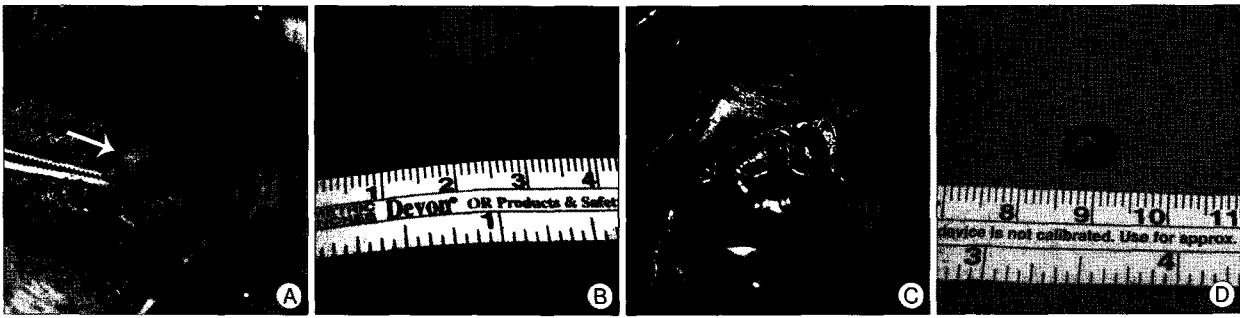


Fig. 5. Intra-operative finding. A and B : cysticercus has been removed from left temporalis muscle (white arrow). C and D : whitish yellow cystic lesion (black arrow) is seen in subarachnoid space after opening of the dura.




Fig. 6. Pathologic examination of the mass in the subarachnoid space of the brain (A and B) show the wall of larval cyst with chronic inflammatory cell infiltration.




Fig. 7. Three months later after treatment, brain axial, T2-weighted MR images scan without gadolinium shows that the numerous cysts are significantly decreased after albendazole treatment. A : Brain sagittal, post-gadolinium MR images also presents decreased number of cystic lesions. B and C : Brain axial, T1-weighted MR image shows disseminated rim enhancing small lesions with mild multifocal edemas in subcortical white matters.

DISCUSSION

Neurocysticercosis is common parasite disease in most of developing countries, especially in Latin-America, Asia and Africa^{1,6,12-15,17}. These countries have high prevalence of cysticercosis because there is a close contact between humans and pigs, and poor hygiene^{2,6,12-14,17}. In addition, they enjoy to eat uncooked meat. Also, the parasite disease occurs in industrialized nations, largely as a result of the immigration of infected persons from the endemic area.

Widespread dissemination of cysticerci throughout the human body was reported as early as 1912 by British Army medical officers stationed in India^{2,16}. In contrast to many neurocysticercosis were reported, the disseminated cysticercosis cases were reported only few in number. Currently, fewer than 50 cases have been re-

ported worldwide, the majority being from India²⁷. Until the present time, the case of disseminated cysticercosis has not been reported in Korea. To our knowledge, this is the disseminated cysticercosis first treated case in Korea.

The larvae of taenia solium cause neurocysticercosis and the ova of the tapeworm spread via the fecal-oral route. The intermediate host is the pig, which harbors the larvae after eating ova, while the definitive host is the human being. Once the human ingests egg-contaminated food or water, the cysticerci spread through the small intestine and then extend to muscles, brain and subcutaneous tissues via blood stream. The usual organs that involved are subcutaneous tissue, skeletal muscles, lungs, brain, eyes, liver and heart. In our case, the patient enjoyed to eat uncooked animals from his childhood in Mongol and grew up in poor sanitation, water supply and personal hygiene^{2,9,14}. Both of this environment and traditional food culture in Mongol might be the cause of the dis-

seminated infection.

Subsequent studies failed to highlight this form of clinical presentation, because of its relative rarity. The main features of disseminated cysticercosis include intractable epilepsy, dementia, enlargement of muscles, subcutaneous and lingual nodules and a relative absence of focal neurological signs or obviously raised intracranial pressure, at least until late in the disease. Clinical presentations of our patient were only headache, generalized tonic-clonic seizure. There were no other clinical manifestations such as visual disturbance, muscle hypertrophy with tenderness, subcutaneous nodules which were usually seen in other case reports of disseminated cysticercosis.

The reported cases of disseminated cysticercosis were treated with physician's own trial which was not established worldwide. Even though there is no certain established guide line

for treatment and diagnosis of the disseminated cysticercosis in Korea, the management of disseminated cysticercosis may include symptomatic treatment of central nervous system lesions. The reason why the biopsies were performed is that the diagnosis remained questionable and the disseminated cysticercosis had not been reported in Korea before. Pharmacological management with the cysticidal drugs praziquantel and albendazole is indicated as they help by reducing the parasite burden⁸. These drugs facilitate the death of the cysts. However, the pharmacological treatment may be associated with severe reactions, which may result from massive release of antigens causing local tissue swelling and generalized anaphylactic reaction. The corticosteroids would decrease the incidence of such complications when it is used before starting the cysticidal drug^{6,11,13,14,16}.

In other cases of disseminated cysticercosis, most institutions used albendazole in a dose of 15 mg/kg/day for 30 days and few other institutions applied praziquantel in a dose of 50mg/kg/day for 15-20 days^{2,7,11}. The advantage of albendazole over praziquantel is that the former also destroys subarachnoid and ventricular cysts because of its better penetration in CSF, as well as the fact that it can be administered jointly with corticosteroid agents for anti-inflammatory therapy^{6,11,13,14,16}. Even though both regimens were treatable for the disseminated cysticercosis, the cysticidal drugs cause inflammatory reactions and may exacerbate the intracranial hypertension which may cause the side effects such as headache, nausea and vomiting¹⁰. Thus, we attempted to treat the patient with lower dose for short duration than other cases; that is albendazole in a dose of 12 mg/kg/day for 8 days and dexamethasone in a dose of 0.1 mg/kg/day⁴. After 8 days, the steroid was tapered and albendazole was stopped. After the treatment, the symptoms of headache and seizure were disappeared and followed brain MRI presented decreased numbers of cysts in brain parenchyma. Despite the low dose and short duration of cysticidal drugs' usage, the symptoms were improved and numbers of the cysts were reduced in follow up radiologic images. Even if we need more cases of disseminated cysticercosis to investigate and establish the proper management, the complications of cysticidal drugs had not been occurred after the low dose and shorter duration of the regimen.

CONCLUSION

We report the first treated case of disseminated cysticercosis

in Korea. Even though the disseminated cysticercosis is very rare infectious disease, we recommend to investigate the spine and other organs to rule out the disseminated cysticercosis when multiple neurocysticerci present in the brain CT scan.

References

1. Bergsneider M, Holly LT, Lee JH, King WA, Frazee JG : Endoscopic management of cysticercal cysts within the lateral and third ventricles. *J Neurosurg* 92 : 14-23, 2000
2. Bhalla A, Sood A, Sachdev A, Varma V : Disseminated cysticercosis : a case report and review of the literature. *J Med Case Reports* : 137, 2008
3. Chang GY, Keane JR : Visual loss in cysticercosis : analysis of 23 patients. *Neurology* 57 : 545-548, 2001
4. Cruz I, Cruz ME, Carrasco F, Horton J : Neurocysticercosis : optimal dose treatment with albendazole. *J Neurol Sci* 133 : 152-154, 1995
5. Del Brutto OH, Rajshekhar V, White AC Jr, Tsang VC, Nash TE, Takayanagui OM, et al. : Proposed diagnostic criteria for neurocysticercosis. *Neurology* 57 : 177-183, 2001
6. Garg RK : Neurocysticercosis : classic diseases revisited. *Postgrad Med J* 74 : 321-326, 2008
7. Kumar A, Bhagwani DK, Sharma RK, Kavita, Sharma S, Datar S, et al. : Disseminated cysticercosis. *Indian Pediatr* 33 : 337-339, 1996
8. López-Gómez M, Castro N, Jung H, Sotelo J, Corona T : Optimization of the single-day praziquantel therapy for neurocysticercosis. *Neurology* 57 : 1929-1930, 2001
9. Mamkin I, Sood N, Ramanan SV : Taenia solium neurocysticercosis. *N Engl J Med* 357 : 1666-1667, 2007
10. Pretell EJ, Garcia HH, Custodio N, Padilla C, Alvarado M, Gilman RH, et al : Short regimen of praziquantel in the treatment of single brain enhancing lesions. *Clin Neurol Neurosurg* 102 : 215-218, 2000
11. Proaño JV, Madrazo I, Avelar F, López-Félix B, Díaz G, Grijalva I : Medical treatment for neurocysticercosis characterized by gaint subarachnoid cysts. *N Engl J Med* 345 : 879-885, 2001
12. Román G, Sotelo J, Del Brutto O, Flisser A, Dumas M, Wadia N, et al : A proposal to declare neurocysticercosis an international reportable disease. *Bull World Health Organ* 78 : 399-406, 2000
13. Sotelo J, Del Brutto OH : Brain cysticercosis. *Arch Med Res* 31 : 3-14, 2000
14. Sotelo J, Del Brutto OH : Review of neurocysticercosis. *Neurosurg Focus* 12 : e1, 2002
15. Sotelo J, Escobedo F, Rodriguez-Carbajal J, Torres B, Rubio-Donnadieu F : Therapy of parenchymal brain cysticercosis with praziquantel. *N Engl J Med* 310 : 1001-1007, 1984
16. Wadia N, Desai S, Bhatt M : Disseminated cysticercosis. New observations, including CT scan findings and experience with treatment by praziquantel. *Brain* 111 : 597-614, 1988
17. White AC Jr : Neurocysticercosis : updates on epidemiology, pathogenesis, diagnosis, and management. *Annu Rev Med* 51 : 187-206, 2000