

## The Laparoscopic Repair of a Morgagni Hernia in a Child

Yong Joon Ra, M.D.\*, Up Huh, M.D.\*\*, Sang-Gwon Lee, M.D.\*, Hyung Gon Je, M.D.\*

A 12-year-old female presented with the abnormal findings on the chest PA. The chest CT revealed a retrosternal defect of the diaphragm and a fatty opacity in the pleural cavity, resulting in a diagnosis of Morgagni hernia. It was decided to undergo a laparoscopic surgery. The retrosternal defect of the diaphragm measuring 3.5 cm in diameter was found, through which a portion of the greater omentum and the fatty tissue connected with the falciform ligament were herniated into the pleural cavity. The greater omentum was pushed back into the peritoneal cavity and the fatty tissue connected with falciform ligament was excised. The mediastinal pleura was plicated and the defect of the diaphragm was repaired primarily. Immediately after the operation, the patient developed a right pneumothorax for which a chest tube was inserted. She was discharged at the post-operative third day without any further complications.

Key words: 1. Hernia  
2. Hernia, diaphragmatic  
3. Morgagni hernia

### CASE REPORT

A 12-year-old female visited the hospital with the chief complaint of an abnormal finding on a simple chest X-ray. A radiopaque lesion was observed in the right cardiophrenic angle area (Fig. 1A). A discontinuity of the diaphragm was observed in the retrosternal portion by chest CT and mesenteric fat was herniated through this discontinuity (Fig. 1B). Based on these findings, a Morgagni hernia was diagnosed. The lack of an intestinal hernia was confirmed by barium esophagography, and there was no finding of incarceration. Therefore, an operation was scheduled. Although the patient was 12 years old, her height was above average for her age at 164 cm. Thus, it was determined to perform a laparoscopic

procedure considering that the surgical space for the laparoscopic procedure would be large enough, given her height. Another reason was the cosmetic concern because the patient was female. A 10-mm 30 degree laparoscope was inserted through an upper umbilical incision. To insert additional surgical instruments, a 10-mm troca was inserted through the left flank, the right lower rib, and the right flank incision. CO<sub>2</sub> gas was insufflated into the peritoneal cavity during the operation. Its pressure was maintained at 10 mmH<sub>2</sub>O. The diaphragm injury was observed on the left side of the falciform ligament in the peritoneal cavity (Fig. 2A).

The lesion of the diaphragm injury was oval in shape and around 3.5 cm. The great omentum and fat from the falciform ligament were put in the thoracic cavity. No intestinal

\*Department of Thoracic and Cardiovascular Surgery, Pusan National University Yangsan Hospital

\*\*Department of Thoracic and Cardiovascular Surgery, Pusan National University Hospital

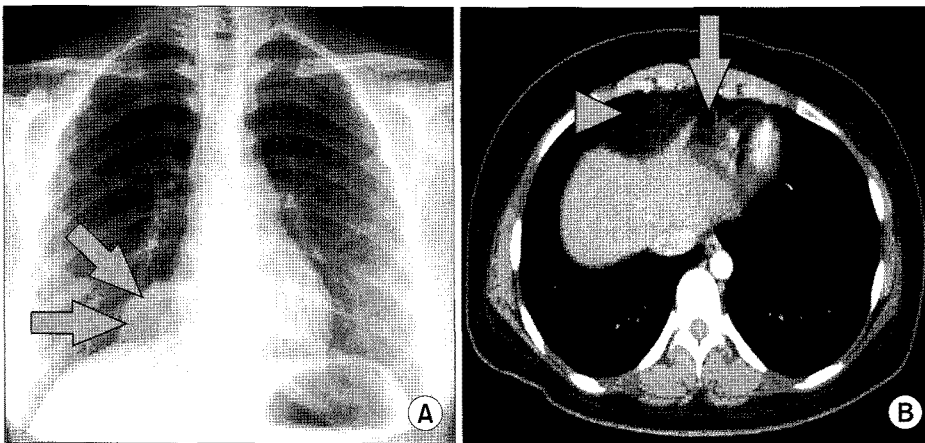
†This article was presented as a case study on video at the Thoracic and Cardiovascular Surgery Conference in 2010.

Received: July 9, 2010, Revised: January 12, 2011, Accepted: January 12, 2011

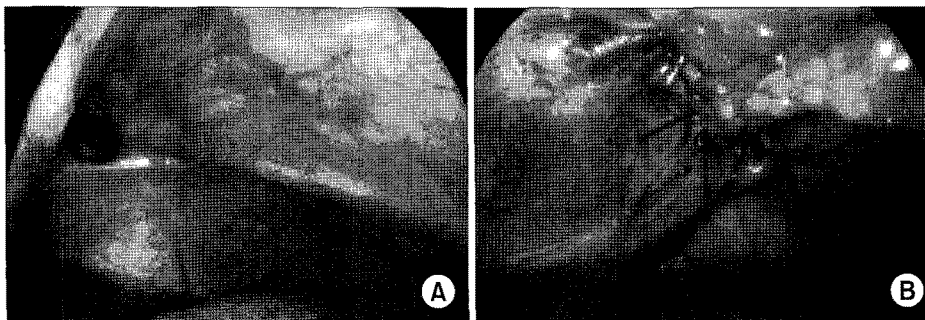
Corresponding author: Yong Joon Ra, Department of Thoracic and Cardiovascular Surgery, Pusan National University Yangsan Hospital, Beomeo-ri, Mulgeum-eup, Yangsan 626-770, Korea  
(Tel) 82-55-360-2127 (Fax) 82-55-360-2157 (E-mail) trimy@paran.com

© The Korean Society for Thoracic and Cardiovascular Surgery. 2011. All right reserved.

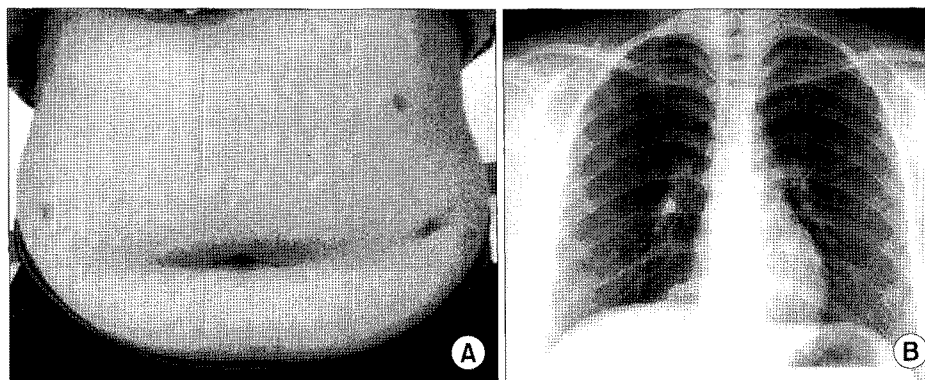
© This is an open access article distributed under the terms of the Creative Commons Attribution Non-Commercial License (<http://creativecommons.org/licenses/by-nc/3.0>) which permits unrestricted non-commercial use, distribution, and reproduction in any medium, provided the original work is properly cited.



**Fig. 1.** (A) The preoperative chest PA. The right cardiophrenic angle shows a radio-opaque lesion (arrows). (B) The preoperative chest CT. A defect is present in the diaphragm behind the sternum (arrow). Through the defect, radio-opaque fatty tissue is protruding into the pleural cavity (arrow head).



**Fig. 2.** Intraoperative finding. (A) There is an opening in the diaphragm measuring approximately 3 cm in diameter. (B) The surgical repair of the diaphragm. Hernia sac was obliterated with placation and the diaphragm was repaired with 2-0 prolene.



**Fig. 3.** (A) Post-operative status of the patient. The operative approaches are shown with an appealing cosmetic effect. (B) Post-operative chest PA. The fat density has disappeared at the cardiophrenic angle and no complications are seen.

hernia was observed. The great omentum, which was pushed into the thoracic cavity by the diaphragm injury, was recovered. The falciform ligament was separated from the margin of the thoracic wall to secure space for the operation. After resection of adipose tissue from the falciform ligament, the hernia sac was closed by tying up the mediastinal pleura and the right diaphragm as is done for plication. To avoid creating a dead space in the pleura cavity, an incision of

about 1 cm was made in the mediastinal pleura before tie-up to make the dead space disappear by inflation of the lung. The right margin of the diaphragm defect was stretched in the lateral direction to adjust the edge of the diaphragm. A simple suture was performed with Prolene 2-0 (Fig. 2B). A chest tube was inserted to treat a pneumothorax which occurred right after the operation. The chest tube was removed on the second day after the surgery. The patient was dis-

charged on the third day after the surgery without special complications, and her progress was observed in the out-patient department (Fig. 3).

## DISCUSSION

Morgagni hernias, which are the rarest type among the congenital diaphragmatic hernias, comprise 3~5% of all diaphragmatic hernias [1,2]. Most cases (90%) occur in the right diaphragm. However, cases occasionally occur in the bilateral and left diaphragms. Most cases of Morgagni hernias are diagnosed in teenagers. However, other cases are found in adulthood and pregnancy, the latter of which makes abdominal pressure increase because it is usually asymptomatic [3]. According to the research of Comer et al., it was reported that symptoms appeared in 28% of cases [4]. Symptoms included upper abdominal pain, dyspnea, and vomiting. Acute symptoms form in only 14% of cases; however, surgical treatment should be considered because there is a risk of incarceration by an intestinal hernia [5,6].

Surgical approaches are through the abdomen or the thorax. Hernia sacs can be found and removed easily with the approach through the thorax. In addition, this approach has an advantage in case of adhesion between the pericardia and lungs. On the other hand, disadvantages of this approach are that it is difficult to repair bilateral hernias and to diagnose the obstruction of intestine. Herniated organs can be returned to their original places easily with an approach through the abdomen. Particularly, this approach should be used in case of bilateral and central hernias, and combined abnormalities in the abdomen [7]. The defect in a Morgagni hernia occurs in the middle tendon of the diaphragm. Thus, the diameter of the width is bigger than the anteroposterior diameter. Therefore, to prevent excessive pressure on the intestine, the diaphragm injury lesion should be anchored retrosternally. However, the argument for the minimally invasive surgical technique still stands because this procedure is difficult [8].

To compliment this procedure, the method in which the diaphragm defect is sutured on the abdominal wall and the suture is fixed to the subcutaneous layer of the abdominal wall has been developed [9].

In the present case, the Morgagni hernia was treated by laparoscopy with a horizontal procedure without retrosternal anchoring. The surgery was successful. A horizontal procedure with laparoscopy to treat a Morgagni hernia is not a difficult method. However, follow up for cases of pregnancy and trauma, which cause an increase in abdominal pressure, is essential.

## REFERENCES

1. Comer TP, Clagett OT. *Surgical treatment of hernia of the foramen of Morgagni*. J Thorac Cardiovasc Surg 1966;52:461-8.
2. Lima M, Domini M, Libri M, Morabito A, Tani G, Domini R. *Laparoscopic repair of Morgagni-Larrey hernia in a child*. J Pediatr Surg 2000;35:1266-8.
3. Bortul M, Calligaris L, Gheller P. *Laparoscopic repair of a Morgagni-Larrey hernia*. J Laparoendosc Adv Surg Techn 1998;8:309-13.
4. Comer TP, Clagett OT. *Surgical treatment of hernia of the foramen of Morgagni*. J Thorac Cardiovasc Surg 1966;52:461-8.
5. Choi BJ, Yoo YK, Kim JG, Lee DH, Cheon JS, Jeong SK, Ahn CJ. *A case report and systemic analysis of articles for Morgagni diaphragmatic hernia*. J Korean Surg Soc 2005;69:353-7.
6. Hwang JJ, Kim DH, Lee YD, Kim KD. *Repair of Morgagni hernia through the abdominal approach - A case report -*. Korean J Thorac Cardiovasc Surg 2007;40:722-5.
7. Kilic D, Nadir A, Doner E, et al. *Transthoracic approach in surgical management of Morgagni hernia*. Eur J Cardiothorac Surg 2001;20:1016-9.
8. Minneci PC, Deans KJ, Kim P, Mathisen DJ. *Foramen of Morgagni hernia: changes in diagnosis and treatment*. Ann Thorac Surg 2004;77:1956-9.
9. Mallick MS, Alqahtani A. *Laparoscopic-assisted repair of Morgagni hernia in children*. J Pediatr Surg 2009;44:1621-4.