

Intrapericardial Implantation of an Implantable Cardioverter-Defibrillator in a Child

Yong Won Seong, M.D.*, Woong-Han Kim, M.D.*, Jae Suk Yoo, M.D.**,
Hye-seon Kim, M.D.*, Byoung-Ju Min, M.D.*, Young-Ok Lee, M.D.*

Implantable cardioverter defibrillator (ICD) can be a crucial therapeutic modality for pediatric patients with congenital heart disease, Brugada syndrome, long QT syndrome and cardiomyopathy. Because transvenous implantation of ICD is mostly unfeasible for pediatric patients due to anatomical and technical limitations, epicardial patch type or subcutaneous type ICD have been used. Implantation of these alternative ICDs, however, was reported to be frequently associated with significant complications. We report a case of successful intrapericardial implantation of a single coil-type ICD through the transverse sinus in a 27 month-old child weighing lesser than 10 kg, and it was inferred from this experience that this alternative technique may decrease complications and morbidities after ICD implantation in children.

Key words: 1. Congenital heart disease
2. Arrhythmia
3. Defibrillation
4. Pacemaker

CASE REPORT

A 27-month-old boy (body weight: 9.9 kg, Height: 84.9 cm), who had been on medication for dilated cardiomyopathy (DCMP) and long QT syndrome, underwent intrapericardial implantation of implantable cardioverter-defibrillator (ICD). He had first episode of ventricular fibrillation when he was 3 months old, which was successfully resuscitated in our emergency room (ER). He was transferred from other institute after recovering from recurrent attack of ventricular fibrillation 3 days prior to his visit to our ER. On arrival, his vital signs were within normal limits, but he showed intermittent brady-

cardia, down to 33 beat/minute, on Holter monitoring. His elder brother had died of DCMP-associated sudden death syndrome. Electrophysiologic study revealed that ventricular pacing induced polymorphic ventricular tachycardia (Fig. 1), and genetic study showed SCN5A gene mutation, which is believed to be linked to long QT syndrome or Brugada syndrome. Because the risk of recurrent ventricular tachycardia/fibrillation was deemed high, we elected to implant a DDD-type ICD for this patient. In the operating room, external defibrillator pad (zoll) was applied on the patient's back and general anesthesia was induced. Through median sternotomy pericardium was widely opened, and single-type

*Department of Thoracic and Cardiovascular Surgery, Seoul National University Hospital, Seoul National University College of Medicine

**Department of Thoracic and Cardiovascular Surgery, Seoul National University Bundang Hospital, Seoul National University College of Medicine

Received: July 24, 2010, Revised: September 20, 2010, Accepted: September 26, 2010

Corresponding author: Woong-Han Kim, Department of Thoracic and Cardiovascular Surgery, Seoul National University Hospital, Seoul National University College of Medicine, 28, Yeongeong-dong, Jongno-gu, Seoul 110-460, Korea
(Tel) 82-2-2072-3637 (Fax) 82-2-3672-3637 (E-mail) woonghan@snu.ac.kr

© The Korean Society for Thoracic and Cardiovascular Surgery. 2011. All right reserved.

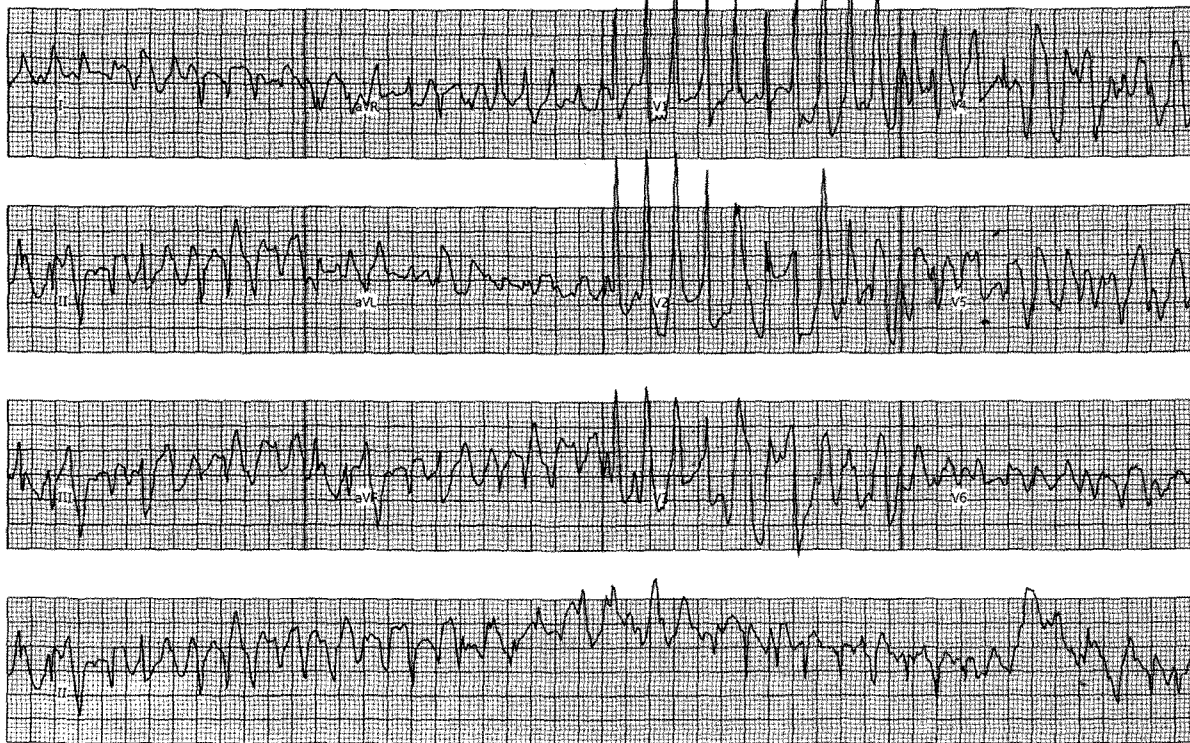© This is an open access article distributed under the terms of the Creative Commons Attribution Non-Commercial License (<http://creativecommons.org/licenses/by-nc/3.0>) which permits unrestricted non-commercial use, distribution, and reproduction in any medium, provided the original work is properly cited.

Age: 2 years
Gender:
Height: 85 cm

Weight: 9.7 kg
Vent rate (BPM): 202
RR (msec): 296

PR (msec): -19,943
QRS dur (msec): 115
QT/QTc (msec): 232/427

Display speed: 25 mm/sec
Display scale: 10 mm/mV



Cardiolab v6.5
GE medical systems

Fig. 1. Preoperative electrophysiologic study showing polymorphic ventricular tachycardia induced by single ventricular pacing.

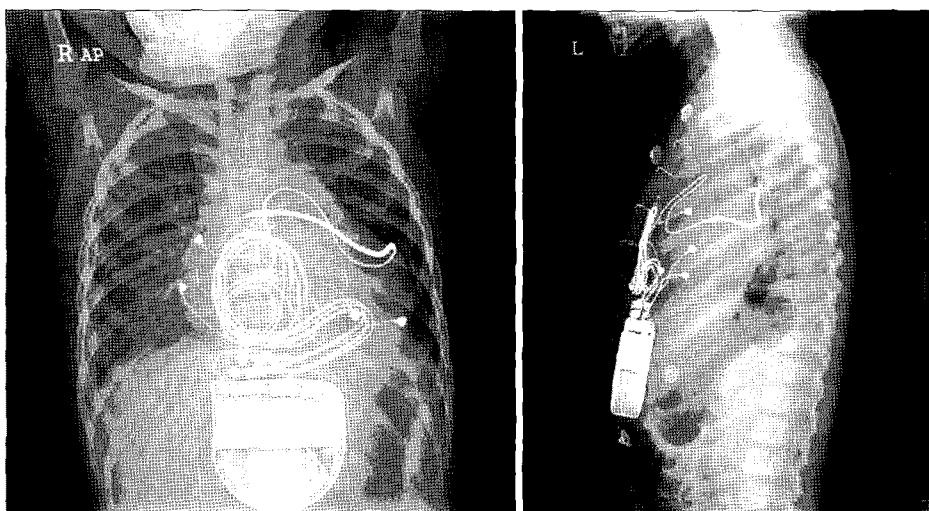


Fig. 2. Chest X-rays showing adequately positioned coil, electrodes and the ICD generator.

coil (Transvene™, model number: 6937, Medtronic Inc, Minneapolis, MN, USA) was introduced into the transverse sinus. After positioning the distal part of the coil in the junction between the superior vena cava and the left atrial roof, the coil was stabilized by three 4-0 black silk sutures. Then steroid-releasing bipolar extra-cardiac electrodes were fixed in the lateral wall of the right atrium and in the apices of both ventricles. From the lower end of the median sternotomy incision, a pouch was made in the right upper quadrant of the abdominal wall by bluntly dissecting the potential space between the rectus abdominis fascia and the peritoneum, and Dual-chamber ICD generator (Entrust D154VR; Medtronic Inc.) was inserted into this pouch after being connected with the coil and electrodes. Proper operation of the ICD was confirmed by successful defibrillation of induced ventricular fibrillation, and pacemaker was set at the minimal heart rate of 60 beats/min. Postoperative course was uneventful, and postoperative simple chest X-ray showed adequate positioning of the coil and the electrodes (Fig. 2). During the one year follow-up period, pacing threshold and ICD impedances were within an appropriate range (atrial pacing: 650 ohms, ventricular pacing: 800 ohms, ICD impedance: 54~55 ohms). There were two proper shocks for episodes of polymorphic ventricular tachycardia during the same time frame.

DISCUSSION

Implantable cardioverter defibrillator (ICD) can be a crucial treatment modality for pediatric patients with congenital heart disease, Brugada syndrome, long QT syndrome and various types of cardiomyopathy. Differing from adults, pediatric patients have limitations in receiving transvenous implantation of ICD because small body of this subset may not have room

for relatively large generator or coil. Furthermore, rapid somatic growth after ICD implantation frequently leads to electrode dislodgement with ICD malfunction [1]. For these reasons, epicardial patch type or subcutaneous type ICD have been used for children. Epicardial patch type ICD, however, has been reported to cause chest pain due to folding or wrinkling of the patch as time passes [2]. Subcutaneous type ICD also has drawbacks such as elevation of sensing threshold and dislodgement/fracture of the electrodes as the child grows up [3]. To alleviate these problems, intrapericardial coil implantation technique was proposed by Hsia et al [4]. They asserted that this technique could be performed with minimal skin incision without median sternotomy. In our case, we performed the procedure through median sternotomy because precise positioning of the coil and electrodes was thought to be more important than minimal incision, given that this patient required appropriate pacing for intermittent bradycardia as well as cardioversion-defibrillation for ventricular arrhythmia.

REFERENCES

1. Link MS, Hill SL, Cliff DL, et al. *Comparison of frequency of complications of implantable cardioverter-defibrillators in children versus adults.* Am J Cardiol 1999;83:263-6.
2. Molina JE, Benditt DG, Adler S. *Crinkling of epicardial defibrillator patches. A common and serious problem.* J Thorac Cardiovasc Surg 1995;110:258-64.
3. Kriebel T, Ruschewski W, Gonzalez MG, et al. *ICD implantation in infants and small children: the extracardiac technique.* Pacing Clin Electrophysiol 2006;29:1319-25.
4. Hsia TY, Bradley SM, LaPage MJ, et al. *Novel minimally invasive, intrapericardial implantable cardioverter defibrillator coil system: a useful approach to arrhythmia therapy in children.* Ann Thorac Surg 2009;87:1234-8.