

Video-assisted Thoracic Surgery Lobectomy

Kwhanmien Kim, M.D., Ph.D.*

Key words: 1. Video-assisted thoracic surgery
2. Lobectomy

DEFINITION

VATS lobectomy can be defined as lobectomy performed entirely under monitor-vision without rib spreading. It may be distinguished from 'minithoracotomy with video-assistance,' in which surgery is performed under direct vision via minithoracotomy using thoracoscopic illumination. 'Hybrid' VATS lobectomy differs from 'complete' VATS lobectomy in that a rib spreader is used in hybrid VATS lobectomy [1,2]. The same oncologic principles that are applied to open-thoracotomy lobectomy, such as complete anatomic resection with negative resection margin, and complete hilar and mediastinal lymph node dissection, are applied in VATS lobectomy for lung cancer.

INDICATIONS

The advantages of VATS lobectomy have been supported by many reports. VATS lobectomy can reduce postoperative pain, length of hospital stay, and occurrence of complications, as well as facilitate adjuvant chemotherapy [2-10]. Technological advances in thoracoscopic equipment and accumulation of experience with VATS lobectomy procedures have contributed to the expanded application of VATS lobectomy. The current recommended indications of VATS lobectomy are as follows.

1) Clinical stage I non-small cell lung cancer (NSCLCa)

VATS lobectomy was recommended as a standard procedure for the treatment of clinical stage I non-small cell lung cancer (NSCLCa) by the International Society of Minimally Invasive Cardiothoracic Surgery consensus statement in 2007 [11], by the American College of Chest Physicians evidence-based clinical practice guidelines in 2007 [12,13], and by the National Comprehensive Cancer Network (NCCN) guidelines in 2010 [14]. VATS lobectomy is most suitable for patients with small (under 5~6 cm in diameter) peripheral tumors without endobronchial lesions, and without visible pleural adhesions or anthracotic lymph nodes that are tightly adhered to pulmonary vessels.

2) Benign lung disease

Benign lung diseases requiring lobectomy include pulmonary aspergilloma, bronchiectasis, multi-drug resistant tuberculosis (MDRTB), and pulmonary sequestration and congenital cystic adenomatoid malformation (CCAM), etc. Weber et al reported successful application of VATS lobectomy for benign pulmonary disease for western population [15]. However, the most challenging issue when performing VATS lobectomy in Asian population for treatment of benign lung disease is pleural adhesion, because adhesions frequently accompany inflammatory changes in the pleural cavity.

*Department of Thoracic and Cardiovascular Surgery, Samsung Medical Center, Sungkyunkwan University, School of Medicine

Corresponding author: Kwhanmien Kim, Department of Thoracic and Cardiovascular Surgery, Samsung Medical Center, Sungkyunkwan University, School of Medicine, 50, Irwon-dong, Gangnam-gu, Seoul 135-710, Korea
(Tel) 82-2-3410-3485 (Fax) 82-2-3410-6986 (E-mail) kmkim0070@skku.edu

© The Korean Society for Thoracic and Cardiovascular Surgery. 2011. All right reserved.

© This is an open access article distributed under the terms of the Creative Commons Attribution Non-Commercial License (<http://creativecommons.org/licenses/by-nc/3.0>) which permits unrestricted non-commercial use, distribution, and reproduction in any medium, provided the original work is properly cited.

Furthermore, tight adhesion of inflamed lymph nodes to the pulmonary vessels is one of the most common causes of conversion into open-thoracotomy during VATS procedure [16]. Therefore, thorough evaluation of hilar structures by pre-operative enhanced chest CT is essential.

3) Expansion of indication of VATS lobectomy

As experience with VATS lobectomy gradually accumulates, VATS lobectomy has been applied in selected cases of N1 lung cancer, microscopic N2 lung cancer (including cases receiving preoperative chemotherapy), and lung cancer with endobronchial lesions that require sleeve resection [17-22]. Reported outcomes of these trials are comparable to those of open-thoracotomy lobectomy, indicating the need for prospective research.

CONTRAINDICATIONS

VATS lobectomy is not applicable for patients with advanced lung cancer, preoperative radiotherapy, or visible anastomotic lymph nodes that are adhered to pulmonary vessels and that impede anatomical dissection. VATS lobectomy is not indicated in patients who cannot sustain single lung ventilation due to poor pulmonary function. However, previous lung surgery, focal pleural adhesions, or incomplete interlobar fissures are not absolute contraindications of VATS lobectomy.

TECHNIQUES

1) Anesthesia and patient preparation

Single lung ventilation by double lumen endotracheal tube intubation is required for VATS lobectomy, as in open thoracotomy. In left side procedures, right-sided double lumen endotracheal intubation does not interfere in the manipulation of the left main bronchus, and facilitates subcarinal lymph node dissection. However, right-sided endotracheal tube might block the right upper lobar bronchus, so it must be well-positioned and maintained by experienced anesthesiologists. The patient is placed in the full lateral decubitus position, and bent downward around the hip to widen the intercostal space. Secure fixation is very important, because the patient can be tilted to both sides during the operation to retract the lung by

gravity.

2) Port placement

Two to four ports can be used according to the surgeon's preference, the experience of the surgeon and staff, and available endo-surgery equipment. Before thoracoscopic port placement, it is important to consider a few things as follows; ergonomically good position to handle the instruments, easiness to convert open thoracotomy in emergency, cosmetically good looking, and less postoperative pain. The first port for the thoracoscope is placed at the 7th or 8th intercostal space in the mid-axillary line, and the pleural space is inspected. A working window of 4~5 cm in length is placed at the 5th or 6th ICS in the mid-clavicular line. Specially-designed wound retractors are commercially available to enhance instrument handling and prevent wound contamination. An additional port is made at the 7th ICS in the post-scapular line. This port configuration guarantees safe and prompt conversion to open-thoracotomy in emergent situations by connecting the working window and the posterior port. Simply by changing the thoracoscope port and applying appropriate maneuvers, all lobes can be accessed by this three-port configuration without major modifications. However, it is left solely to the surgeon's preference to decide where to stand, where to place the thoracoscope, and whether to change the thoracoscope port or to use a fixed port. The most important consideration is to avoid competing with assistant's instruments ("no hand cross-over" technique). We recommend standing on the right side of the operating table because it allows smooth right-hand movement. When doing left side VATS lobectomy, a 10 mm port for the thoracoscope is placed at the 7th intercostal space in the posterior scapular line, and fissure development and subcarinal approach can easily be accomplished without disturbance by the thoracoscope.

3) Approach and sequence of dissection

In the technique of VATS lobectomy introduced by McKenna and D'Amico, hilar structures (the lobar pulmonary vein, artery and bronchus) are sequentially divided from the hilum (the so-called 'hilar approach' or 'single directional approach') [23-25].

Advantage of this approach is that it avoids fissure division

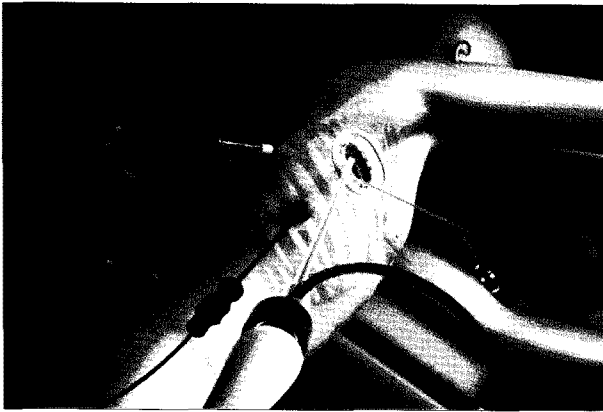


Fig. 1. Port placement for right side VATS lobectomy. Thoracoscope is introduced through working window.

and consequent reduction of air leaks. A good understanding of anatomic structures of the lung and surgical experience are required for this approach.

VATS lobectomy can be performed in the same order and technique as conventional open-thoracotomy lobectomy. In lung cancer surgery, hilar structures are usually divided in the order of pulmonary vein, pulmonary artery, and bronchus. By dividing the pulmonary vein first, it is easy to manipulate the artery, and tumor dissemination into the bloodstream during manipulation of the lung may be prevented.

4) Right upper lobectomy

The example of right side port placement was illustrated in Fig. 1. It is important to assess the condition of the fissure when selecting the approach. We recommend starting from the hilum by opening the parietal pleura covering the hilar structures from the middle lobar vein up to the azygos vein, and then inserting the endo-vascular stapler (white cartridge) through the inferior port to divide the upper lobar branch of the superior pulmonary vein. When dividing the pulmonary vessels, careful release of the perivascular sheath is critical to secure sufficient space for stapler passage, while incomplete release makes stapling difficult and increases the risk of bleeding. Traction of vessels with tapes or rubber bands can be helpful, but is not necessary when the vessels are fully released. Applying lubricant jelly around the stapler head may help smooth passage.

After dividing the upper lobar vein, the anterior trunk of

the right pulmonary artery is carefully released and divided by the endo-vascular stapler (with gray or white cartridge). The posterior ascending artery is then divided using 5 mm interlocking clips. If this branch can be approached from the hilar side, fissure division is easily accomplished by staplers after bronchial division, even if it is not completely developed. However, when the posterior ascending branch is inaccessible from the hilum, it should be divided after major fissure development.

After the vessels of the right upper lobe are divided, peribronchial tissues, including lymph nodes around the right upper lobar bronchus, are dissected and the bronchus is divided with the endo-stapler. A 4.8 mm thickness (green cartridge) stapler that is longer than 45 mm in length is recommended for bronchial division, because the use of smaller staplers can increase the risk of stump failure due to incomplete stapling.

To pull out the resected lobe, surgical rubber gloves or commercially-available plastic bags are used. The specimen must be very cautiously pulled out so as not to tear off the retrieval bag. Lubricant jelly can be applied at the rim of the working window to aid extraction.

The remaining bronchial stump must be confirmed to be securely closed by the air leak test. The inferior pulmonary ligament is divided to promote expansion of the remaining lobes. Additional mediastinal lymph node dissection is then performed (it will be discussed in the next chapter). After irrigating the pleural space with normal saline, the patient must be checked for bleeding, expansion and position of remaining lobes, and position of the chest tube that is inserted through the inferior port. If there is any concern regarding bending or torsion of the right middle lobar bronchus, the middle lobe should be anchored to the lower lobe with one or two stitches. Fig. 2 demonstrate bronchoscopic findings and CT images that show narrowing of the right middle lobar bronchus after right upper lobectomy.

5) Right middle lobectomy

The same port placement is used for right middle lobectomy as for right upper lobectomy. The extent of fissure separation is directly related to the difficulty and approach of operation. Once the right middle lobar branch of superior pulmonary vein is released from the hilar side, fissures must be

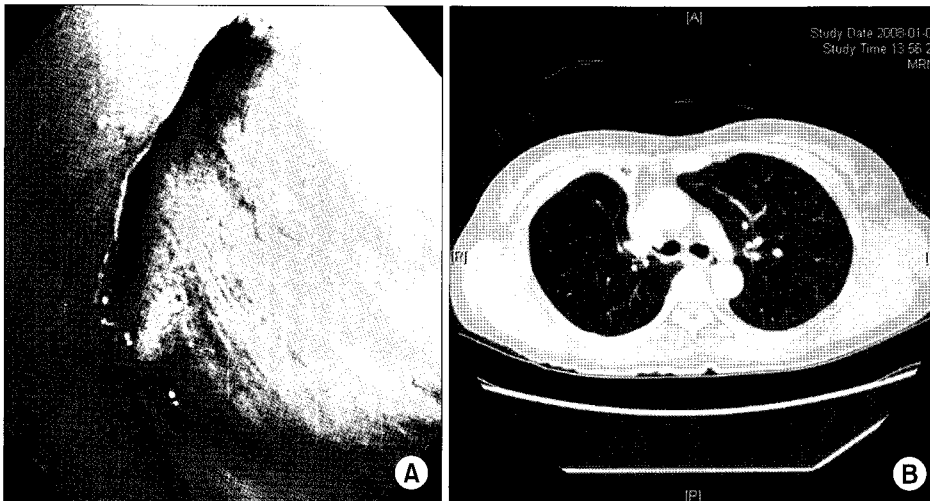


Fig. 2. (A) Bronchoscopic findings of the right middle lobar bronchus narrowing which occurred after VATS right upper lobectomy. (B) Chest CT shows slit-like narrowed right middle lobar bronchus.

developed between the right middle lobe and other lobes to identify the pulmonary artery. The right middle lobar pulmonary artery can be safely accessed after full division of the fissure between the right upper lobe and middle lobe. If the development of this fissure is incomplete, more attention must be paid to the course of the right middle lobar branch of the pulmonary vein before dividing the fissure with an endo-stapler. Aberrant branches in the fissure can be sacrificed. Port selection for the endo-stapler is very important when developing fissures, because the entrance angle of the stapler is determined by the course of the fissure. Fissural vessels such as the right posterior ascending artery, superior segmental artery, and lateral and medial segmental arteries of the right middle lobe must be clearly identified and released. After the fissures and vessels are fully released, the middle lobar arteries are divided with endovascular staplers (over 35 mm, white cartridge), interlocking clips, or the silk tie method. Because the right middle lobar bronchus is short and narrow compared to other bronchi, 30~35 mm endostaplers (blue cartridge) are recommended. The resected lobe is extracted in the same way as for the right upper lobe.

6) Right lower lobectomy

The inferior pulmonary ligament is first divided, and then the right inferior pulmonary vein is isolated. After major fissure development, the basilar trunk and superior segmental branch of the right pulmonary artery are identified and released. The pulmonary arteries can be divided either before

or after the pulmonary vein. The endovascular stapler (30~45 mm, white cartridge) is again used for division of vessels. The right lower basilar trunk and superior segmental branch can be divided together with one stapling, if this does not compromise the posterior ascending branch. These segmental branches can also be divided separately with the silk tie method, interlocking clips or endovascular staplers.

Prevention of narrowing of the right middle lobe bronchial orifice is very important when dividing the right lower lobar bronchus [26,27]. Thus, the bronchial stapling of lower lobar bronchus must be made parallel to the direction of the right middle lobar bronchus, and the right lower lobe can be lifted superiorly to help achieve an appropriate entry angle. Bronchoscopic confirmation by the anesthesiologist is also helpful.

7) Left upper lobectomy

In left sided VATS lobectomy, we recommend using a right-sided double lumen endobronchial tube, because the use of a left-sided tube makes bronchial manipulation and subcarinal lymph node dissection much more difficult. Port placement in left-sided VATS lobectomy is the same as in right-sided VATS lobectomy, except that a 10 mm trocar is used in the posterior port for thoracoscope insertion (Fig. 3).

If the interlobar fissure is completely developed, the superior pulmonary vein and branches of the pulmonary artery can be divided separately. If the interlobar fissure is not completely developed, the hilar approach is recommended.

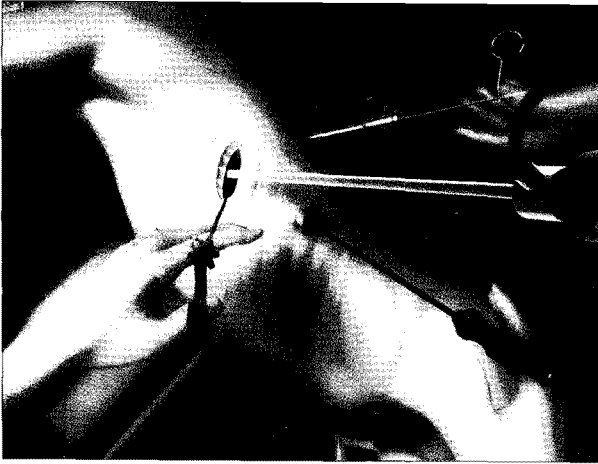


Fig. 3. Port placement for left side VATS lobectomy. Thoracoscope is introduced through working window and a peanut holder for lung retraction is inserted through 10 mm back port. Thoracoscope may be introduced through the back port whenever it is necessary.

The anterior aspect of the hilum is exposed by tilting the operating table to the left and pulling the left lung backward with a lung retractor. The left superior pulmonary vein and left anterior trunk are sequentially divided with an endovascular stapler (35~45 mm, white cartridge).

In the hilar approach, the left upper lobar bronchus is divided with an endo-stapler (45 mm, green cartridge), and the other left upper lobar segmental branches of pulmonary artery are then divided with clips or ties. Finally, the remaining fissure is separated with an endostapler (45~60 mm, green cartridge).

Using the same approach as thoracotomy lobectomy, the operating table is tilted to the right to promote anterior traction of the left upper lobe. After fissure separation, the remaining segmental branches are divided with an endovascular stapler, clips, or silk ligation. The left upper lobar bronchus is divided last with an endostapler (45~60 mm, green cartridge). The remaining bronchial stump must be positioned parallel to the left lower lobar pulmonary artery trunk. If not, the remaining stump may compress the lower lobar trunk and cause pulmonary infarction.

Specimen retraction, irrigation of the pleural space, and the air leak test are performed in the same manner as described above.

8) Left lower lobectomy

The approach is the same as that for left upper lobectomy. If the fissure is incomplete, the single direction method can be used, starting from the inferior pulmonary ligament to the hilum.

First, the operating table is tilted to the right to expose the posterior aspect of the left lung. The inferior pulmonary ligament is divided, and the lymph nodes are dissected. After isolating the left inferior pulmonary vein, the mediastinal pleura is opened posteriorly and superiorly up to the level of the aortic arch, to expose the left lower lobar bronchus and superior segmental artery. The vagus nerve and its branches must be identified and saved. The inferior pulmonary vein is divided with an endovascular stapler. The operating table is then tilted to the left to move the left lung posteriorly, the fissure is separated, and the segmental branches of the lower lobar artery are divided. Sometimes the basilar trunk and superior segmental artery can be divided together with one endovascular stapler (35~45 mm, gray or white cartridge).

If the lingular segmental bronchus is secured, the process of lower lobar bronchial division is the same with that for other lobes. The other procedure is performed as described above.

MEDIASTINAL LYMPH NODE DISSECTION

It is critical to achieve surgical completeness, which includes mediastinal lymph node dissection (MLND). The question of whether MLND improves survival remains controversial [28-30]. However, MLND is considered essential for accurate pathologic staging [31]. Complete lymph node dissection can be defined as removal of all lymph nodes and fat tissues from each nodal station [32]. It must be determined that complete node dissection is really possible by VATS before expanding the indication of VATS lobectomy in lung cancer; this hypothesis is supported by many recent reports [31]. Sugi and Watanabe found that the numbers of lymph nodes removed by VATS were comparable to those removed by thoracotomy, and that survival and recurrence were also comparable [33-35]. Sagawa et al. performed VATS MLND and opened the chest to check its completeness. They found that only 2~3% of lymph nodes remained, and concluded

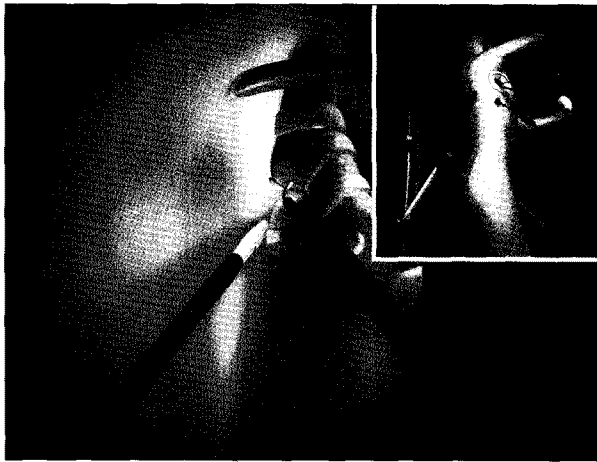


Fig. 4. Subcarinal lymph node dissection, which is facilitated with tilting the operating table to the left side and retraction of the right lung.

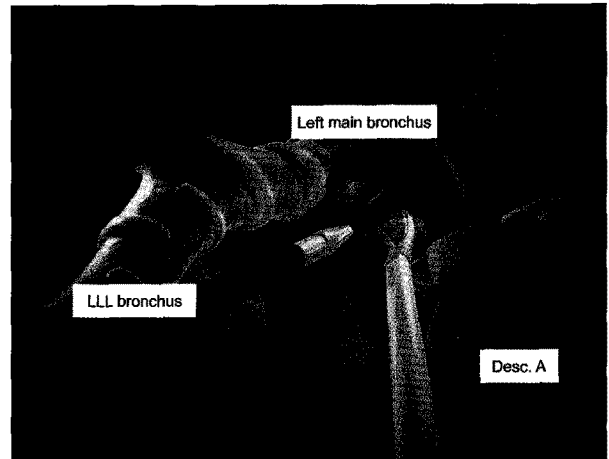


Fig. 6. Posterior approach for subcarinal lymph node dissection after VATS left lower lobectomy. Desc=A: descending aorta.

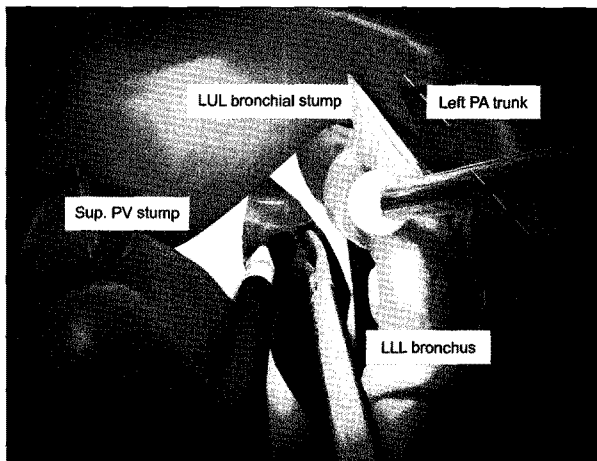


Fig. 5. Anterior approach for subcarinal lymph node dissection after VATS left upper lobectomy. Sup. PV=Superior pulmonary vein.

that VATS MLND is not inferior to MLND by thoracotomy [36]. Therefore, thoracoscopic lymph node dissection is technically feasible, and does not violate the oncologic principle. However, more evidence is required to extend the indication of VATS lobectomy from stage I lung cancer to more advanced disease. VATS lobectomy can be tried in carefully selected cases of N1 lung cancer without signs of extranodal invasion, but the open technique is still recommended in cases of more advanced disease.

Basically, the technique of thoracoscopic lymph node dissection is almost the same as that of the open technique, but

can vary according to the position of the scope, presence of working window, the thoracoscopic instruments used, and the adequacy of surgical view by scope. During dissection, special attention is required not to crush harvested nodes and prevent possible tumor dissemination. Releasing the mediastinal space during mediastinoscopic lymph node screening prior to lobectomy can be helpful. However, if bleeding occurs it may worsen the surgical view.

1) Right side mediastinal lymph node dissection

The parietal pleura around the azygos vein is opened, and the superior vena cava (SVC) is retracted anteriorly. All fat tissues at the right side of the trachea are removed *en bloc*, from the subclavian and innominate arteries to the right main pulmonary artery (PA) and anterior subcarinal area, to visualize the pericardial surface. The vagus nerve, right recurrent laryngeal nerve, thymus, and right main pulmonary artery must be carefully identified and saved. Ultrasonic devices such as Harmonic[®] scalpels are useful to reduce the occurrence of lymphatic leaks after dissection and to prevent post-operative chylothorax.

When dividing the inferior pulmonary ligament (IPL), the IPL lymph node can be removed. Care must be taken to control bleeding from all minute vessels.

The subcarinal space can be best exposed by tilting the operating table to the left and pushing the right lung anteriorly with a lung retractor. The parietal pleura is then opened,

avoiding injury to the vagus nerve. The subcarinal nodes can be removed *en bloc* starting inferiorly and moving upward using electrocautery and the Harmonic[®] scalpel. The subcarinal space can be reached by an anterior approach if clear dissection is difficult from behind (Fig. 4).

2) Left side mediastinal lymph node dissection

Complete left side MLND is technically more challenging than right side MLND due to the difficulty of obtaining an adequate view of the left paratracheal and subcarinal spaces, and requires appropriate division of the adjacent tissues (e.g., vagus nerve branches, bronchial arteries, and lymphatic ducts) as well as effective retraction of the lung and bronchus.

The mediastinal pleura is opened from the left phrenic nerve to the subaortic area. The left vagus nerve and recurrent laryngeal nerve must be identified and saved. All fat tissues and lymph nodes are removed *en bloc*. The lymph nodes and tissues around the left tracheobronchial area are dissected.

It is better to approach the subcarinal area anteriorly after left upper lobectomy, and posteriorly after left lower lobectomy. For the anterior approach after left upper lobectomy, the left pulmonary artery trunk and main bronchus are lifted upward, the stump of the superior pulmonary vein is pushed aside, and the inferior pulmonary vein is pulled downward (Fig. 5). Right-sided double lumen intubation is recommended to lift the left main bronchus effectively. After left lower lobectomy, the subcarinal space is exposed via the usual posterior approach. The descending aorta and esophagus are retracted posteriorly, while the left main bronchus is retracted anteriorly. Port selection for the appropriate retractors is important (Fig. 6).

REFERENCES

- Rocco G, Internullo E, Cassivi SD, Van Raemdonck D, Ferguson MK. *The variability of practice in minimally invasive thoracic surgery for pulmonary resections*. Thorac Surg Clin 2008;18:235-47.
- Lewis RJ, Caccavale RJ, Bocage JP, Widmann MD. *Video-assisted thoracic surgical non-rib spreading simultaneously stapled lobectomy: a more patient-friendly oncologic resection*. Chest 1999;116:1119-24.
- Lewis RJ, Caccavale RJ, Sisler GE, Mackenzie JW. *Video-assisted thoracic surgical resection of malignant lung tumors*. J Thorac Cardiovasc Surg 1992;104:1679-85; discussion 85-7.
- Nagahiro I, Andou A, Aoe M, Sano Y, Date H, Shimizu N. *Pulmonary function, postoperative pain, and serum cytokine level after lobectomy: a comparison of VATS and conventional procedure*. Ann Thorac Surg 2001;72:362-5.
- Shigemura N, Akashi A, Funaki S, et al. *Long-term outcomes after a variety of video-assisted thoracoscopic lobectomy approaches for clinical stage IA lung cancer: a multi-institutional study*. J Thorac Cardiovasc Surg 2006;132:507-12.
- Yim AP, Wan S, Lee TW, Arifi AA. *VATS lobectomy reduces cytokine responses compared with conventional surgery*. Ann Thorac Surg 2000;70:243-7.
- Flores RM, Park BJ, Dycoco J, et al. *Lobectomy by video-assisted thoracic surgery (VATS) versus thoracotomy for lung cancer*. J Thorac Cardiovasc Surg 2009;138:11-8.
- Nicasri DG, Wisnivesky JP, Little VR, et al. *Thoracoscopic lobectomy: report on safety, discharge independence, pain, and chemotherapy tolerance*. J Thorac Cardiovasc Surg 2008;135:642-7.
- Tomaszek SC, Cassivi SD, Shen KR, et al. *Clinical outcomes of video-assisted thoracoscopic lobectomy*. Mayo Clin Proc 2009;84:509-13.
- Farjah F, Wood DE, Mulligan MS, et al. *Safety and efficacy of video-assisted versus conventional lung resection for lung cancer*. J Thorac Cardiovasc Surg 2009;137:1415-21.
- Lee LS, Daniel J. *Highlights from the 11th Annual Scientific Meeting of the International Society for Minimally Invasive Cardiothoracic Surgery*. J Thorac Cardiovasc Surg 2008;136:1107-9.
- Scott WJ, Howington J, Feigenberg S, Movsas B, Pisters K. *Treatment of non-small cell lung cancer stage I and stage II: ACCP evidence-based clinical practice guidelines (2nd edition)*. Chest 2007;132:234S-42S.
- Alberts WM. *Diagnosis and management of lung cancer executive summary: ACCP evidence-based clinical practice guidelines (2nd Edition)*. Chest 2007;132:1S-19S.
- National Comprehensive Cancer Network. NCCN Guidelines TM Version 2.2011 Non-Small Cell Lung Cancer. Available at: <http://www.nccn.org>
- Weber A, Stammberger U, Inci I, Schmid RA, Dutly A, Weder W. *Thoracoscopic lobectomy for benign disease—a single centre study on 64 cases*. Eur J Cardiothorac Surg 2001;20:443-8.
- Park JS, Kim HK, Choi YS, Kim J, Shim YM, Kim K. *Unplanned conversion to thoracotomy during video-assisted thoracic surgery lobectomy does not compromise the surgical outcome*. World J Surg 2010.
- Kim HK, Choi YS, Kim J, Shim YM, Kim K. *Outcomes of unexpected pathologic N1 and N2 disease after video-assisted thoracic surgery lobectomy for clinical stage I*

- non-small cell lung cancer*. J Thorac Cardiovasc Surg 2010;140:1288-93.
18. Shiraishi T, Hiratsuka M, Yoshinaga Y, Yamamoto S, Iwasaki A, Shirakusa T. *Thoracoscopic lobectomy with systemic lymph node dissection for lymph node positive non-small cell lung cancer--is thoracoscopic lymph node dissection feasible?* Thorac Cardiovasc Surg 2008;56:162-6.
 19. Kim K, Kim HK, Park JS, et al. *Video-assisted thoracic surgery lobectomy: single institutional experience with 704 cases*. Ann Thorac Surg 2010;89:S2118-22.
 20. Shaw JP, Dembitzer FR, Wisnivesky JP, et al. *Video-assisted thoracoscopic lobectomy: state of the art and future directions*. Ann Thorac Surg 2008;85:S705-9.
 21. Shao WL, Liu LX, He JX, et al. *Bronchial sleeve resection and reconstruction of pulmonary artery by video-assisted thoracic small incision surgery for central lung cancer: a report of 139 cases*. Zhonghua Wai Ke Za Zhi 2007;45:1530-2.
 22. Nakanishi K. *Video-assisted thoracic surgery lobectomy with bronchoplasty for lung cancer: initial experience and techniques*. Ann Thorac Surg 2007;84:191-5.
 23. McKenna RJ, Houck W, Fuller CB. *Video-assisted thoracic surgery lobectomy: Experience with 1,100 cases*. Ann Thorac Surg 2006;81:421-6.
 24. Swanson SJ, Herndon JE, D'Amico TA, et al. *Video-assisted thoracic surgery lobectomy: Report of CALGB 39802 - A prospective, multi-institution feasibility study*. J Clin Oncol 2007;25:4993-7.
 25. Balsara KR, Balderson SS, D'Amico TA. *Surgical techniques to avoid parenchymal injury during lung resection (fissureless lobectomy)*. Thorac Surg Clin 2010;20:365-9.
 26. Cable DG, Deschamps C, Allen MS, et al. *Lobar torsion after pulmonary resection: presentation and outcome*. J Thorac Cardiovasc Surg 2001;122:1091-3.
 27. Purohit M, Zacharias J. *A simple reproducible method of preventing lobar torsion*. J Cardiothorac Surg 2008;3:22.
 28. Izbiicki JR, Passlick B, Pantel K, et al. *Effectiveness of radical systematic mediastinal lymphadenectomy in patients with resectable non-small cell lung cancer: results of a prospective randomized trial*. Ann Surg 1998;227:138-44.
 29. Naruke T, Tsuchiya R, Kondo H, Nakayama H, Asamura H. *Lymph node sampling in lung cancer: how should it be done?* Eur J Cardiothorac Surg 1999;16(Suppl 1):S17-24.
 30. Keller SM, Adak S, Wagner H, Johnson DH. *Mediastinal lymph node dissection improves survival in patients with stages II and IIIa non-small cell lung cancer. Eastern Cooperative Oncology Group*. Ann Thorac Surg 2000;70:358-65; discussion 65-6.
 31. D'Amico TA. *Videothoracoscopic mediastinal lymphadenectomy*. Thorac Surg Clin 2010;20:207-13.
 32. Rami-Porta R, Wittekind C, Goldstraw P. *Complete resection in lung cancer surgery: proposed definition*. Lung Cancer 2005;49:25-33.
 33. Sugi K, Kaneda Y, Esato K. *Video-assisted thoracoscopic lobectomy achieves a satisfactory long-term prognosis in patients with clinical stage IA lung cancer*. World J Surg 2000;24:27-30; discussion -1.
 34. Watanabe A, Mishina T, Ohori S, et al. *Is video-assisted thoracoscopic surgery a feasible approach for clinical N0 and postoperatively pathological N2 non-small cell lung cancer?* Eur J Cardiothorac Surg 2008;33:812-8.
 35. Watanabe A, Koyanagi T, Ohsawa H, et al. *Systematic node dissection by VATS is not inferior to that through an open thoracotomy: a comparative clinicopathologic retrospective study*. Surgery 2005;138:510-7.
 36. Sagawa M, Sato M, Sakurada A, et al. *A prospective trial of systematic nodal dissection for lung cancer by video-assisted thoracic surgery: can it be perfect?* Ann Thorac Surg 2002;73:900-4.