

## Pulsed Radiofrequency Treatment of Pain Relieving Point in a Soft Tissue

<sup>1</sup>Department of Anesthesiology and Pain Medicine, <sup>2</sup>Anesthesia and Pain Research Institute, Yonsei University College of Medicine, Seoul, Korea

Jeong Soo Lee, MD<sup>1,2</sup>, Kyung Bong Yoon, MD<sup>1,2</sup>, In Ki Kim, MD<sup>1</sup>, and Duck Mi Yoon, MD<sup>1,2</sup>

Pulsed radiofrequency (PRF) treatment of nervous tissue has been proposed as a less neurodestructive technique alternative to continuous RF heat lesioning. Recently, clinical reports using PRF have shown favorable effects in the treatment of a variety of focal pain areas, even in non-nervous tissues; however, the mechanism of effect underlying this treatment to non-nervous tissue remains unclear. We report the case of a 67-year-old male who presented with pain relieving point in the posterior neck. The patient had pain in the posterior neck for 3 years. The pain subsided with pressure applied to a point in the posterior neck. There were no specific abnormal findings on laboratory testing and radiologic examinations. After PRF treatment to the pain-relieving point, he had pain relief which lasted more than 5 months. (Korean J Pain 2011; 24: 57-60)

### Key Words:

pain relieving point, pulsed radiofrequency, soft tissue.

Radiofrequency (RF) neurotomy using thermal energy to nervous tissue has been used for more than 30 years to treat pain conditions from a variety of causes. Pain relief is thought to result from neurodestruction from thermal coagulation and blocking nociceptive input [1]. Recently, it has been hypothesized that pain relief after RF neurotomy results not from destruction of nervous tissue, but from strong electric fields induced by voltage fluctuations in the area of treatment [2]. Unlike continuous RF treatment, pulsed radiofrequency (PRF) treatment using a 20-msec burst, followed by a 480-msec rest period at a lower temperature, has been reported as an effective pain

treatment modality with less neurodestruction.

In addition to neurotomy, radiofrequency ablation (RFA) for destruction of tumor tissue and pain control is widely used for cancer patients [3,4]. It has been reported that an application of RF to a trigger point in soft tissue results in a good outcome of pain control [5]. Thus, RF is becoming more common as a treatment modality for pain control for various reasons.

We report a case of pain control of the posterior neck through PRF at a pain-relieving point, and review the related literature.

Received December 1, 2010. Revised January 4, 2011. Accepted January 7, 2011.

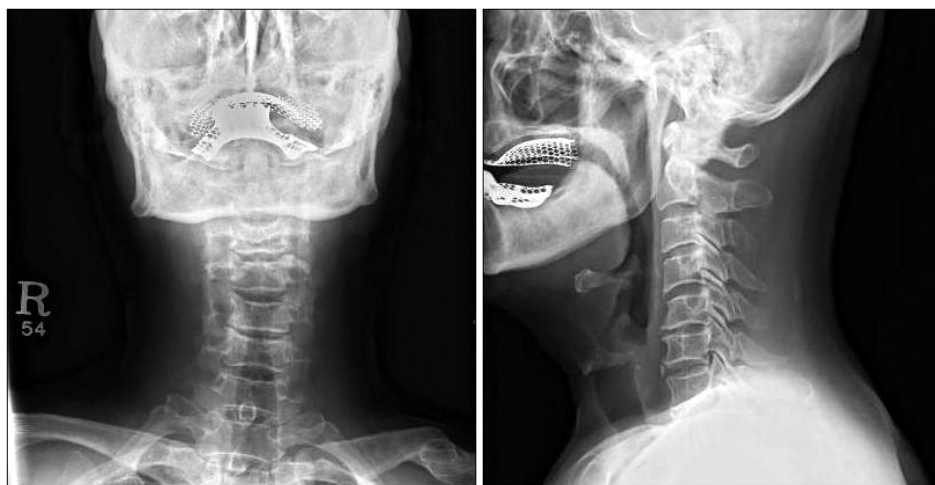
Correspondence to: Duck Mi Yoon, MD

Department of Anesthesiology and Pain Medicine, Yonsei University College of Medicine, 134, Sinchon-dong, Seodaemun-gu, Seoul 120-752, Korea

Tel: +82-2-2228-2420, Fax: +82-2-312-7185, E-mail: dmyoon@yuhs.ac

© This is an open-access article distributed under the terms of the Creative Commons Attribution Non-Commercial License (<http://creativecommons.org/licenses/by-nc/3.0/>), which permits unrestricted non-commercial use, distribution, and reproduction in any medium, provided the original work is properly cited.

Copyright © The Korean Pain Society, 2011



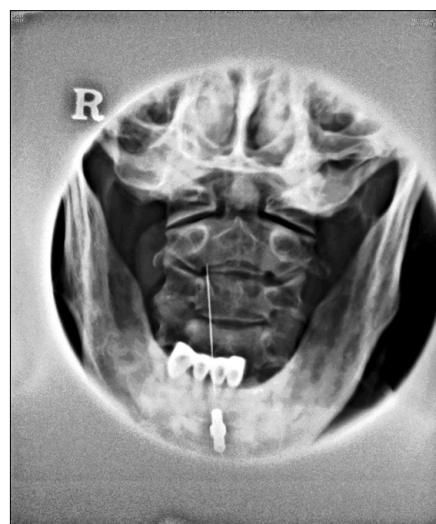
**Fig. 1.** The radiologic images of patient's cervical spine. There was no abnormal bone structure, only degenerative change.

### CASE REPORT

We evaluated a 67-year-old man with a 3-year history of posterior neck pain and headache with vertigo that resulted from a head injury sustained in an accident. The medical and family histories were negative for headaches. There were no significant findings on a brain magnetic resonance (MR) image immediately after the accident and a brain MR angiographic image 1 year after the accident. A neurosurgeon referred him to our pain clinic for pain control after confirming normal findings of a computed tomography scan of the temporal bone and cerebellopontine angle cistern.

The chief complaint was posterior neck pain which continued all day except while at work. There was a pain-relieving point in the posterior neck area that reduced the pain when he applied pressure with his finger. He rated his pain as 3–4/10 using a 0–10 numerical rating scale. The physical examination revealed that there was no mass-like lesion in the neck area and no pain related to neck motion. There was only degenerative changes in the simple X-ray image of cervical spine (Fig. 1). Vertigo with headaches began after the accident and occurred approximately 4 times a day and lasted 5 minutes. Nausea accompanied the vertigo, but there was no loss of consciousness. There were no aggravating or relieving factors related to the vertigo. He had tinnitus and fullness in his left ear.

With a diagnosis of cervicogenic headaches, he underwent C2 dorsal root ganglion and third occipital nerve blocks with 2 ml of 0.5% lidocaine and 10 mg of tri-



**Fig. 2.** Pulsed radiofrequency needle placement of the imaged cervical area. Open mouth view. The needle depth in the soft tissue of posterior neck was about 1 cm.

amcinolone at each site guided by radiologic imaging. Infiltration of local anesthetics near the pain-relieving point was done. He was treated with medication for true vertigo with a diagnosis of Meniere's syndrome. Five days later, the headaches improved, but the posterior neck pain persisted. The injection of local anesthetics had a temporary effect. Thus, 10 days after the 1<sup>st</sup> visit, after explaining the procedure, efficacy, and side effects of PRF, we placed the patient in a prone position. Under radiologic image guiding, the pain-relieving point in the soft tissue of the posterior neck was between the 2<sup>nd</sup> and 3<sup>rd</sup> cervical vertebrae, 1.5 cm from the midline. The 8-cm RF electrode

with a 5-mm active tip was advanced to the pain-relieving point at a depth of 1 cm (Fig. 2). After clarifying the location of the pain-relieving point through test stimulation with 50 Hz and 0.5 mA that shows concordant pain as usual, we performed PRF for 120 seconds at 40°C. Immediately after the procedure, the patient rated his pain in the posterior neck as 0/10 using a 0–10 numerical rating scale. Eleven days after the PRF procedure, relief of headache and posterior neck pain was maintained with slight dizziness. The patient reported continued relief of headache and posterior neck pain by telephone follow-up for 5 months.

## DISCUSSION

Unlike conventional RF treatment with continuous thermal energy, PRF treatment using high-voltage energy (usually 45 V) at a 20-msec burst, followed by a 480-msec rest period at a less neurodestructive temperature not to exceed 42°C, has been reported as an effective pain treatment modality.

The mechanism of PRF without the significant heat-induced tissue damage is debatable. A popular theory is that the rapidly changing electronic fields produced by PRF alter the transmission of pain signal via a pathway involving c-Fos. Previous study has shown that PRF increased c-Fos expression in the dorsal horn, a response that was sustained as long as 7 days after treatment [6]. This result also hinted at the inhibition of excitatory C fibers and long term depression.

Since previous studies have reported the effects of PRF with a lower complication rate, the application of PRF is increasing, even on the non-nervous tissues. RF ablation applied to non-nervous tissue aims to destroy target tissues; however, the indication is very limited. It is necessary to maintain a temperature of 60–100°C to achieve complete ablation of the soft tissue, especially tumor. For osteoid osteomas resulting in severe pain, tumors less than 15 mm in size are not appropriate for surgery and are generally treated with RFA. For metastatic bone tumors, the treatment of choice is radiotherapy. However, recurrent pain after radiotherapy could be treated with RFA [4]. The mechanism of pain relief after RFA is not well-understood. In a previous study, possible mechanisms of pain relief of tumors after RFA include the following: destruction of sensory nerves of periosteum, thus blocking the transmission

of pain; decreased stimulation to sensory nerve endings by reduction of tumor volume; and direct destruction of tumor cells secreting cytokines, resulting in stimulation of nerve endings [7]. The application of RFA for soft tissue tumors has been limited because the safety and efficacy of RF in the treatment of soft tissue tumors has not been investigated systematically. However, there are some case reports involving patients with soft tissue tumors have been treated with RFA and shown a good response [8].

Tamini et al. treated nine patients with myofascial trigger points and scar neuromas [5]. In 8 of 9 patients, a 75–100% reduction of pain was achieved immediately after the PRF procedure at tender points. In 6 of 9 patients, pain relief was sustained over 6 months. The authors suggest that PRF of the trigger point could be a minimally invasive, less effective method to control pain. The patient with a more diffuse painful condition shows a less effective response. The effects of PRF have limits for the treatment field. This result is consistent with the previous theory that the neuromodulatory effect of PRF is derived from the voltage change of nervous cell membranes near the needle tip.

This patient had an unusual pain-relieving point measuring 1.5 × 1.5 cm that resulted in relief of the posterior neck pain with pressure. The pain-relieving point differed from a trigger point that results in severe pain with pressure. Trigger points are discrete, very sensitive areas of skeletal muscle that contain palpable, taut bands of muscle. At the point that it showed unusual pain aspect with pressure, we elected to use PRF in the treatment of focal pain having a pain-relieving point.

We performed PRF after clarifying the location of the pain-relieving point through test stimulation with 50 Hz and 0.5 mA that shows concordant pain as usual. We thought that the placement of electrode tip was in a subcutaneous tissue. Because, the 8 cm RF electrode with a 5 mm active tip was advanced to the pain-relieving point at a depth of 1 cm without bone touch or fascial click. Considering the formation of electric field by PRF electrode, PRF lesion could be located in front of electrode. Therefore, the possibility that PRF lesion could be placed at the fascia or periosteum cannot be excluded.

Although we have observed positive results from PRF treatment, knowledge of the precise mechanism and technique remains elusive. It is clear that the PRF procedure to soft tissues has limited theoretical background and clin-

ical outcomes. Notwithstanding the shortcomings of this report, the positive response demonstrated through this review suggests that further systemic evaluation of this treatment approach is warranted.

## REFERENCES

1. Van Zundert J, Raj P, Erdine S, van Kleef M. Application of radiofrequency treatment in practical pain management: state of the art. *Pain Pract* 2002; 2: 269–78.
2. Cosman ER Jr, Cosman ER Sr. Electric and thermal field effects in tissue around radiofrequency electrodes. *Pain Med* 2005; 6: 405–24.
3. Locklin JK, Mannes A, Berger A, Wood BJ. Palliation of soft tissue cancer pain with radiofrequency ablation. *J Support Oncol* 2004; 2: 439–45.
4. Ahrar K. The role and limitations of radiofrequency ablation in treatment of bone and soft tissue tumors. *Curr Oncol Rep* 2004; 6: 315–20.
5. Tamimi MA, McCeney MH, Krusch J. A case series of pulsed radiofrequency treatment of myofascial trigger points and scar neuromas. *Pain Med* 2009; 10: 1140–3.
6. Van Zundert J, de Louw AJ, Joosten EA, Kessels AG, Honig W, Dederen PJ, et al. Pulsed and continuous radiofrequency current adjacent to the cervical dorsal root ganglion of the rat induces late cellular activity in the dorsal horn. *Anesthesiology* 2005; 102: 125–31.
7. Callstrom MR, Charboneau JW, Goetz MP, Rubin J, Wong GY, Sloan JA, et al. Painful metastases involving bone: feasibility of percutaneous CT- and US-guided radio-frequency ablation. *Radiology* 2002; 224: 87–97.
8. Patti JW, Neeman Z, Wood BJ. Radiofrequency ablation for cancer-associated pain. *J Pain* 2002; 3: 471–3.