

Case Report

Emergent Endovascular Embolization for Iatrogenic Vertebral Artery Injury during Cervical Discectomy and Fusion

Hyeun Jin Jung, M.D.,¹ Dong Min Kim, M.D., Ph.D.,² Seok Won Kim, M.D., Ph.D.,¹ Sung Myung Lee, M.D., Ph.D.¹

Departments of Neurosurgery,¹ Internal Medicine,² College of Medicine, Chosun University, Gwangju, Korea

Injury to the vertebral artery during anterior cervical discectomy is rare but potentially fatal. We report a case of cerebellar infarction after endovascular embolization for iatrogenic vertebral artery injury at C5-C6 during an anterior cervical discectomy and fusion. A 61-year-old man had an intraoperative injury of the right vertebral artery that occurred during anterior cervical discectomy and fusion at C5-C6. Hemorrhage was not controlled successfully by packing with surgical hemostatic agents. While the patient was still intubated, an emergency angiogram was performed. The patient underwent endovascular occlusion of the right V2 segment with coils. After the procedure, his course was uneventful and he did not show any neurologic deficits. Brain computed tomographic scans taken 3 days after the operation revealed a right cerebellar infarction. Anti-coagulation medication was administered, and at 3-month follow-up examination, he had no neurologic sequelae in spite of the cerebellar infarction.

Key Words : Cervical discectomy · Vertebral artery injury · Endovascular occlusion · Cerebellar infarction.

INTRODUCTION

Anterior cervical discectomy and fusion (ACDF) is a standard surgical procedure performed to remove a herniated or degenerative disc in the cervical region of the spine. Although ACDF for cervical spondylotic myelopathy or radiculopathy is considered to be safe and efficient, the vertebral artery (VA) may be injured while drilling the uncinat process due to its position adjacent to the neural foramen. When a VA is injured, the consequences can be serious or even fatal because of the difficulty in controlling the copious hemorrhage which can cause severe hypotension and even cardiac arrest. If massive intraoperative bleeding occurs, immediate control of hemorrhage is necessary and is usually achieved only by compressive tamponade. However, if intraoperative bleeding is not controlled by compressive tamponade using surgical hemostat agents, the condition becomes life-threatening and must be urgently addressed^{4,8)}. We report a case of iatrogenic injury to the vertebral artery at C5-C6 occurring while drilling the uncinat process, which was successfully treated by emergent endovascular embolization.

CASE REPORT

A 61-year-old male complaining of a tingling sensation and radiculopathy on right arm visited our medical center. Diagnostic workup disclosed a cervical spondylosis and central stenosis on C4-C7 and a right foraminal disc on C5-C6. The patient underwent decompressive laminectomy for cervical stenosis. The operation was successful, but the right arm pain still remained despite some improvement of tingling sensation. We therefore decided to perform an additional ACDF on C5-C6. He underwent microscopic discectomy employing the right side approach. The larynx, trachea, and esophagus were retracted medially using a cervical retractor and the carotid artery was retracted on the lateral side. The longus colli muscle and prevertebral fascia were then exposed. After C5-C6 discectomy, and the lower end plate of C5 and upper end plate of C6 were removed. While drilling the right medial side of the uncinat process of C5-C6, a massive pulsatile flow of fresh blood was observed. Control of the bleeding was attempted at the injury site by quickly packing with hemostatic agents (Surgicel, Spongostan, etc.). However, it was difficult to achieve complete hemostasis. When transient hemostasis was attained, the wound was closed rapidly following insertion of a cage packed with allograft bone chips. The patient's estimated blood loss was more than 1600 mL over 10 minutes. The patient was moved quickly to the interventional angiography room, and a 4-vessel angiography was performed.

• Received : December 7, 2010 • Revised : March 8, 2011

• Accepted : November 29, 2011

• Address for reprints : Seok Won Kim, M.D., Ph.D.
Department of Neurosurgery, College of Medicine, Chosun University,
365 Pilmun-daero, Dong-gu, Gwangju 501-717, Korea
Tel : +82-62-220-3126, Fax : +82-62-227-4575
E-mail : ns64902@hanmail.net

Although there was no active bleeding in right vertebral artery angiographic injection, we found a tiny leakage site that appeared to be a small pseudoaneurysm (Fig. 1). After confirming that collateral circulation of the left vertebral artery was sufficient, coil embolization of right vertebral artery was successfully performed (Fig. 2). Post-embolization angiography showed complete occlusion of the right vertebral artery, and collateral circulation of the left VA was enough to compensate for the sacrifice of the right VA (Fig. 3). After the entire procedure, neck and brain computed tomography (CT) was performed but there was no evidence of hemorrhage or infarction. The patient was transferred to the intensive care unit. On postoperative day 3 and 14, brain computed tomographic scan (CT) and magnetic resonance imaging (MRI) were performed. The CT and MRI revealed the presence of a right cerebellar infarction but there were no related symptoms and the vital signs of the patient were stable (Fig. 4). Anti-coagulation medication was administered. At the 3-month follow-up examination, the patient had no neurologic sequelae and his vital signs were also stable.

DISCUSSION

Anterior cervical discectomy and fusion to treat cervical disc herniation is popular and widely-performed by spine surgeons. An anterior approach is more convenient than a posterior approach because the disc can be reached without disturbing the spinal cord, spinal nerves, or the strong neck muscles. Despite the advantages of anterior approach, the VA can be injured during this process and can result in fatalities^{1,4,7}. Cases of iatrogenic VA injury are rare in the literature. The reported incidence of VA injury during anterior cervical surgery is 0.3-0.5% and most cases occur during corpectomy procedures^{2,8,9,11}. Most of these injuries were caused by using a high-speed drill. At our institution, we had not experienced VA injury for single level ACDF before the present case. The rate of neurological complications associated with VA injuries is 50% and the severity of complications varied from cerebellar infarction to severe quadriplegia^{4,6}. Smith et al.¹¹ analyzed three common causes of VA injury : 1) off of the midline use of a power burr, 2) excessive width of bone and disc removal, and 3) abnormal softening of the lateral bone resulting from a tumor or infection. Identification of an aberrant VA on preoperative imaging is critical to prevent these potentially devastating injuries. Gantwerker et al.⁶ insisted that the possibility of anomalous vertebral arteries that were at risk of injury during surgery. In the present case however, we couldn't find any anomalous vertebral arteries in spite of retrospective analysis of MR images. The uncinat process is medial to the transverse foramen and thus represents an important landmark for dissection or drilling during anterior cervical surgery. With aging, the uncinat process begins to flatten and lose its characteristic sharp and tapered shape. The uncinat process is intimately related to the VA and usually gives the surgeon safety margin. As it flattens with age, the uncinat process can no longer

be relied on to prevent VA injury.

When the vertebral artery is injured while drilling, the primary action is to achieve hemostasis by packing the injured site with a hemostatic agent (Surgicel, Spongostan, Avitene, etc.). Direct hemostatic tamponade by compression is easy to perform and may be effective. However, several cases of delayed hemorrhage and fistula formation from packing the injured arteries have been re-

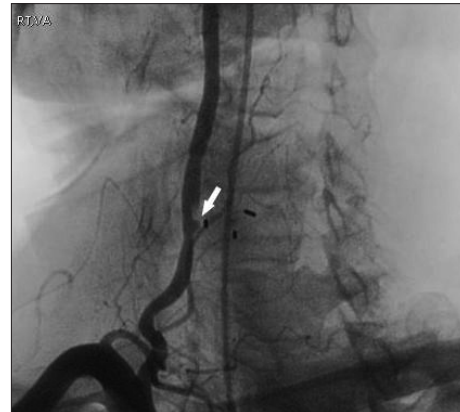


Fig. 1. Right vertebral artery angiographic injection shows filling defect on distal portion and pseudoaneurysm like appearance (arrow).

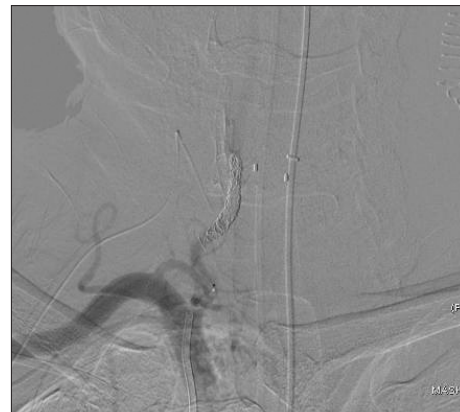


Fig. 2. Endovascular occlusion of the right V2 segment and pseudoaneurysm is being performed after confirming collateral circulation of left vertebral artery.

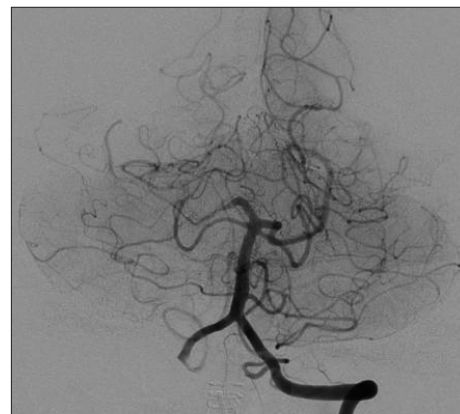


Fig. 3. Post-embolization angiography shows collateral circulation of the left vertebral artery and posterior inferior cerebellar artery.

ported in the literature. A risk of delayed hemorrhage remains for a patient in which hemorrhage was controlled by hemostatic packing^{3,5}. Some authors have advocated direct surgical repair which usually requires subperiosteal dissection of the longus colli muscle⁶. However, direct exposure and suture repair of a VA laceration is not always feasible because of massive bleeding and hemodynamic instability. In the present case, it was difficult to directly repair the vertebral artery. Recently, endovascular management, such as coil embolization, stent-assist coil embolization, and the use of stent grafts or covered stents, has been introduced¹⁰. Intraoperative angiography will help the urgent evaluation of the injury site and identify the contralateral vertebral artery status. Most patients have a dominant VA. The left VA is dominant in 50% to 60% of the population whereas the right VA is dominant in approximately only 25%. The remaining 25% of the population is known to have co-dominant vertebral arteries². Direct occlusion of an injured vertebral artery by the neurosurgeon or endovascular team is only justified if the patient has a patent contralateral VA or sufficient collateral posterior circulation. If the contralateral VA is hypoplastic, vessel repair is the preferred treatment.

There are several ways to prevent intraoperative VA injury. First, careful preoperative evaluation of the dilated or tortuous vertebral artery is most important to prevent iatrogenic VA injury. Failure to recognize an aberrant vertebral artery can result in catastrophic consequences even when lateral decompression is achieved within generally accepted safe limits. Second, an extensive lateral procedure such as decompression of the uncovertebral joints or neural foramen, lateral disc removal should be avoided. Maintaining the midline orientation is essential to adequate decompression of the neural structures, as well as to prevent injury to the vertebral artery. The medial uncovertebral joint should be a guide as to the lateral extent of any dissection or drilling. We speculate the drilling over uncovertebral joint might cause VA injury in this patient. The patient fortunately had no neurologic sequelae due to emergent endovascular obliteration in spite of cerebellar infarction.

CONCLUSION

It is important to be aware of the possibility of VA injury. It can be avoided by understanding the anatomical relationships of the VA, the spinal canal, and uncinat process. Emergent endovascular embolization should be considered as alternative mea-

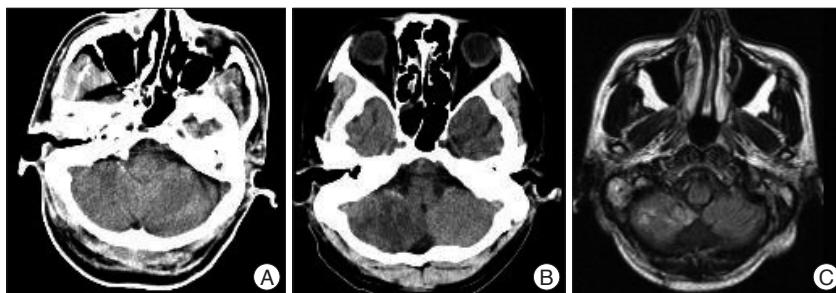


Fig. 4. Postoperative radiological imaging studies. A : There is no evidence of cerebellar infarction immediately after the endovascular embolization. B : On postoperative day 3, brain computed tomographic scan shows low density in the right cerebellar hemisphere. C : On postoperative day 14, FLAIR magnetic resonance imaging view reveals infarction in the right cerebellar hemisphere.

sure in case of difficulty with controlling bleeding by hemostatic packing.

References

- Burke JP, Gerszten PC, Welch WC : Iatrogenic vertebral artery injury during anterior cervical spine surgery. *Spine J* 5 : 508-514; discussion 514, 2005
- Choi JW, Lee JK, Moon KS, Kim YS, Kwak HJ, Joo SP, et al. : Endovascular embolization of iatrogenic vertebral artery injury during anterior cervical spine surgery : report of two cases and review of the literature. *Spine (Phila Pa 1976)* 31 : E891-E894, 2006
- Cosgrove GR, Theron J : Vertebral arteriovenous fistula following anterior cervical spine surgery. Report of two cases. *J Neurosurg* 66 : 297-299, 1987
- Daentzer D, Deinsberger W, Böker DK : Vertebral artery complications in anterior approaches to the cervical spine : report of two cases and review of literature. *Surg Neurol* 59 : 300-309; discussion 309, 2003
- de los Reyes RA, Moser FG, Sachs DP, Boehm FH : Direct repair of an extracranial vertebral artery pseudoaneurysm : case report and review of the literature. *Neurosurgery* 26 : 528-533, 1990
- Gantwerker BR, Baaj AA, Maughan PH, McDougall CG, White WL : Vertebral artery injury during cervical discectomy and fusion in a patient with bilateral anomalous arteries in the disc space : case report. *Neurosurgery* 67 : E874-E875; discussion E875, 2010
- Garcia Alzamora M, Rosahl SK, Lehmborg J, Klisch J : Life-threatening bleeding from a vertebral artery pseudoaneurysm after anterior cervical spine approach : endovascular repair by a triple stent-in-stent method. Case report. *Neuroradiology* 47 : 282-286, 2005
- Golfinos JG, Dickman CA, Zabramski JM, Sonntag VK, Spetzler RF : Repair of vertebral artery injury during anterior cervical decompression. *Spine (Phila Pa 1976)* 19 : 2552-2556, 1994
- Lee DG, Rhim SC, Roh SW, Im SB, Kwon Y, Kwun BD : Vertebral artery injury during anterior cervical spine surgery : report of two cases. *J Korean Neurosurg Soc* 30 : 231-238, 2001
- Méndez JC, González-Llanos F : Endovascular treatment of a vertebral artery pseudoaneurysm following posterior C1-C2 transarticular screw fixation. *Cardiovasc Intervent Radiol* 28 : 107-109, 2005
- Smith MD, Emery SE, Dudley A, Murray KJ, Leventhal M : Vertebral artery injury during anterior decompression of the cervical spine. A retrospective review of ten patients. *J Bone Joint Surg Br* 75 : 410-415, 1993