

Clinical Article

Acute-on-Chronic Subdural Hematoma : Not Uncommon Events

Kyeong-Seok Lee, M.D., Jae-Jun Shim, M.D., Seok-Mann Yoon, M.D., Jae-Won Doh, M.D., Il-Gyu Yun, M.D., Hack-Gun Bae, M.D.

Department of Neurosurgery, Soonchunhyang University Cheonan Hospital, Cheonan, Korea

Objective : Patients with asymptomatic chronic subdural hematoma (SDH) are prone to fall or slip. Acute trauma on these patients may develop acute subdural bleeding over the chronic SDH. We recently experienced 9 patients with acute-on-chronic SDH. We report the clinical and radiological features of this lesion.

Methods : We retrospectively examined the computed tomographic (CT) scans of 107 consecutive patients who diagnosed as chronic SDH from January 2008 to December 2010. All cases of CSDH were diagnosed on CT with or without MRI scan.

Results : Acute-on-chronic SDH is not rare, being 8% of chronic SDH. The most common cause of trauma was a slip in drunken state. Alcoholism with multiple episodes of trauma was one of the prominent histories. Acute-on-chronic SDH appeared as a hyperdense layer of clot with irregular blurred margin or lumps in liquefied hematoma. Single or two burr holes was usually effective to remove the hematoma.

Conclusion : Repeated trauma may cause acute bleeding over the chronic SDH. It will be helpful to understand the role of repeated trauma as a mechanism of hematoma enlargement.

Key Words : Chronic subdural hematoma · Computed tomography · Craniocerebral trauma · Diagnosis.

INTRODUCTION

Chronic subdural hematoma (SDH) is an encapsulated liquefied hematoma in the subdural space. Pathologically acute SDH is a solid subdural clot without membranes. Pre-morbid condition for the chronic SDH is a sufficient potential subdural space, such as brain atrophy or intracranial hypotension⁶⁾. This is the reason why chronic SDHs occur most often in the elderly. Even though the chronic SDH continue to enlarge, it may remain asymptomatic, when the reserve capacity was remained or well balanced. Although some patients with chronic SDH are still asymptomatic, they are prone to fall or slip down. If they slip, even though the injury itself is trivial, it may tear the cortical bridge veins or fragile vessels in the neomembrane. Acute trauma on the patients with chronic SDH may develop acute subdural bleeding over the chronic SDH. We recently experienced 9 patients with acute-on-chronic SDH. We report the clinical and radiological features of these lesions.

MATERIALS AND METHODS

We retrospectively examined the computed tomographic (CT) scans of 107 consecutive patients who diagnosed as chronic SDH from January 2008 to December 2010. All cases of CSDH were diagnosed on CT with or without MRI scan. We could find 9 patients (8% of chronic SDH) with acute-on-chronic SDH. We collected the medical records of these patients. We examined these medical records to obtain clinical features regarding the symptoms, history, preoperative mental status, and operative findings. We reviewed the radiological features of the CT scans. We measured the maximum thickness of the hematoma, degree of the midline shift around the third ventricle, and the highest density of the hematoma in Hounsfield units.

RESULTS

Clinical features

There was only one female patient. The age ranged from 48 to 83 years old (Table 1). The most common cause of trauma was a slip in drunken state. All had a history of alcoholism with multiple episodes of trauma. The most recent trauma was occurred within two weeks, usually 3 to 5 days. The most common symptom was hemiparesis.

• Received : September 19, 2011 • Revised : September 27, 2011
• Accepted : December 19, 2011
• Address for reprints : Kyeong-Seok Lee, M.D.
Department of Neurosurgery, Soonchunhyang University Cheonan Hospital,
31 Soonchunhyang 6-gil, Dongnam-gu, Cheonan 330-721, Korea
Tel : +82-41-570-3652, Fax : +82-41-572-9297
E-mail : ksleens@sch.ac.kr

Table 1. Clinical features of patients with acute-on-chronic subdural hematoma

No.	Sex	Age	GCS	Cause	Symptom	Past History	PT(INR)	Anticoagulants
1	F	66	9	?	Discovered on the road	Craniotomy 10 yr pta	1.12	No
2	M	48	3	Slip	Discovered on the road	HI 10 D, 1 M pta; warfarin for atrial fibrillation	2.44	Aspirin, warfarin
3	M	52	10	?	Discovered on the road	Traffic accident 15 yr pta	0.94	No
4	M	52	15	?	Headache for 9d	Aspirin	1.01	Aspirin
5	M	63	15	Slip	Hemiparesis for 3d	Alcoholic LC; slip 2 M pta	0.95	No
6	M	65	15	Slip	Hemiparesis for 3d	Craniotomy 12 yr pta	0.97	No
7	M	69	15	Slip	Hemiparesis for 1d	Slip 3 M pta	0.99	No
8	M	80	11	?	Hemiparesis for 4d	Diabetes, COPD, alcoholic LC	1.12	Aspirin
9	M	83	15	Slip	Hemiparesis for 2w	Stomach CA 7 yr pta; femur fracture 5 yr pta	1.06	No

GCS : preoperative Glasgow Coma Score, pta : prior to admission, HI : head injury, LC : liver cirrhosis, COPD : chronic obstructive pulmonary disease, CA : cancer, INR : international normalized ration

Three patients received anticoagulation therapy. However, results of the laboratory coagulation test was marginally abnormal in six patients on admission except case 2.

Radiological features

The chronic SDH were unilateral in eight cases and bilateral in one case. The acute bleeding was usually hyperdense clot with irregular blurred margin (Fig. 1, 2). It was often lumps in liquefied hematoma as in case 5 and 6. The degree of midline shift was usually more than 8 mm corresponding to the thick hematomas (Table 2). In case 2, the CT scan of the brain revealed a large SDH with three different features in the right hemisphere (Fig. 3). He used warfarin due to atrial fibrillation for 2 years. Detailed history taking revealed three episodes of head injuries; in-car accident on 49 days prior to admission (PTA), falling on 9 days PTA, and slipping down on the day of admission with corresponding subdural lesions. We presumed the layered oval hematoma resulted from the in-car accident, hypodense crescentic hematoma was developed by the falling, and the hyperdense hematoma was made by the slipping.

Treatment and outcome

Although the hematomas were a mixture of semisolid clot and liquefied hematoma, we could remove the hematoma by single or two burr holes in seven patients. We did not try to remove the clot vigorously (Table 2). We removed some clot with gentle irrigation and suction. On the immediate postoperative CT scans, we could find remained subdural hematomas (Fig. 4).

Table 2. Radiologic features of patients with acute-on-chronic subdural hematoma

No.	Side	Type	Density*	Size (mm)	Shift (mm)
1	Left	Two layered	67	20.5	8.8
2	Right	Mixed pattern	70	28.1	26.5
3	Right	Hyperdense thick layer	70	24.6	20.7
4	Left	Homogeneous hyperdensity	53	16.4	13.0
5	Left	Lumps in low density	55	24.8	10.3
6	Right	Lumps in isodensity	47	20.2	13.0
7	Left	Hyperdense layer	60	19.9	14.9
8	Right	Scattered lumps in low density	51	20.2	8.8
9	Bilateral	Hyperdense thin layer	65	22.0+11.8	9.6

*Hounsfield Unit. Size : maximum thickness of hematoma, Shift : degree of midline shift

Table 3. Treatment and outcome of patients with acute-on-chronic subdural hematoma

No.	Surgery	Operative findings	Outcome
1	Burr hole	Liquefied hematoma & clot	Died of GB CA 3 M later
2	Refused	Not operated	Died of HI on HD 5
3	Burr hole	Liquefied hematoma & clot	Recovered
4	Craniotomy	Membrane within hematoma, liquefied hematoma & clot	Recovered
5	Burr hole	Liquefied hematoma & clot	Recovered
6	Burr hole	Liquefied hematoma & clot	Recovered
7	BH & endoscope	Membrane within hematoma, liquefied hematoma & clot	Recovered
8	Burr hole	Liquefied hematoma & clot	Died of MI on HD 3
9	Burr hole	Liquefied hematoma & clot	Recovered

BH : burr hole, GB : gall bladder, CA : cancer, HD : hospital day, MI : myocardial infarction

We placed a soft silicon drain in all cases. Semisolid clot was usually drained out or resolved within several days. In case 4, we had to perform craniotomy to remove the clot under the neomembrane. In case 7, we used an endoscopy to suck out the semisolid clot around the corner of the hematoma cavity. In case 2, his relatives refused surgical treatment.

All except one patients were improved after surgery. One patient died of cardiac failure on the third hospital day. One another patient died of metastasis from the gall bladder cancer, within about 3 months after the operation.

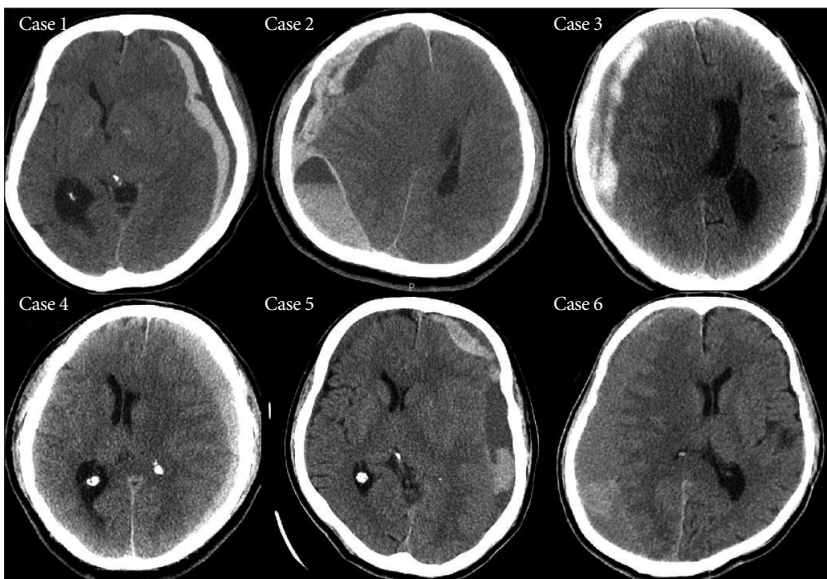


Fig. 1. Preoperative CT scans of the acute-on-chronic subdural hematoma (case 1 to 6).

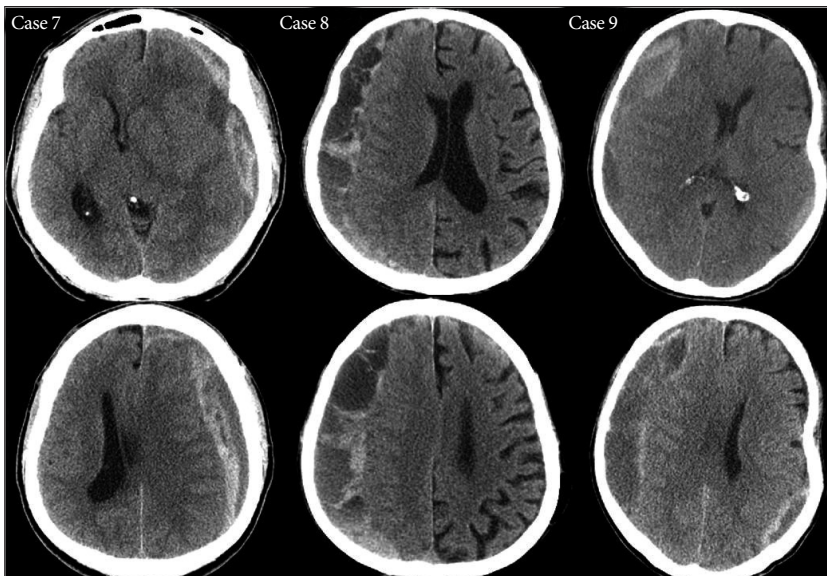


Fig. 2. Preoperative CT scans of the acute-on-chronic subdural hematoma (case 7 to 9).

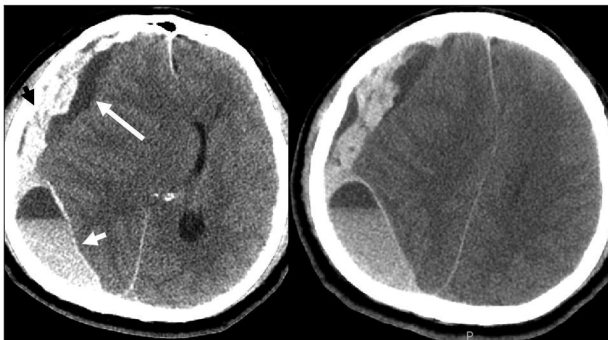


Fig. 3. CT scans of case 2. Three different hematomas are corresponding to the episodes of head injuries on 49 days (short white arrow) prior to admission (PTA), on 9 days (long white arrow) PTA, and on the day of admission (black arrow).

DISCUSSION

Acute-on-chronic SDH is not rare. In this study, we found 8% of chronic SDH were actually acute-on-chronic SDHs. There are a few cases designated as acute-on-chronic SDH in the literature^{5,8,9,16}. Curiously, it is hard to find any comments on the acute-on-chronic SDH, even in clinical series^{3,12} reporting more than a thousand cases of chronic SDH. Age and sex distribution were identical with the typical chronic SDH. Alcoholism with multiple episodes of trauma was one of the prominent features. Patients with chronic SDH are prone to the trauma since they are usually aged and enjoy drinking. The bridge veins in the potential subdural space are thin-walled¹¹, and might be under significant tension by the hematoma. Since the chronic SDH usually show excessive activation of both the coagulation and fibrinolytic systems¹⁰, acute bleeding into the hematoma cavity may not make a solid clot.

Although there was an acute subdural bleeding, the patients visited our hospital several days after the trauma. The reason was that the bleeder was usually venous or capillary, either from bridging veins or fragile new vessels in the neomembrane. The outer membrane contains many fragile sinusoidal vessels that are often the source of repeated multifocal bleeding^{4,14}. Like the repeated hemorrhages from the outer membrane, repeated trauma may cause acute bleeding over the chronic SDH as

a mechanism of hematoma enlargement. Even though the chronic SDH continue to enlarge, brain atrophy in the elderly may allow the hematoma to accumulate before symptoms become obvious¹⁷. The patients become symptomatic after compression of the pyramidal tract with significant midline shift. Bleeding from the bridging veins may produce clot, while bleeding from the neomembrane may diffuse into the pre-existing hematoma cavity. Diffusion without clot formation may produce homogeneous hyperdense chronic SDH, as in case 4.

CT remains the preferred diagnostic procedure for chronic SDH³. Acute SDH is usually hyperdense in the CT, whereas chronic one is iso- or hypodense⁷. Rebleeding into a chronic SDH with admixture of fresh blood and lucent fluid can lead to isodensity. Insidious repeated microhemorrhage from the neo-

membrane may not cause a clot, being homogeneous isodense. Repeated trauma may cause active bleeding, which would make a lump or a layer of hyperdensity within hypo- or isodense hematoma. With current high-resolution CT scanners real isodensity becomes rare¹⁹. We found a lump in isodense hematoma (case 6) or a layer of hyperdensity (case 9) in this study.

Acute-on-chronic SDH appeared as a layer of hyperdense clot with irregular blurred margin or lumps in liquefied hematoma. Acute-on-chronic SDH often show layers of extraaxial fluid of varied density separated by internal membranes². Layered type of isodense chronic SDH may result from either gravitational separation of the blood component¹⁸ or acute bleeding on the chronic SDH⁸. Often, differentiation hyperacute SDH from acute-on-chronic SDH in CT may be difficult, however, acute-on-chronic SDHs have a more insidious presentation compared to the hyperacute one^{2,13}. In case 2, we presumed the layered oval hematoma result from the in-car accident, hypodense crescentic hematoma was developed by the falling, and the hyperdense hematoma was made by the slipping.

Warfarin or other oral anticoagulants may increase intracranial hemorrhagic complications^{15,20}. The risk of SDH with anticoagulation is 4- to 15-fold²⁰. However, anticoagulation therapy is usually safe with international normalized ration (INR) from 2.0 to 3.0, since the incidence of hemorrhagic complications increase with INR >4.8¹⁵.

Even though the hematomas had a solid clot, removal of the liquefied hematoma only by a burr hole was possible to relieve the displacement. Endoscopy may be helpful to remove a semi-solid clot around the corner. Semisolid clot was usually drained out or resolved within a few days with or without urokinase or tissue plasminogen activator. The surgery was usually effective, although the final outcome was dependent on the age, Glasgow Coma Score at presentation, and associated illnesses¹¹.

CONCLUSION

Acute-on-chronic SDH is not rare, being 8% of chronic SDHs. Repeated trauma may cause acute bleeding over the chronic SDH. It will be helpful to understand the role of repeated trauma as a mechanism of hematoma enlargement.

References

1. Chen JC, Levy ML : Causes, epidemiology, and risk factors of chronic subdural hematoma. *Neurosurg Clin N Am* 11 : 399-406, 2000
2. Fernando S, Obaldo RE, Walsh IR, Lowe LH : Neuroimaging of nonac-

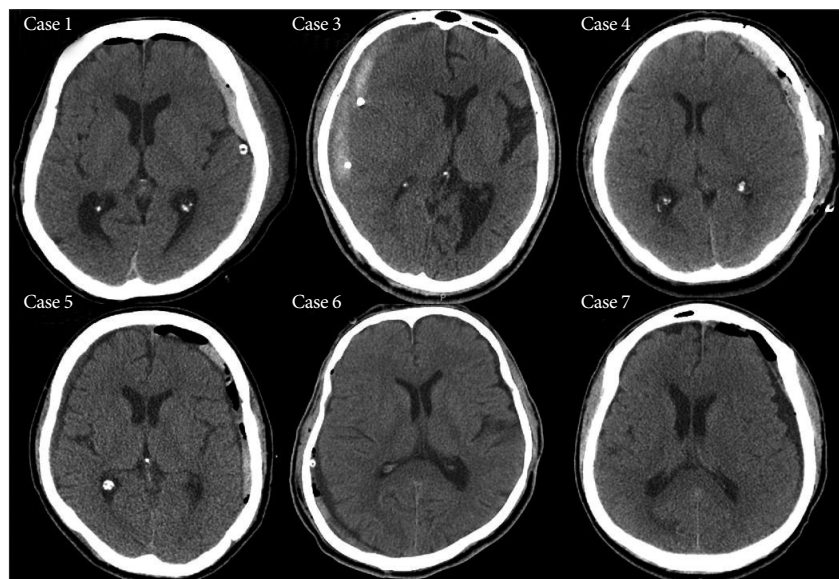


Fig. 4. Immediate postoperative CT scans of the acute-on-chronic subdural hematoma. Even though some solid clots are remained, the degree of midline shift is reduced. In case 4, there is a thin acute hematoma after a craniotomy. In case 7, we could remove the semisolid clots clearly with endoscopy.

- cidental head trauma : pitfalls and controversies. *Pediatr Radiol* 38 : 827-838, 2008
3. Gelabert-González M, Iglesias-Pais M, García-Allut A, Martínez-Rumbo R : Chronic subdural haematoma : surgical treatment and outcome in 1000 cases. *Clin Neurol Neurosurg* 107 : 223-229, 2005
4. Haines DE, Harkey HL, al-Mefty O : The "subdural" space : a new look at an outdated concept. *Neurosurgery* 32 : 111-120, 1993
5. Kloss BT, Lagace RE : Acute-on-chronic subdural hematoma. *Int J Emerg Med* 3 : 511-512, 2010
6. Lee KS : Natural history of chronic subdural hematoma. *Brain Inj* 18 : 351-358, 2004
7. Lee KS, Bae WK, Bae HG, Doh JW, Yun IG : The computed tomographic attenuation and the age of subdural hematomas. *J Korean Med Sci* 12 : 353-359, 1997
8. Luque JC, Monsalve G : Suspended brain in a degraded bottom : bilateral subdural chronic hematomas with acute rebleeding. *J Trauma* 69 : 240, 2010
9. Miele VJ, Carson L, Carr A, Bailes JE : Acute on chronic subdural hematoma in a female boxer : a case report. *Med Sci Sports Exerc* 36 : 1852-1855, 2004
10. Park SH, Kang DH, Park J, Hwang JH, Hwang SK, Sung JK, et al. : Fibrinogen and D-dimer analysis of chronic subdural hematomas and computed tomography findings : a prospective study. *Clin Neurol Neurosurg* 113 : 272-276, 2011
11. Ramachandran R, Hegde T : Chronic subdural hematomas--causes of morbidity and mortality. *Surg Neurol* 67 : 367-372; discussion 372-373, 2007
12. Sambasivan M : An overview of chronic subdural hematoma : experience with 2300 cases. *Surg Neurol* 47 : 418-422, 1997
13. Sargent S, Kennedy JG, Kaplan JA : "Hyperacute" subdural hematoma : CT mimic of recurrent episodes of bleeding in the setting of child abuse. *J Forensic Sci* 41 : 314-316, 1996
14. Sato S, Suzuki J : Ultrastructural observations of the capsule of chronic subdural hematoma in various clinical stages. *J Neurosurg* 43 : 569-578, 1975
15. Stein PD, Grandison D, Hua TA, Slettehaug PM, Henry JW, Turlapaty

- P, et al. : Therapeutic level of oral anticoagulation with warfarin in patients with mechanical prosthetic heart valves : review of literature and recommendations based on international normalized ratio. **Postgrad Med J 70 Suppl 1** : S72-S83, 1994
16. Takahashi N, Kimura H, Kitai R, Sato M, Yoneda M, Yamamoto C, et al. : Acute on chronic subdural hematoma as a rare complication in a microscopic polyangiitis patient receiving antithrombotic treatment. **Clin Nephrol 72** : 211-215, 2009
17. Tan ST, Hung CT : Acute-on-chronic subdural haematoma : a rare complication after spinal anaesthesia. **Hong Kong Med J 9** : 384-386, 2003
18. Tsai FY, Huprich JE, Segall HD, Teal JS : The contrast-enhanced CT scan in the diagnosis of isodense subdural hematoma. **J Neurosurg 50** : 64-69, 1979
19. Wilms G, Marchal G, Geusens E, Raaijmakers C, Van Calenbergh F, Goffin J, et al. : Isodense subdural haematomas on CT : MRI findings. **Neuroradiology 34** : 497-499, 1992
20. Wintzen AR, Tijssen JG : Subdural hematoma and oral anticoagulant therapy. **Arch Neurol 39** : 69-72, 1982