

## Clinical Article

# Clinical Efficacy of Radiation-Sterilized Allografts for Sellar Reconstruction after Transsphenoidal Surgery

Sejin Kim, M.D.,<sup>1</sup> Chiman Jeon, M.D.,<sup>2</sup> Doo-Sik Kong, M.D., Ph.D.,<sup>3</sup> Kwan Park, M.D.,<sup>3</sup> Jong Hyun Kim, M.D.<sup>3</sup>

*Department of Neurosurgery,<sup>1</sup> Gyeongsang National University School of Medicine, Jinju, Korea*

*Department of Neurosurgery,<sup>2</sup> Pusan National University School of Medicine, Busan, Korea*

*Department of Neurosurgery,<sup>3</sup> Samsung Medical Center, Sungkyunkwan University School of Medicine, Seoul, Korea*

**Objective :** The aim of this study was to assess the safety and efficacy of radiation-sterilized allografts of iliac bone and fascia lata from cadaver specimens to repair skull base defects after transsphenoidal surgery.

**Methods :** Between May 2009 and January 2010, 31 consecutive patients underwent endonasal transsphenoidal surgery and all patients received sellar reconstruction using allografts following tumor removal. The allografts were obtained from the local tissue bank and harvested from cadaver donors. The specimens used in our approach were tensor fascia lata and the flat area of iliac bone. For preparation, allografts were treated with gamma irradiation after routine screening by culture, and then stored at -70°C.

**Results :** The mean follow-up period after surgery was 12.6 months (range, 7.4-16 months). Overall, postoperative cerebrospinal fluid (CSF) leaks occurred in three patients (9.7%) and postoperative meningitis in one patient (3.2%). There was no definitive evidence of wound infection at the routine postoperative follow-up examination or during re-do surgery in three patients. Postoperative meningitis in one patient was improved with the use of antibiotics and prolonged CSF diversion.

**Conclusion :** We suggest that allograft materials can be a feasible alternative to autologous tissue grafts for sellar reconstruction following transsphenoidal surgery under selected circumstances such as no or little intraoperative CSF leaks.

**Key Words :** Endoscopic endonasal approach · Transsphenoidal approach · Allograft · Sellar reconstruction · CSF leak.

## INTRODUCTION

The transsphenoidal approach has been regarded as a safe and effective treatment for a variety of sellar and parasellar pathologies. Even large tumors involving the skull base or tumors located adjacent to the internal carotid artery can be successfully managed by endoscopic techniques<sup>15</sup>. An endoscopic endonasal approach (EEA) to the anterior cranial base provides minimally invasive access for removing a variety of intra- and extradural cranial base pathologies<sup>10</sup>. Although EEA has many advantages including the fact that it does not require brain retraction and involves minimal neurovascular manipulation, sellar reconstruction following removal of the tumor poses some difficulties and carries the potential risk of postoperative cerebrospinal fluid (CSF) leaks<sup>2-4,9,10,14</sup>. Because postoperative CSF leak can

sometimes lead to ascending meningitis or tension pneumocephalus, water-tight reconstruction of large skull defects is essential and is considered one of the greatest challenges of endonasal skull base surgery<sup>5</sup>.

To date, numerous attempts have been made to reconstruct sellar defects such as free graft using the fat tissue or fascia lata, packing of collagen sponge, and the use of a variety of solid or semisolid buttress materials such as autologous cartilage and bone, absorbable plates, and nonabsorbable silicone and titanium plates or mesh<sup>2,5,10,11,13</sup>. However, when used as dural substitutes, autologous tissues such as abdominal fat or tensor fascia lata require additional skin incisions and prolonged operative time<sup>2</sup>. In addition, autologous septal bone is irregularly shaped and bony reconstruction is difficult to apply as a buttress. In terms of not requiring additional skin incisions, bovine, porcine or artificial materials and nonabsorbable silicone or titanium mesh provide some advantages over autologous tissues especially in the cases with no or little intraoperative CSF leaks. We have recently carried out reconstruction with radiation-sterilized allograft materials for the repair of sellar floor defects. In this study we retrospectively evaluated the safety and efficacy of radiation-sterilized allografts using iliac bone and tensor fascia

• Received : January 20, 2011 • Revised : September 19, 2011

• Accepted : December 19, 2011

• Address for reprints : Doo-Sik Kong, M.D., Ph.D.

Department of Neurosurgery, Samsung Medical Center, Sungkyunkwan University School of Medicine, 50 Irwon-dong, Gangnam-gu, Seoul 135-710, Korea


Tel : +82-2-3410-0732, Fax : +82-2-3410-0048

E-mail : kds026@skku.edu

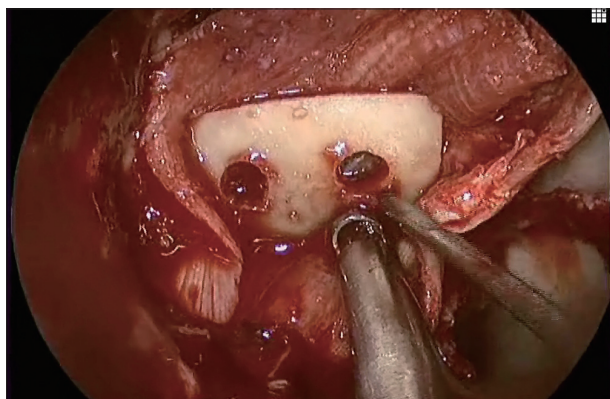
lata from cadaver specimen for reconstruction of skull base defects after the transsphenoidal surgery.

**Table 1.** The characteristics of patients

Characteristic	Value
No. of patients	31
Follow-up (mo)	
Median	12.6
Range	7.4-16
Age (y)	
Mean	45
Range	13-76
Sex (n)	
Male	21
Female	10
Pathology (n)	
Pituitary adenoma	21
Craniopharyngioma	4
Rathke's cleft cyst	1
Xanthogranuloma	1
Chordoma	1
Meningioma	1
Brain abscess	1
Olfactory neuroblastoma	1



**Fig. 1.** Photographs demonstrating tensor fascia lata and the flat area of iliac bone that are obtained from the local tissue bank, which was approved by Korea Food and Drug Administration.



**Fig. 2.** Modified gasket-seal method using allograft materials for sellar reconstruction. Allograft fascia from the tissue bank is fashioned as an on-lay layer covering the skull base defect. Then, a flat bone allograft from cadaveric iliac bone is placed approximately over the edge of the bony defect as a buttress.

## MATERIALS AND METHODS

### Patient population

We reviewed the pituitary tumor database for a total of 31 consecutive patients who underwent 31 EEA procedures between May 2009 and January 2010. This study was performed under the permission of our local institutional review board (SMC 2011-05-031-002). The patients consisted of 10 women and 21 men. Patient age ranged from 13 to 76 years, with a mean of 45 years. Twenty-two patients underwent transsphenoidal transsellar EEA for intrasellar lesions, whereas 9 patients received transtuberculum or transplanum EEA for extra-sellar lesions. All surgeries were performed by a single physician (DK). Pathological diagnosis included 21 pituitary adenomas, one Rathke's cleft cyst, 4 craniopharyngiomas, and 5 other tumors including chordoma, meningioma, and xanthogranuloma (Table 1). Medical records were reviewed to determine the magnitude of the intraoperative CSF leak and to identify procedure-related complications and adverse effects attributed to the use of allografts.

### Allograft preparation

Allografts obtained from the local tissue bank, which was approved by Korea Food and Drug Administration, were harvested from cadaver donors. The tissues used were the tensor fascia lata and the flat area of the iliac bone. All donors had undergone standard screening tests for transmissible diseases such as human immunodeficiency virus, hepatitis viruses (HBV and HCV), cytomegalovirus, and the VDRL test for syphilis. Allografts were treated with gamma irradiation (25 KGy), and then stored at -70°C (Fig. 1).

### Surgical procedures

All patients included in this study underwent EEA for sellar or extra-sellar lesions. Patients were typically placed in the supine position with their heads elevated 20-30 degrees. To allow for the use of the neuronavigation systems, each patient's head was placed in a three-point Mayfield skeletal fixation headrest. The endoscopic procedure was performed using a rigid endoscope (Karl Storz, Tuttlingen, Germany) with a diameter of 4 mm, a length of 18 cm with 0 or 30-degree lenses. Standard EEA was performed bilaterally through the nostrils, and the floor of the sella was opened to expose the cavernous sinuses laterally along with the superior and inferior intercavernous sinuses. In extended EEA, the thick bone of the tuberculum sellae and the sellar floor were removed using a high speed 3 mm diamond drill. Frameless neuronavigation was routinely used to assess the removal of bone and to accurately approach the target sites. Extended EEA did not always require opening of the arachnoid membrane, especially in patients with extradural lesions such as chordoma involving the clivus. Disruption of the integrity of the subarachnoid space was only necessary for the following conditions: significant dumbbell shape of the tumor, craniopharyngioma, me-

ningioma or tumor showing eccentric suprasellar growth.

### Gasket-seal method using allografts

The method previously described by Leng et al. was modified and applied primarily for grade 1 or 2 CSF leaks. First, either autologous tensor fascia lata or homologous fascia from the tissue bank at our institute was fashioned as an onlay layer that was larger than the cranial base defect. This redundant graft extended beyond the margin of the bone defect. Then, a flat bone allograft from cadaveric iliac bone was placed approximately over the edge of the bony defect as a buttress (Fig. 2). The compaction of the fascia lata graft by the overlying bone graft resulted in a tight closure of the skull base defect. We performed an extra-multilayer closure including additional fascia lata and synthetic materials such as gelatin foams and collagen sponges. Finally, polymerised hydrogel (DuraSeal) was sprayed over the bone and fascia lata graft. We used the database of the endoscopic skull base center to evaluate safety and complications such as infections, crust formation, infectious disease transmission, and postoperative meningitis following sellar reconstruction using allografts for skull base defects. Infectious complications are surprisingly rare with endonasal skull base surgery, with an incidence of bacterial meningitis of 1-2%. This can be attributed to minimal bacterial colonization of the nasal cavity and sinuses (compared to the oral cavity), prophylactic perioperative antibiotics, frequent intraoperative irrigation, skull base reconstruction with allografts, and aggressive management of postoperative CSF leaks<sup>15</sup>.

## RESULTS

Between May 2009 and January 2010, 31 consecutive patients underwent endonasal transsphenoidal surgery and, following tumor removal, all patients underwent sellar reconstruction using allografts. The mean follow-up period after the surgery was 12.6 months (range, 7.4-16 months). The “gasket-seal” method using allografts with tensor fascia lata and flat area from iliac bone was used for reconstruction for skull base defects in all patients.

### Outcomes of reconstruction

Postoperative CSF leaks occurred in three patients. Two of these three patients required a second intervention for persistent CSF leaks. There was no definitive evidence of wound infection during re-do surgery in three patient. Regular follow-up rhinological examination revealed that there was no definitive difference of healing time and eventually time of covering with normal nasal mucosa overlying the surgical wound, compared with the cases with autologous tissue grafts.

### Infection rates

We found postoperative meningitis in one of 31 patients. Postoperative meningitis was improved with the use of antibiotics and prolonged CSF diversion and did not require further

surgical intervention. Regular rhinological examinations also revealed no evidence of nasal infection.

## DISCUSSION

Transsphenoidal surgery is widely recognized as the optimal approach for resection of sellar or suprasellar tumors<sup>12</sup> because of its short operation time, simple surgical procedures, and low associated morbidities<sup>13</sup>. Despite modern advances in surgical technique and increased expertise of neurosurgeons, sellar reconstruction remains challenging<sup>9</sup>. Several methods for sellar reconstruction have been proposed to prevent CSF leaks<sup>3,4,9,10,13,14</sup>. The use of autologous tissue is highly recommended to enhance the outcome for sellar reconstruction. This is especially important when high flow CSF leaks are expected after tumor removal in the case of extended transsphenoidal surgeries requiring that the arachnoid membrane be opened wide, or when communication with the third ventricle is involved. However, in most cases with no or low intraoperative CSF leaks, and with the exception of extended transsphenoidal surgeries, autologous tissue grafts can lead to inconvenience of additional skin incisions, prolongation operation times, and subsequent pain and cosmetic disadvantages. In these cases, synthetic dura and titanium mesh or xenografts including bovine or porcine materials can be used for sellar reconstruction instead of autologous grafts. Allografts present another attractive source to close the sellar defect made by transsphenoidal surgery<sup>9,10</sup>.

Here, we evaluated use of allograft tissue and bone as a dural substitute and buttress. The use of allografts reduces operation time and avoids additional scarring associated with autologous tissue grafts. Allografts are especially useful in pediatric patients because they can prevent the psychological trauma from another skin incision. However, it has been assumed that allograft materials carry risks of infection<sup>7</sup>. To avoid the risk of transmission of infectious disease from donor to recipient, sterilization of allografts from the donors by radiation treatment has been recommended<sup>1,6,8</sup>. In our study, we performed routine preparations including culture to assess bacterial contamination and gamma irradiation of 25 KGy. Toxic compounds released after gamma irradiation of bone marrow in trabecular bone may cause adverse effects<sup>16</sup>. However, the infection rate is decreased by minimal bacterial colonization of the nasal cavity and sinuses (compared to the oral cavity), and can be further controlled by prophylactic peri-operative antibiotics, frequent intraoperative irrigation, skull base reconstruction with allografts, and aggressive management of postoperative CSF leaks<sup>15</sup>.

Gamma irradiation with 25 KGy may decrease the bio-availability of graft materials and yields unsatisfactory outcomes of reconstruction for CSF leaks. Such failure to control CSF leaks is closely associated with higher infection rates. Allografts from the fascia lata is assumed to show weaker adhesion to adjacent structures and are of limited use in cases with severe CSF leaks, compared to autologous tensor fascia lata. Thus, the use of al-

lograft materials should perhaps be limited to cases with no or slight CSF leaks, rather than those with severe CSF leaks requiring autologous grafts. Additional studies of the use of allografts for severe intraoperative CSF leaks should be carried out to assess the reconstructive results, compared with the use of autologous tissue grafts.

## CONCLUSION

We suggest that allograft materials present a feasible alternative to autologous tissue grafts for sellar reconstruction following transsphenoidal surgery under selected circumstances, such in as patients with no or few intraoperative CSF leaks.

## References

1. Balsly CR, Cotter AT, Williams LA, Gaskins BD, Moore MA, Wolfbarger L Jr : Effect of low dose and moderate dose gamma irradiation on the mechanical properties of bone and soft tissue allografts. *Cell Tissue Bank* 9 : 289-298, 2008
2. Cavallo LM, Messina A, Esposito F, de Divitiis O, Dal Fabbro M, de Divitiis E, et al. : Skull base reconstruction in the extended endoscopic transsphenoidal approach for suprasellar lesions. *J Neurosurg* 107 : 713-720, 2007
3. Ciric I, Ragin A, Baumgartner C, Pierce D : Complications of transsphenoidal surgery : results of a national survey, review of the literature, and personal experience. *Neurosurgery* 40 : 225-236; discussion 236-237, 1997
4. de Divitiis E, Cavallo LM, Cappabianca P, Esposito F : Extended endoscopic endonasal transsphenoidal approach for the removal of suprasellar tumors : Part 2. *Neurosurgery* 60 : 46-58; discussion 58-59, 2007
5. Dusick JR, Mattozo CA, Esposito F, Kelly DF : BioGlue for prevention of postoperative cerebrospinal fluid leaks in transsphenoidal surgery : a case series. *Surg Neurol* 66 : 371-376; discussion 376, 2006
6. Fideler BM, Vangsness CT Jr, Lu B, Orlando C, Moore T : Gamma irradiation : effects on biomechanical properties of human bone-patellar tendon-bone allografts. *Am J Sports Med* 23 : 643-646, 1995
7. Flynn MK, Webster GD, Amundsen CL : Abdominal sacral colpopexy with allograft fascia lata : one-year outcomes. *Am J Obstet Gynecol* 192 : 1496-1500, 2005
8. Grieb TA, Forng RY, Bogdanský S, Ronholdt C, Parks B, Drohan WN, et al. : High-dose gamma irradiation for soft tissue allografts : high margin of safety with biomechanical integrity. *J Orthop Res* 24 : 1011-1018, 2006
9. Kelly DF, Oskouian RJ, Fineman I : Collagen sponge repair of small cerebrospinal fluid leaks obviates tissue grafts and cerebrospinal fluid diversion after pituitary surgery. *Neurosurgery* 49 : 885-889; discussion 889-890, 2001
10. Leng LZ, Brown S, Anand VK, Schwartz TH : "Gasket-seal" watertight closure in minimal-access endoscopic cranial base surgery. *Neurosurgery* 62 : ONSE342-ONSE343; discussion ONSE343, 2008
11. Nishioka H, Izawa H, Ikeda Y, Namatame H, Fukami S, Haraoka J : Dural suturing for repair of cerebrospinal fluid leak in transnasal transsphenoidal surgery. *Acta Neurochir (Wien)* 151 : 1427-1430, 2009
12. Rabadán AT, Hernández D, Ruggeri CS : Pituitary tumors : our experience in the prevention of postoperative cerebrospinal fluid leaks after transsphenoidal surgery. *J Neurooncol* 93 : 127-131, 2009
13. Seda L, Camara RB, Cukiert A, Burattini JA, Mariani PP : Sellar floor reconstruction after transsphenoidal surgery using fibrin glue without grafting or implants : technical note. *Surg Neurol* 66 : 46-49; discussion 49, 2006
14. Shiley SG, Limonadi F, Delashaw JB, Barnwell SL, Andersen PE, Hwang PH, et al. : Incidence, etiology, and management of cerebrospinal fluid leaks following trans-sphenoidal surgery. *Laryngoscope* 113 : 1283-1288, 2003
15. Snyderman CH, Pant H, Carrau RL, Prevedello D, Gardner P, Kassam AB : What are the limits of endoscopic sinus surgery? : the expanded endonasal approach to the skull base. *Keio J Med* 58 : 152-160, 2009
16. Vastel L, Lemoine CT, Kerboull M, Courpiéd JP : Structural allograft and cemented long-stem prosthesis for complex revision hip arthroplasty : use of a trochanteric claw plate improves final hip function. *Int Orthop* 31 : 851-857, 2007