

# Retrospective Study of Bone Resorption after Maxillary Sinus Bone Graft

Ji-A Moon<sup>1</sup>, Min-Sung Cho<sup>2</sup>, Seung-Gon Jung<sup>2</sup>, Min-Suk Kook<sup>2</sup>,  
Hong-Ju Park<sup>2</sup>, Hee-Kyun Oh<sup>2</sup>

1. Department of Dental Science, School of Dentistry, Chonnam National University, Gwangju, Korea  
2. Department of Oral and Maxillofacial Surgery, School of Dentistry, Chonnam National University, Gwangju, Korea

## Corresponding Author

**Hee-Kyun Oh, DDS, PhD**

Department of Oral and Maxillofacial Surgery, School of Dentistry, Chonnam National University, 77 Yongbong-ro, Buk-gu, Gwangju 500-757, Korea  
TEL : +82-62-530-5817 FAX : +82-62-220-5437 E-mail: hkoh@chonnam.ac.kr

Received for publication November 25, 2011; Returned after revision December 1, 2011;  
Accepted for publication December 8, 2011

## • Abstract

**Purpose:** This research sought to determine the resorption rate of bone grafted to the maxillary sinus according to the grafted material's type, patient's age, systemic disease, implant size, site of implant placement, and residual ridge height.

**Materials and Methods:** This research targeted 24 patients who had immediate Osstem<sup>®</sup> implant (US Plus<sup>®</sup>) placement after bone graft. The panorama was taken before the surgery, after the surgery, and 6 months after the surgery. Vertical height change and resorption rate of the grafted bone were measured with the same X-rays and compared. The influence of the following factors on the grafted bone material's resorption rate was evaluated: grafted material type, patient's age, systemic disease, implant size, site of implant placement, and residual ridge height.

**Results:** Patients in their 40s had 34.0±21.1% resorption rate, which was significantly higher compared to the other age groups (P<0.05). There was no significant relationship between systemic disease and grafted bone resorption. There was no significant relationship between implant size (diameter, length) and grafted bone resorption. There was no significant relationship between the site of implant placement and grafted bone resorption. The ramal bone-grafted site was significantly more resorbed than the ramal bone/Bio-Oss<sup>®</sup>-grafted site, maxillary tuberosity bone/Bio-Oss<sup>®</sup>-grafted site, and ramal bone/maxillary tuberosity bone/Bio-Oss<sup>®</sup>-grafted site (P<0.05). There was no significant difference in the grafted bone resorption rate in the sinus between more than 4 mm and less than 4 mm residual ridge heights. After an average of 6 months, a second surgery was done; given an average follow-up of 1.9 years, the success rate and survival rate of the implant were 96.9% and 98.4%, respectively.

**Conclusion:** These results indicate that the bone resorption rate of grafted bone among patients in their 40s is higher compared to patients in their 50s and over, and that only autogenous bone (ramus) shows higher resorption rate than the mixed graft of autogenous bone and xenogenous graft (Bio-oss) after maxillary sinus graft.

• Key word : Dental implants, Maxillary sinus, Alveolar ridge augmentation, Alveolar bone loss/surgery, Bone resorption

• J Kor Dent Sci. 2011; 4(2) : 59 - 66

© This is an open access article distributed under the terms of the Creative Commons Attribution Non-Commercial License (<http://creativecommons.org/licenses/by-nc/3.0>) which permits unrestricted non-commercial use, distribution, and reproduction in any medium, provided the original work is properly cited.

## Introduction

After the loss of the maxillary molar, the maxillary sinus floor shows rapid resorption; the size of the maxillary sinus also increases. Therefore, only the thin bone wall between the oral cavity and the maxillary sinus may remain. To place an implant for such patient, bone graft is done for bone augmentation. In 1980, Boyne and James<sup>1)</sup> performed maxillary sinus bone graft for implant placement for the first time. As implant technology and bone grafting developed, and surface treatment technology improved, maxillary sinus bone grafting became a popular surgery. Nonetheless, maxillary sinus bone as grafting material has become the object of controversy. Bone grafting materials used for maxillary sinus graft include autogenous bone, allogeneous bone, xenogeneous bone, and synthetic bone. Since autogenous bone graft has the disadvantage of requiring secondary surgery, allogeneous bone, xenogeneous bone, or synthetic bone may be used. Unlike autogenous bone, allogeneous bone contains no osteoblast; thus, osteogenesis by osteoconductive material may not be expected. The principle of new bone to be formed by autogenous bone is that grafted bone exhibits osteoconductivity for osteoblast maturity by stimulating the osteoprogenitor cell of adjacent tissue or plays the role of passive substrate for the osteoprogenitor cell of adjacent tissue to come in after growth<sup>2)</sup>. Meanwhile, autogenous bone graft has the limit of bone yield but no tissue rejection; it is also regarded as surgery with high prediction. According to Drago and Sullivan<sup>3)</sup> autogenous bone is a bone graft material with the highest regenerative capability when it comes to alveolar bone defects. Note, however, that maxillary sinus bone graft using autogenous bone was found to lead to considerable bone resorption over time. In particular, Hatano et al.<sup>4)</sup> cited the possibility of pneumatization for the first 2~3 years after bone grafting. In their study using computed tomography (CT), Johansson et al.<sup>5)</sup> stated that maxillary sinus bone graft using autogenous bone harvested from iliac bone led to the resorption of 49.5% of graft material 6 or 7 months after the surgery. On the other hand, Smolka et al.<sup>6)</sup> reported that maxillary sinus elevation using skull vault in autogenous bone recorded an average of 19.2% resorption as a result of measuring grafted bone volume using three-dimensional CT.

Autogenous bone including hard bone, ribs, or iliac bone can be used. Due to problems such as inconvenience of hospitalization, general anesthesia, postoperative pain, and bur-

den of medical expenses, however, its use has been limited. Alternatively, autogenous bone from the oral cavity such as mental region, mandibular body, zygomatic region, and maxillary tuberosity has often been used<sup>7)</sup>. Mandibular ramus bone has high ratio of cortical bone, but the harvest of the latter is difficult. Nonetheless, it is preferred as bone graft material for the maxillary sinus due to the low risk of edema and nerve injury compared to mental bone. Bone in the maxillary tuberosity area is mostly composed of trabecular bone and used limitedly due to the lack of bone mass but preferred as maxillary sinus bone graft material due to the ease of harvesting and absence of specific complications except the risk of perforation<sup>8)</sup>. To remedy such shortcomings, the use of bone graft material by non-autogenous bone was discussed.

In 1996, the Academy of Osseointegration Sinus Consensus Conference<sup>9)</sup> published the positive effect of using other bone graft material including allogeneous, xenogeneous, and synthetic bone as well as autogenous bone as maxillary sinus bone graft material. Later, many clinical and histological studies on maxillary sinus bone graft material have been reported. In particular, Hatano et al.<sup>4)</sup> recommended the combined use of allogeneous bone and synthetic bone and autogenous bone.

Jensen et al.<sup>9)</sup> noted that residual alveolar bone height had the most influence on the survival rate of the implant placed after maxillary sinus elevation, and that, if the height was 7 mm or less, bone graft must be done for implant placement. Meanwhile, in poor bone substrate, the implant with rough surface formed through surface treatment was found to have faster periosteal reaction and stabler, higher survival rate than the implant with smooth surface on the long-term basis<sup>10)</sup>.

Such extensive literature revealed the fact that bone graft material type, residual alveolar bone height, and implant surface type had an influence on the survival rate of the implant placed after maxillary sinus elevation, but it has not clearly shown the effect on the implant survival rate of factors such as the patient's age, systemic disease, implant placement position, and implant size. In particular, there have been few studies on the factors affecting bone resorption.

This research sought to determine the influence of bone graft material, age, systemic disease, implant size, implant placement position, and residual alveolar bone height on the resorption rate of grafted bone after maxillary sinus bone

graft.

## Materials and Methods

### 1. Research Object

This research targeted patients whose X-ray was taken just before and after the surgery and 6 months after the surgery among those who had Osstem® US Plus® Implant (Osstem®, Seoul, Korea) placed after maxillary sinus bone graft using the lateral window approach technique in Department of Oral and maxillofacial surgery, Chonnam University between Dec. 2008 and Sept. 2010. The 24 patients were selected for this research after excluding patients with maxillary bone fracture, disease symptoms such as tumor or cyst in the maxillary sinus, maxillary sinus surgery record, only maxillary sinus bone graft surgery performed, no X-ray taken after the surgery, and delayed placement from among a total of 47 patients who had bone graft.

A clinical conference was held with the relevant doctor for patients with systemic disease before the maxillary sinus bone graft, and such patients were not excluded unless there was any significant finding in the conference.

### 2. Research Methods

#### 1) Surgical Procedure

The surgery was performed following Midazolam sedation treatment and local anesthesia. The full-thickness skin flap was elevated by performing alveolar crest incision and vertical incision up to the mucogingival junction, and oval bone cut was done by round bur on the anterior wall of the maxillary sinus. After the mucosa of the maxillary sinus was elevated, an acceptable implant bed was formed according to the manufacturer's instruction. Autogenous bone was harvested from the maxillary tuberosity or mandibular ramus. The bone harvested from the mandibular ramus was crushed, and bone rongeur was used for harvesting the bone from the maxillary tuberosity. Bio-Oss® (Geistlich Pharma AG, Wolhusen, Switzerland) was used as allogeneous bone; harvested autogenous bone was used separately or in combination with Bio-Oss® for the maxillary sinus bone graft. A tissue adhesive, Tisseel® (Baxter Healthcare, Westlake Village, CA, USA), was used in combination with particulate bone to ensure the stability of bone graft material and hemostatic effect. After filling with bone graft material in the elevated maxillary sinus base, and then performing implant placement, the wound area was sutured

using 3.0 Mersilk to avoid applying any tension on it.

#### 2) Radiological Examination

The residual alveolar bone mass was checked by measuring the distance from the alveolar crest to the maxillary sinus base on a panorama taken before the surgery. The amount of bone augmentation (A) was evaluated to observe the resorption of the maxillary sinus graft material by measuring the distance from the bottommost part of the fixture threads to the uppermost part of bone graft material on a center-line of fixture after the surgery. The same measuring method was applied to evaluate the bone augmentation amount on a panorama taken 6 months after the bone graft (B). With such difference, the resorption amount of bone graft material (A-B) and the resorption rate (resorption amount  $\times$  100/A) were calculated (Fig. 1).

#### 3) Statistical Analysis on the Resorption Rate of Bone Graft Material

With each measurement, statistical analysis on bone resorption 6 months after the surgery was performed using independent-sample t-test and Chi-square test in the SPSS 12.0™ program by age, systemic disease, implant size, implant placement region, bone graft material, and residual alveolar bone height.

#### 4) Clinical Evaluation on Implant

Complications including perforation, osseointegration failure, and survival and success rates of 64 implants placed simultaneously with maxillary sinus elevation were investigated by retrospectively examining the patients' medical

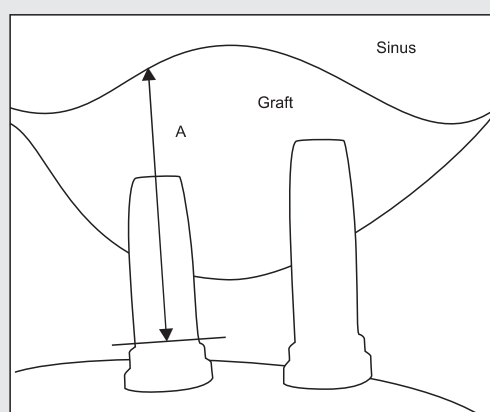


Fig 1. Measure of the distance (A) between the uppermost part of bone graft material and the lowermost part of the fixture threads on the panoramic image.

Ji-A Moon, et al: Retrospective Study of Bone Resorption after Maxillary Sinus Bone Graft. J Kor Dent Sci 2011.

records during an average monitoring period of one year and 9 months (10 months~2 years and 4 months) after bone graft. The criteria for implant survival were set as the case wherein the upper prosthesis functions well without any special symptom after placement to date, and that, even if the soft tissue around the implant has a problem, its function is maintained by properly treating the problem and removing the symptom. The criteria for implant success were set as the case without any fluctuation, pain, abnormality in cognition, radiolucent lesion, peri-implantitis, and progressive bone resorption (1 mm or less within one year of implant placement and 0.2 mm or less after one year) according to the criteria of Albrektson<sup>11</sup>. In this research, secondary surgery was performed after an average of 6 months.

## Results

### 1. Age Group and Resorption Rate of Maxillary Sinus Bone Graft

Based on the panorama taken before the surgery and 6 months after the surgery, the resorption rate of maxillary sinus bone graft of patients in their 40s was 34.0±21.1%,

**Table 1. Mean resorption rate of bone materials according to age**

Age	Number of implants	Resorption rate (%) (Mean±SD)
40~49	16	34.0±21.1
50~59	21	18.2±6.4
60~69	20	20.6±16.2
70~79	7	22.8±10.6
Total	64	

SD: standard deviation.

\*Statistically significant difference, P<0.05.

Ji-A Moon, et al: Retrospective Study of Bone Resorption after Maxillary Sinus Bone Graft. J Kor Dent Sci 2011.

**Table 2. Mean resorption rate of bone materials according to systemic disease**

Systemic disease	Number of patients	Resorption rate (%) (Mean±SD)
None	12	23.0±16.8
Hypertension	4	22.2±14.5
Diabetes mellitus	2	19.0±1.2
Cardiovascular dx	3	20.3±10.2
Tuberculosis	1	23.6±10.8
Hyperthyroidism	2	21.9±12.2
Total	24	

SD: standard deviation.

Ji-A Moon, et al: Retrospective Study of Bone Resorption after Maxillary Sinus Bone Graft. J Kor Dent Sci 2011.

which was significantly higher than the rates of other ages (P<0.05). There was no significant difference among the 50s, 60s, and 70s age groups, however (Table 1).

### 2. Systemic Disease and Bone Resorption Rate

Systemic disease had no significant impact on the resorption rate of maxillary sinus bone graft (Table 2). Other diseases included cardiovascular disorders, tuberculosis, and hyperthyroidism, but there was no significant correlation among the impact of such diseases on the resorption rate.

### 3. Implant Size and Bone Resorption Rate

Maxillary bone graft surgery was performed in 28 maxillary sinuses of 24 patients, and 64 implants were placed in the bone graft regions. There was no significant correlation between the diameter, length of placed implant, and bone resorption rate (Table 3).

### 4. Implant Placement Region and Bone Resorption Rate

Among the bone resorption rates of the maxillary sinus base, the second premolar region showed the highest resorption rate with 28.1±15.5%, whereas the second molar

**Table 3. Mean resorption rate of bone materials according to implant size**

Fixture	Number of implants	Resorption rate (%) (Mean±SD)
Length (mm)	10	18.1±8.2
	11.5	23.2±10.6
Diameter (mm)	13	24.5±11.2
	3.75	17.5±10.2
	4	26.3±16.6
5	16	22.0±15.6

SD: standard deviation.

Ji-A Moon, et al: Retrospective Study of Bone Resorption after Maxillary Sinus Bone Graft. J Kor Dent Sci 2011.

**Table 4. Mean resorption rate of bone materials according to implant site**

Sites	Number of implants	Resorption rate (%) (Mean±SD)
1st premolar	6	23.2±13.5
2nd premolar	10	28.1±15.5
1st molar	27	24.4±14.2
2nd molar	21	19.2±9.8

SD: standard deviation.

Ji-A Moon, et al: Retrospective Study of Bone Resorption after Maxillary Sinus Bone Graft. J Kor Dent Sci 2011.

region showed the lowest resorption rate with  $19.2\pm 9.8\%$ . There was no significant difference by implant placement region, however (Table 4).

### 5. Bone Graft Material and Bone Resorption Rate

The average residual bone thickness before the surgery in the group who had single mandibular ramal bone graft was  $6.6\pm 2.4$  mm, and the average resorption rate of bone graft material was  $34.2\pm 19.6\%$ . The average residual bone thickness before the surgery in the group who had combined graft of ramal bone and Bio-Oss<sup>®</sup> was 4.5 mm, and the average resorption rate of bone graft material was  $24.5\pm 10.2\%$ . The average residual bone thickness before the surgery in the group who had the combined graft of maxillary tuberosity and Bio-Oss<sup>®</sup> was 6.3 mm, and the average resorption rate of bone graft material was  $19.4\pm 7.8\%$ . The average residual bone thickness before the surgery in the group who had the combined graft of mandibular ramal bone, maxillary tuberosity, and Bio-Oss<sup>®</sup> was 4.8 mm, and the average resorption rate of bone graft material was  $16.5\pm 6.2\%$ . The graft material resorption rate in single ramal bone graft was significantly high compared to the other graft material groups ( $p < 0.05$ ), and there was no difference in the resorption rates of the other groups (Table 5).

### 6. Residual Alveolar Bone and Bone Resorption Rate

The average height of residual alveolar bone before the surgery was  $5.4\pm 2.6$  mm, and the average height of alveolar bone after the surgery was  $20.8\pm 3.4$  mm and the average amount of bone augmentation was  $15.4\pm 4.0$  mm. The average height of alveolar bone 6 months after the surgery on the average was  $17.4\pm 3.2$  mm, and the average bone resorption rate was  $3.4\pm 2.2$  mm ( $22.1\pm 14.3\%$ ) compared to

that just after the surgery. There was no significant difference in the grafted bone resorption rates of the groups with less than 4 mm and more than 4 mm residual ridge heights. Neither was there any significant correlation between residual ridge thickness and bone resorption rate (Table 6).

### 7. Clinical Evaluation on Implants

In one maxillary sinus among the 28 sinuses of 24 patients who had maxillary sinus bone graft, perforation of the mucous membrane occurred when the mucous membrane was elevated but was cured without any specific abnormality by positioning Collatape<sup>®</sup> (Zimmer Dental, Carlsbad, CA, USA) in the perforated region and performing bone graft. During the monitoring period of one year and nine months (10 months~two years and 4 months) on the average on 64 implants, one implant of a male patient in his 70s and with no systemic disease showed agitation and led to osseointegration failure. On the other hand, one implant of a male patient in his 60s and with diabetes maintained its function but showed more than 1 mm progressive bone resorption 6 months after the surgery. The success rate and survival rate of the implants were 96.9% and 98.4%, respectively.

### Discussion

Maxillary sinus bone graft surgery is now predictable and is regarded as a safe surgical procedure. Most of the biocompatible bone graft materials are known to yield a good result in terms of the survival rate of implant, but maxillary sinus bone graft materials may be absorbed over time<sup>12)</sup>. Bone graft materials include allogeneous bone, xenogeneous bone, and synthetic bone. Drago and Sullivan<sup>3)</sup> reported in 1973 that autogeneos bone was a bone graft material with the highest capability to regenerate when it comes to alveolar bone defects. If maxillary sinus bone graft was performed using autogeneos bone, however, a lot of grafted bone was

Table 5. Mean resorption rate of bone materials according to graft material type

Graft material	Number of implants	Resorption rate (%) [Mean±SD]
Ra	10	34.2±19.6
Ra+BioOss	27	24.5±10.2
Mx tub+BioOss	19	19.4±7.8
Ra+Mx tub+BioOss	8	16.5±6.2
Total	64	

SD: standard deviation, Ra: ramus, Mx tub: maxillary tuberosity.

\*Statistically significant difference,  $P < 0.05$ .

Table 6. Mean resorption rate of bone materials according to residual ridge height

Residual ridge height	Number of implants	Resorption rate (%) [Mean±SD]
≤0.4 mm	26	25.2±14.2
>4 mm	38	20.1±12.8
Total	64	

found to be absorbed over time; thus, the combined materials of xenogenous bone and synthetic bone were often used. Kim et al.<sup>13)</sup> reported that there was no big difference (0.1 mm) in the resorption amount between the combination of a little autogenous bone and Bio-Oss<sup>®</sup> and a mixture of autogenous bone and the combined material of autogenous and Bio-Oss<sup>®</sup>. According to them, there was no significant merit in the combination of Bio-Oss<sup>®</sup> and demineralized bone and Bio-Oss<sup>®</sup> only in terms of bone healing and implant stability on a short-term basis. Maiorana et al.<sup>14)</sup> reported a 97% implant cumulative survival rate through 4 years of monitoring after performing maxillary sinus bone graft using synthetic bone (HA+ Collagen) or allogeneous bone (Bio-Oss<sup>®</sup>). According to them, such material can be useful in maxillary sinus bone graft surgery due to less resorption and securing of early implant stability appropriately.

Iliac bone is generally a source for harvesting enough bone, but such harvest may necessitate secondary surgery besides surgery on oral cavity, causing considerable donor bone resorption. Due to such shortcomings, the use of iliac bone is strictly limited in dental implant, and autogenous bone chips harvested especially from mandibular symphysis or ramus in the oral cavity are used. The biggest advantage of mandibular symphysis or ramus, intraoral bone is membranous bone. Such bone has been known to lead to less bone resorption after bone graft, more frequent revascularization of grafted bone tissue, and finally better combination with the host bone in the grafted region<sup>15)</sup>. An intraoral block bone harvested from mandibular symphysis is also effective like mandibular ramus but has shown many complications of permanent paresthesia in the mandibular tooth and lower lip, symphysis, and considerable inconvenience of the patient<sup>16)</sup>. In this research, the bone from mandibular ramus and maxillary tuberosity was used as autogenous bone for grafting. Such bone is useful for maxillary sinus bone graft due to the ease of harvest, absence of specific complication such as inconvenience after the surgery, and good osseointegration.

Graziani et al.<sup>17)</sup> stated that the use of tissue adhesive with particulate bone graft material can promote bone healing by preventing the fluctuation of the particles. In this research, the use of Tisseel<sup>®</sup>, a tissue adhesive, led to stability of graft material and hemostatic effect during the surgery in all cases.

The perforation of the maxillary sinus membrane is the

most frequent complication occurring during maxillary sinus bone graft surgery, and Ardekian et al.<sup>18)</sup> disclosed that its incident rate reached 20~62%. According to Cheong et al.<sup>19)</sup> the frequency of maxillary sinus abnormality increased the perforation possibility among patients scheduled for operation. Pikos<sup>20)</sup> stated that collagen membrane should be used in case of perforated size of less 5~10 mm, whereas the operation should be delayed in case of over 5~10 mm. In this research, perforation in one maxillary sinus mucous membrane occurred when the membrane was elevated, but it healed well without abnormality by positioning Collatape<sup>®</sup> in the perforated membrane, filling by using bone graft material and Tisseel<sup>®</sup>, and performing simultaneous implant placement.

Autogenous bone has high capability to regenerate bone compared to the other bone graft materials. Note, however, that graft by a combination of allogeneous bone and autogenous bone, synthetic bone, and xenogenous bone revealed that autogenous bone had faster and greater resorption compared to other bone graft materials<sup>5)</sup>. Various factors as well as the bone graft material type can be said to have an influence on the resorption rate of graft material. Herzberg et al.<sup>21)</sup> reported in the study on 70 patients who had maxillary sinus bone graft and implant placement during the period 1995~2000 that the dangerous factors in bone resorption were smoking and implant with small surface area, but there was no big difference between simultaneous and delayed implant placements after maxillary sinus bone graft. In this research, implant placement was simultaneously done following maxillary sinus bone graft. This research reported that residual alveolar bone height of less than 4 mm tended to promote the resorption of graft material, and that implant with wide surface area can compensate for such resorption.

Regarding the patient's age, Kim and Lee<sup>22)</sup> reported no correlation between the resorption rate and the patient's age. In this research, patients in their 40s among the patient groups of 40s~70s showed significantly greater resorption (Table 1). Young people probably exhibited greater resorption of graft material due to active metabolism, whereas old people had less resorption rate due to increased capability to resist the resorption of graft material according to the decrease in bone density and bone mass and more bone calcification. Nonetheless, additional studies on that part are deemed necessary.

Regarding the systemic disease of the patient, Kim and Lee<sup>22)</sup> reported that osteoporosis and diabetes showed significant

decrease in the resorption rate compared to other systemic disease. In this research, there was no significant difference among the resorption rates by systemic disease. The small surface area of implant was reported to have the possible risk of increasing the resorption rate<sup>21)</sup>; in this research, however, there was no correlation between the implant size and resorption rate of graft material. According to Kim and Lee<sup>22)</sup>, there was no correlation with the implant placement region. Similarly, this research found no significant difference by placement region.

With regard to the bone graft material type, maxillary sinus bone graft using autogenous bone was found to lead to significant graft bone resorption over time. Hanato et al.<sup>4)</sup>, recommended using a combination of autogenous bone and allogeneous bone or xenogeneous bone. In this research, the resorption rate after the single graft of mandibular ramus bone was 34%, whereas that after a combined graft of mandibular ramus bone or maxillary tuberosity bone and Bio-Oss<sup>®</sup> was 19% and 24%, respectively. The resorption rate after a combined graft of mandibular ramus bone, maxillary tuberosity bone, and Bio-Oss<sup>®</sup> was 16%. Note that the resorption rate after a single graft of mandibular ramus bone was significantly high compared to other groups, corresponding to the results of existing studies, i.e., the resorption rate after single autogenous bone graft was significantly high compared to the rate after combination with allogeneous bone such as Bio-Oss<sup>®</sup>. Note, however, that there was no significant difference among the other groups except the group with graft using autogenous bone only.

With reference to the study result of Herzberg et al.<sup>21)</sup>, i.e., residual alveolar bone height of less than 4 mm tended to promote graft material resorption, this research divided the residual alveolar bone height into two groups of less than 4 mm and over 4 mm. As a result, there was neither significant difference in the resorption rate between the two groups nor significant correlation between residual alveolar bone thickness and resorption rate.

Herzberg et al.<sup>21)</sup> examined 70 patients with 212 implants placed in 81 maxillary sinus regions during the period 1995~2000 and reported 95.5% and 3.7% cumulative survival and success rates, respectively, for four and a half years. In this research, one implant of a male patient in his 70s with no systemic disease showed agitation and led to osseointegration failure, whereas one implant of a male patient in his 60s and with diabetes maintained its function but showed more than 1 mm progressive bone resorption 6 months after

the surgery. Therefore, the success rate and survival rate of the implants were 96.9% and 98.4%, respectively.

The other study that did monitoring for 5 years after maxillary sinus bone graft reported that continuous resorption occurred for one~three years after the surgery, becoming relatively stable after 3 years<sup>23)</sup>. Note, however, that this research had a short monitoring period of one year and nine months on the average after the graft surgery; additional monitoring for over 3 years is recommended in the future to check long-term stability. This research also had the limit of unequal sample size by group as well as small sample size. To contribute to accurate research results, the reinforcement of this part is strongly recommended.

## Conclusion

The evaluation results on the resorption level using the panorama X-ray pictures immediately after the surgery and 6 months after the surgery are as follows:

1. Among the resorption rates by age of maxillary sinus bone graft material, the rate of patients in their 40s was 34.0%, which was significantly high compared to that of patients in their 50s, 60s, and 70s ( $P<0.05$ ). There was no significant difference among patients in their 50s, 60s, and 70s.
2. The patient's systemic disease did not show significant correlation with the resorption rate of maxillary sinus bone graft material.
3. The grafted implant thickness and length did not show significant correlation with the resorption rate of maxillary sinus bone graft material.
4. Implant placement in the premolar region and molar region did not show significant correlation with the resorption rate of maxillary sinus bone graft material.
5. The single mandibular ramus graft showed significantly high resorption rate compared to the combined graft group of mandibular ramus bone and Bio-Oss<sup>®</sup>, combined graft group of maxillary tuberosity and Bio-Oss<sup>®</sup>, and combined graft group of mandibular ramus bone, maxillary tuberosity, and Bio-Oss<sup>®</sup> ( $P<0.05$ ).
6. As a result of examination by dividing residual alveolar bone into two groups of less than 4 mm and over 4 mm, there was no significant difference between the two groups; neither was there any correlation between residual alveolar bone thickness and resorption rate of maxillary sinus bone graft material.

7. Secondary surgery was performed 6 months later on the average. The success rate and survival rate during the monitoring period of one year and 9 months (10 months~2 years and 4 months) on the average were 96.9% and 98.4%, respectively.

Such results revealed that patients in their 40s, after maxil-

lary sinus bone graft, showed higher resorption rate than those in their 50s and over, and that single autogenous bone (mandibular ramus bone) graft led to higher resorption compared to the combined graft groups of autogenous bone and xenogenous bone.

## References

1. Boyne PJ, James RA. Grafting of the maxillary sinus floor with autogenous marrow and bone. *J Oral Surg.* 1980; 38: 613-6.
2. Mellonig JT, Bowers GM, Bailey RC. Comparison of bone graft materials. Part I. New bone formation with autografts and allografts determined by Strontium-85. *J Periodontol.* 1981; 52: 291-6.
3. Dragoo MR, Sullivan HC. A clinical and histological evaluation of autogenous iliac bone grafts in humans. I. Wound healing 2 to 8 months. *J Periodontol.* 1973; 44: 599-613.
4. Hatano N, Shimizu Y, Ooya K. A clinical long-term radiographic evaluation of graft height changes after maxillary sinus floor augmentation with a 2:1 autogenous bone/xenograft mixture and simultaneous placement of dental implants. *Clin Oral Implants Res.* 2004; 15: 339-45.
5. Johansson B, Grepe A, Wannfors K, Hirsch JM. A clinical study of changes in the volume of bone grafts in the atrophic maxilla. *Dento-maxillofac Radiol.* 2001; 30: 157-61.
6. Smolka W, Eggensperger N, Carollo V, Ozdoba C, Iizuka T. Changes in the volume and density of calvarial split bone grafts after alveolar ridge augmentation. *Clin Oral Implants Res.* 2006; 17: 149-55.
7. Misch CM. Comparison of intraoral donor sites for onlay grafting prior to implant placement. *Int J Oral Maxillofac Implants.* 1997; 12: 767-76.
8. Zijderveld SA, Schulten EA, Aartman IH, ten Bruggenkate CM. Long-term changes in graft height after maxillary sinus floor elevation with different grafting materials: radiographic evaluation with a minimum follow-up of 4.5 years. *Clin Oral Implants Res.* 2009; 20: 691-700.
9. Jensen OT, Shulman LB, Block MS, Iacono VJ. Report of the sinus consensus conference of 1996. *Int J Oral Maxillofac Implants.* 1998; 13 Suppl: 11-45.
10. Wennerberg A, Albrektsson T, Andersson B, Krol JJ. A histomorphometric and removal torque study of screw-shaped titanium implants with three different surface topographies. *Clin Oral Implants Res.* 1995; 6: 24-30.
11. Albrektsson T, Zarb G, Worthington P, Eriksson AR. The long-term efficacy of currently used dental implants: a review and proposed criteria of success. *Int J Oral Maxillofac Implants.* 1986; 1: 11-25.
12. Scarano A, Degidi M, Iezzi G, Pecora G, Piattelli M, Orsini G, Caputi S, Perrotti V, Mangano C, Piattelli A. Maxillary sinus augmentation with different biomaterials: a comparative histologic and histomorphometric study in man. *Implant Dent.* 2006; 15: 197-207.
13. Kim YK, Yun PY, Im JH. Clinical retrospective study of sinus bone graft and implant placement. *J Korean Assoc Maxillofac Plast Reconstr Surg.* 2008; 30: 249-57.
14. Maiorana C, Sigurtà D, Mirandola A, Garlini G, Santoro F. Sinus elevation with alloplasts or xenogenic materials and implants: an up-to-4-year clinical and radiologic follow-up. *Int J Oral Maxillofac Implants.* 2006; 21: 426-32.
15. Misch CM. Ridge augmentation using mandibular ramus bone grafts for the placement of dental implants: presentation of a technique. *Pract Periodontics Aesthet Dent.* 1996; 8: 127-35.
16. Raghoebar GM, Batenburg RH, Vissink A, Reintsema H. Augmentation of localized defects of the anterior maxillary ridge with autogenous bone before insertion of implants. *J Oral Maxillofac Surg.* 1996; 54: 1180-5.
17. Graziani F, Ducci F, Tonelli M, El Askary AS, Monier M, Gabriele M. Maxillary sinus augmentation with platelet-rich plasma and fibrinogen cryoprecipitate: a tomographic pilot study. *Implant Dent.* 2005; 14: 63-9.
18. Ardekian L, Oved-Peleg E, Mactei EE, Peled M. The clinical significance of sinus membrane perforation during augmentation of the maxillary sinus. *J Oral Maxillofac Surg.* 2006; 64: 277-82.
19. Cheong CS, Cho BH, Hwang DS, Jung YH, Naa KS. Evaluation of maxillary sinus using cone-beam CT in patients scheduled for dental implant in maxillary posterior area. *J Korean Assoc Oral Maxillofac Surg.* 2009; 35: 21-5.
20. Pikos MA. Maxillary sinus membrane repair: report of a technique for large perforations. *Implant Dent.* 1999; 8: 29-34.
21. Herzberg R, Dolev E, Schwartz-Arad D. Implant marginal bone loss in maxillary sinus grafts. *Int J Oral Maxillofac Implants.* 2006; 21: 103-10.
22. Kim BJ, Lee JH. The retrospective study of survival rate of implants with maxillary sinus floor elevation. *J Korean Assoc Oral Maxillofac Surg.* 2010; 36: 108-18.
23. Wiltfang J, Schultze-Mosgau S, Nkenke E, Thorwarth M, Neukam FW, Schlegel KA. Onlay augmentation versus sinuslift procedure in the treatment of the severely resorbed maxilla: a 5-year comparative longitudinal study. *Int J Oral Maxillofac Surg.* 2005; 34: 885-9.