

# Frenectomy for improvement of a problematic conventional maxillary complete denture in an elderly patient: a case report

Youssef S. Al Jabbari<sup>1,2\*</sup>, BDS, MS, PhD

<sup>1</sup>Dental Biomaterials Research and Development Chair, <sup>2</sup>Department of Prosthetic Dental Sciences, College of Dentistry, King Saud University College of Dentistry, Riyadh, Saudi Arabia

Maxillary labial and buccal frena are considered as normal anatomic structures in the oral cavity. However, they may exist intraorally as a thick broad fibrous attachment and/or become located near the crest of the residual ridge, thus interfering with proper denture border extension resulting in inferior denture stability, retention and overall patient satisfaction. This case report highlights the importance of clinical examination and treatment planning which may mandate preprosthetic surgery prior to fabrication of a new conventional complete denture. Adequate patient satisfaction with conventional complete dentures can be significantly increased after frenectomy. [J Adv Prosthodont 2011;3:236-9]

**KEY WORDS:** Frenectomy; Preprosthetic surgery; Complete denture; Treatment planning; Patient satisfaction

## INTRODUCTION

The number of patients who require complete maxillary and/or mandibular dentures will continue to increase as a result of the increasing proportion of the adult population older than 55 years.<sup>1</sup> It has been estimated that nearly 40 million patients in the United States are edentulous.<sup>2</sup> Before the implant era, therapy with complete dentures was the only available option for completely edentulous patients.<sup>3</sup> Normally, a sufficient number of patients demonstrate full satisfaction with denture usage and if there is a complaint, it is usually related to the mandibular denture.<sup>3,4</sup> It has been reported that the patient satisfaction with the complete dentures sometimes is related to the quality of the dentures, however, there is no clear evidence of a relationship between patient satisfaction and the denture supporting tissues or physical condition of the mouth.<sup>3,5</sup> Low satisfaction of patients with complete dentures has been related to poor adaptability of the patients and for those, treatment with implants enhanced their overall satisfaction.<sup>3</sup> Ability to adapt to new situations was found to be more difficult for elderly patients (65 years old and older).<sup>6</sup>

Careful patient examination and proper treatment planning play an important role in denture quality. Intraoral examina-

tion may reveal unfavorable conditions which may indicate preprosthetic surgery prior to initiation of the treatment. Maxillary frena are considered to be complicating factors in denture construction.<sup>7</sup> A problematic frenum is one that is large with a broad base migrated near the crest of the residual ridge. Therefore, early recognition and surgical removal of such a frenum will assure a more satisfactory treatment outcome with complete dentures.<sup>7</sup> Besides a large frena being a compromising factor for denture resistance and retention, large notches that are normally required to accommodate such frena are considered a "cleavage point". Therefore, these notches have been considered responsible for fracture of many dentures.<sup>7</sup> The purpose of this clinical report is to describe the attainment of an elderly patient's satisfaction with a maxillary complete denture resulted from proper examination, treatment planning and preprosthetic surgery (frenectomy).

## CASE REPORT

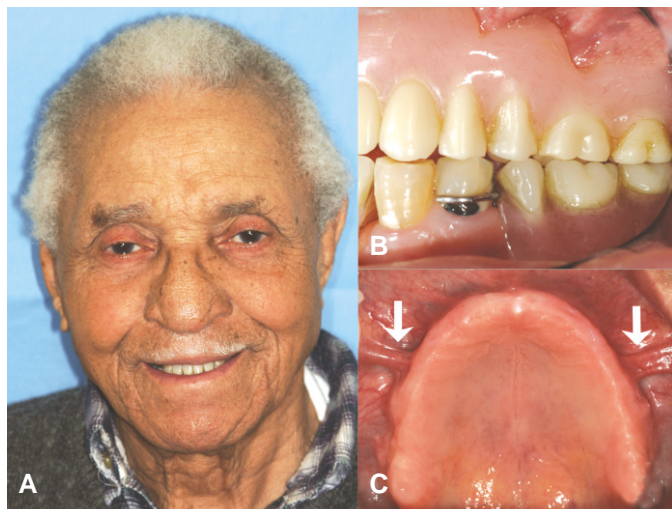An 83-year-old man presented to the prosthodontic specialty clinic to enhance the existing maxillary complete denture and/or to make a new denture with or without implant utilization. The patient was referred to prosthodontic clinic by an

Corresponding author: Youssef S. Al Jabbari  
Director, Dental Biomaterials Research and Development Chair, King Saud University College of Dentistry  
P.O.Box 60169, Riyadh 11545, Saudi Arabia  
Tel. 966 1 4677325: e-mail, yaljabbari@ksu.edu.sa  
Received July 1, 2011 / Last Revision August 18, 2011 / Accepted November 21, 2011

© 2011 The Korean Academy of Prosthodontics  
This is an Open Access article distributed under the terms of the Creative Commons Attribution Non-Commercial License (<http://creativecommons.org/licenses/by-nc/3.0>) which permits unrestricted non-commercial use, distribution, and reproduction in any medium, provided the original work is properly cited.

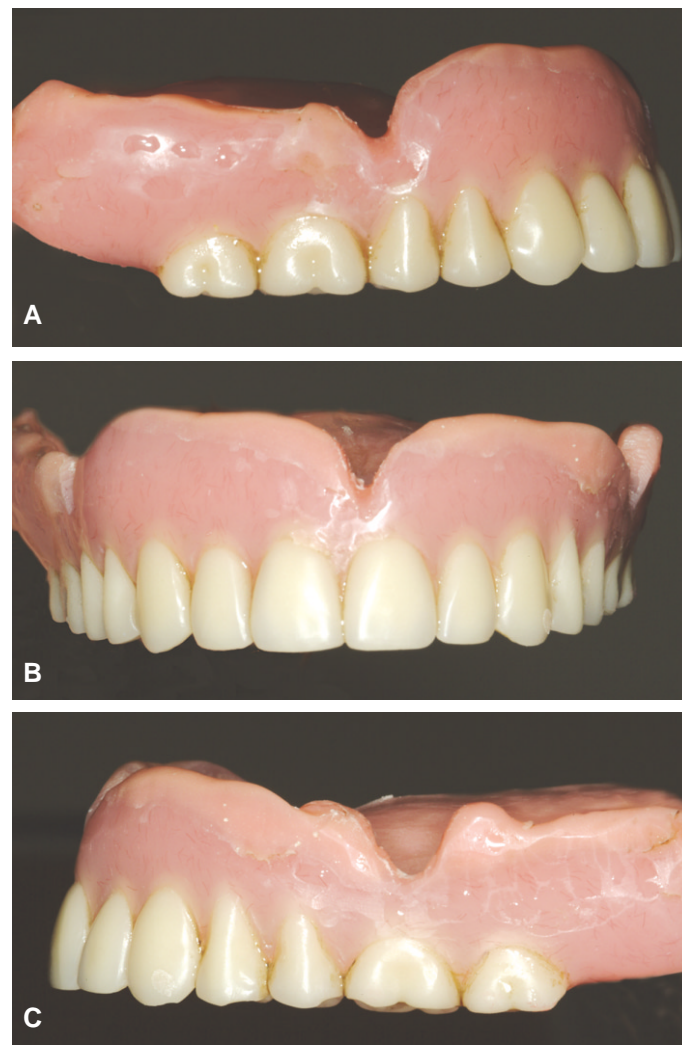
undergraduate student because of the patient's continual complaint about poor retention and stability of the maxillary complete denture. The patient was healthy and independent with hypertension that was medically controlled. The existing prosthesis, which was fabricated by the undergraduate student one year earlier, included a maxillary complete denture and a mandibular transitional RPD Kennedy Class I modification 1 which were made after extraction of his mandibular incisors keeping only the two mandibular canines and the first left premolar. The patient was not happy with the existing prosthesis and was not totally satisfied with a previous denture made by his dentist four years earlier. His major complaint with the first and second prostheses was mainly that the maxillary complete denture loosens while he is speaking. Multiple chair side hard and soft relines were performed over the previous year to enhance the retention and stability of the existing maxillary complete denture. Because of patient financial limitations, he wanted to avoid implant therapy if a new denture could be fabricated with adequate retention and resistance.

Upon intraoral examination of the maxilla, the maxillary right and left buccal frena appeared as thick/multiple fibrous bands giving them a "fan-shape" and along with the labial frenum, they were considered low and located close to the crest of the residual ridge (Fig. 1). The vestibules were considered shallow because of the frena anatomy; otherwise, the rest of the soft tissues appeared within normal limits. The edentulous ridge appeared broad, rounded, and covered by firm soft tissue. The patient was informed about the observed frena and had been told that they could be a causative factor for his complaint and for maxillary denture looseness. Therefore, he was advised that the frena should be removed surgically by a procedure called "frenectomy" before a new denture was made. Additionally,



**Fig. 1.** Pre-treatment views. A: Extra-oral view with the existing prosthesis, B: Intra-oral left lateral view of the complete denture, C: Occlusal view of the maxilla showing low and thick buccal frena (arrows).

he was told that if low satisfaction with the new complete denture continued, implant therapy would be considered. Before the patient was referred to the oral surgeon, the existing soft liners on the maxillary complete denture were removed and a new chair side hard reline (Flexacryl Hard, Lang Dental Mfg. Co, Inc., Wheeling, IL, USA) was performed. Fig. 2 shows the significant amount of relief (labial and buccal notches) needed to accommodate the frena after the chair side reline procedure. After the hard reline, clinical evaluation of occlusion and vertical dimension for the existing removable prosthesis found to be adequate. However, during subsequent visits patient was still complaining about the maxillary denture looseness at different time of day while he was speaking.



**Fig. 2.** Existing patient's maxillary denture after chair-side hard relining. A: Right lateral view, B: Frontal view, C: Left lateral view. Note the significant relief areas (labial and buccal notches) that were required to accommodate the low and thick frena.

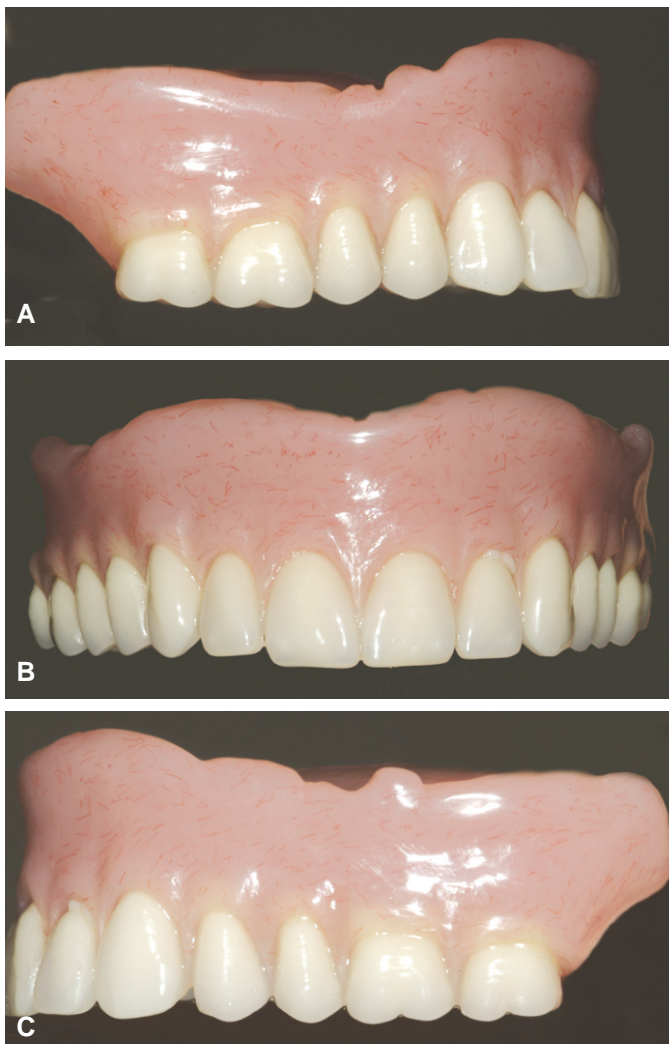
Then the patient was referred to the oral surgeon to perform the frenectomy. At the time of appointment for frenectomy, the treating prosthodontist was available to utilize the existing denture as a stent to support and stabilize the tissue attachments in the new position. Because of the existence of broad frena and shallow vestibules, the oral surgeon decided to perform the frenectomy with the Z-plasty technique because of its usefulness in such situation where simultaneous frenum elimination and vestibule lengthening can be achieved. When simultaneous frena excision and vestibule deepening with the Z-plasty technique were completed, and after final suturing, a soft denture reline material (Coe-Comfort, GC America, Inc., Alsip, IL, USA) was placed on the existing denture and carefully inserted into the patient's mouth. A gentle border mold-

ing was performed before the denture was removed from the mouth and then the excess reline material was trimmed around the borders. According to a previously suggested protocol,<sup>7,8</sup> the patient was instructed to keep the denture in place for the next 24 hours including sleep time and to minimize the in-out placement of the denture during the initial stages of healing (normally the first 3 - 5 days). The sutures were removed after 7 days. During post-surgical week one and two, the initial soft denture reline material was replaced with new material twice. On the third post-surgical week, a different denture reline material was used (Coe-Soft, GC America, Inc.) and left in place for an additional three weeks.<sup>7,8</sup> The definitive maxillary complete denture construction was initiated six weeks following the surgical frenectomy procedure.<sup>2,7,8</sup>

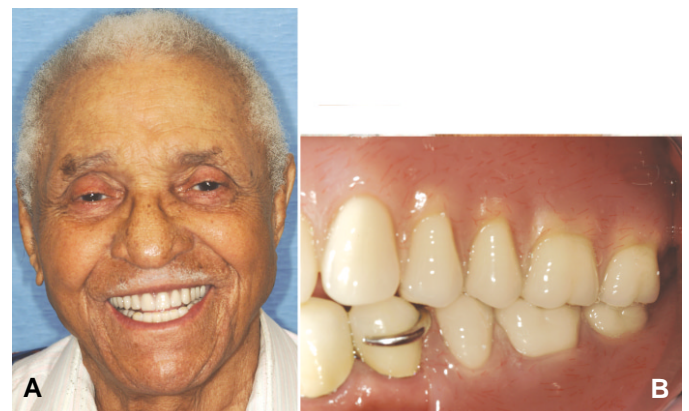The full mouth rehabilitation of the patient was achieved following the proposed treatment plan and the rendered treatment was performed according to classical recommendations in text books and literature<sup>2,9</sup> for delivering such prosthodontic therapy. The final complete maxillary denture had longer border extensions (Figs. 3 and 4). Post-treatment follow-up appointments indicated that the patient was fully satisfied with the final treatment outcome. Currently, it has been over a year since the treatment was completed and the patient is functioning well with the denture.

## DISCUSSION

Previous findings<sup>3,5</sup> which reported that the quality of the dentures and physical conditions of the mouth had little influence on satisfaction of denture patients, should be interpreted with caution, because others suggested that presence of large denture notches to accommodate thick frena will compromise denture seal leading to air leak in and retention loss.<sup>2</sup> Additionally,



**Fig. 3.** Newly fabricated maxillary denture after frenectomy. A: Right lateral view, B: Frontal view, C: Left lateral view. Note the improved borders extension of the denture compared to what is shown in Fig. 2.



**Fig. 4.** Post-treatment views. A: Extra-oral view with the newly fabricated prosthesis, B: Intra-oral left lateral view of the complete denture.

this clinical report demonstrated adequate patient satisfaction after enhancement of the quality of the supporting tissue. It is true that being elderly can lead to increased difficulty adapting to complete dentures<sup>5</sup>, however, the prosthodontist should consider the elderly patient's complaint about his/her denture as a legitimate complaint unless it is proved otherwise by careful examination of the oral supporting tissues and evaluation of the existing dentures. The majority of edentulous patients have been reported to have adequate satisfaction with their dentures.<sup>3</sup> Those few patients with continuing complaints were classified as true maladaptive patients because they had good quality of denture-supporting tissues and received adequate/proper technical treatment.<sup>3</sup>

During the implant era, preprosthetic surgery has been overlooked by many prosthodontists and whenever improvement of denture retention and stability is needed, it is normally achieved by dental implants.<sup>6</sup> However, prosthodontists should keep in mind the following: 1) not every patient can afford implant therapy, especially elderly patients due to limited economic status; 2) preprosthetic surgery alone can sometimes be enough for improvement of denture retention and stability; and 3) Hillerup<sup>6</sup> has stated that "many clinical conditions, especially in the maxilla, cannot be managed solely with implants. The combination of preprosthetic surgery and implants may solve problems that either discipline cannot solve

alone". This clinical report supports that preprosthetic surgery is sometimes helpful for enhancement of future complete dentures, thus preventing patients from going through a more expensive and time-consuming treatment with dental implants.

## REFERENCES

1. Douglass CW, Shih A, Ostry L. Will there be a need for complete dentures in the United States in 2020? *J Prosthet Dent* 2002;87:5-8.
2. Zarb GA, Carlsson GE, Bolender CL. Boucher's prosthodontic treatment for edentulous patients. 11th ed. St. Louis: Mosby; 1997. p. 46-7.
3. Carlsson GE, Omar R. The future of complete dentures in oral rehabilitation. A critical review. *J Oral Rehabil* 2010;37:143-56.
4. Christensen GJ. Treatment of the edentulous mandible. *J Am Dent Assoc* 2001;132:231-3.
5. van Waas MA. The influence of clinical variables on patients' satisfaction with complete dentures. *J Prosthet Dent* 1990;63:307-10.
6. Hillerup S. Preprosthetic surgery in the elderly. *J Prosthet Dent* 1994;72:551-8.
7. Axinn S, Brasher WJ. Frenectomy plus free graft. *J Prosthet Dent* 1983;50:16-9.
8. Costello BJ, Betts NJ, Barber HD, Fonseca RJ. Preprosthetic surgery for the edentulous patients. *Dent Clin North Am* 1996; 40:19-38.
9. Driscoll CF, Masri RM. Single maxillary complete denture. *Dent Clin North Am* 2004;48:567-83.