

Case Report

Pulsed Radiofrequency Neuromodulation Treatment on the Lateral Femoral Cutaneous Nerve for the Treatment of Meralgia Paresthetica

Hyuk Jai Choi, M.D., Seok Keun Choi, M.D., Tae Sung Kim, M.D., Young Jin Lim, M.D.

Department of Neurosurgery, School of Medicine, Kyung Hee University, Seoul, Korea

We describe a rare case of pulsed radiofrequency treatment for pain relief associated with meralgia paresthetica. A 58-year-old female presented with pain in the left anterior lateral thigh. An imaging study revealed no acute lesions compared with a previous imaging study, and diagnosis of meralgia paresthetica was made. She received temporary pain relief with lateral femoral cutaneous nerve blocks twice. We performed pulsed radiofrequency treatment, and the pain declined to 25% of the maximal pain intensity. At 4 months after the procedure, the pain intensity did not aggravate without medication. Pulsed radiofrequency neuromodulation treatment on the lateral femoral cutaneous nerve may offer an effective, low risk treatment in patients with meralgia paresthetica who are refractory to conservative medical treatment.

Key Words : Meralgia paresthetica · Lateral femoral cutaneous nerve · Pulsed radiofrequency · Neuromodulation.

INTRODUCTION

Meralgia paresthesia (MP) is a clinical pain syndrome characterized by numbness, a tingling sensation, pain, or a burning sensation in the anterior lateral thigh resulting from compression of the lateral femoral cutaneous nerve (LFCN)⁶. Because the LFCN is a purely sensory nerve, no associated motor or reflexes are present in patients with MP¹⁵.

In most patients with MP, satisfactory pain relief is expected from conservative treatments such as weight reduction or medication. However, a small group of patients do show medically intractable pain. More aggressive treatment tools have been considered for such patients, including LFCN blocks and surgical procedures (including neurolysis, trans position or transection of the LFCN)⁸. However, the effects of nerve block are generally temporary, and surgical treatments are invasive and risk further complications. In this case, we treated MP refractory to conservative treatment by pulsed radiofrequency (PRF) and found that it may be an effective, low risk alternative treatment.

CASE REPORT

A 58-year-old very obese female with a history of chronic low back pain presented with severe numbness and a tingling sensation in the left anterior lateral thigh. Severe disabling conditions had manifested over a 4-month period. The numbness and tingling sensation lasted no more than 5 minutes per episode, and the pain attacks occurred 40-50 times a day. A neurological examination was normal, except for the severe numbness and tingling sensation in the left anterior lateral thigh.

Lumbar magnetic resonance imaging (MRI) revealed no acute lesions except for a mild posterior disc bulging at the L2-3 level. This lesion was unchanged when compared with a lumbar MRI taken two years prior. Her chronic back pain was relatively well controlled without medication, but her thigh pain was unresponsive to conservative treatment with medication. Before visiting our outpatient clinic, the patient had undergone various treatments including weight reduction, medication, and acupuncture around the left anterior lateral thigh. However, her symptoms did not improve, and instead had progressed. Treatment with non-steroidal anti-inflammatory drugs and anticonvulsants was unhelpful, as was using suspenders instead of a belt to avoid waist compression. LFCN blocks using a local anesthetic and steroids were performed twice at 1-week intervals in our outpatient clinic. These blocks provided temporary pain relief that lasted about 1 week. After the positive results of the diagnostic nerve blocks, the patient was scheduled for PRF

• Received : February 28, 2011 • Revised : April 24, 2011

• Accepted : August 16, 2011

• Address for reprints : Tae Sung Kim, M.D.

Department of Neurosurgery, School of Medicine, Kyung Hee University,
1 Hoegi-dong, Dongdaemun-gu, Seoul 130-702, Korea
Tel : +82-2-958-8385, Fax : +82-2-958-8380

E-mail : kumckts@chol.com

treatment of the LFCN.

We performed fluoroscopically guided selective LFCN PRF using a NeuroTherm NT1,000 (NeuroTherm, Inc., Middleton, MA, USA) radiofrequency generator. In the operating room, the patient's position was supine. The target site was prepped with betadine and aseptically draped, and the anterior superior iliac spine was identified under C-arm fluoroscopy. A disposable 20-gauge, 15 cm radiofrequency cannula (Model S-1505, NeuroTherm, Inc., Middleton, MA, USA) with a 5 mm active tip was inserted (Fig. 1). The introducer needle was withdrawn and the disposable RF electrode (Model RFDE-15, NeuroTherm, Inc., Middleton, MA, USA) was advanced. This was accomplished without bleeding.

Selective stimulation of sensory fibers (50 Hz) showed concordant pain between 0.3 and 0.5 V, which confirmed proper localization of the PRF electrode. Motor stimulation was negative at 1.7 V. After stimulation, PRF lesioning was performed for a total of 240 pulses. The pre-set maximal temperature was 42°C. After the procedure, her pain, as measured on a visual analog scale, had decreased by 75% without medication. The pain intensity did not aggravate after 4 months of follow-up without medication.

DISCUSSION

Meralgia paresthetica is a compressive mononeuropathy with a reported population incidence of 1 in 10,000. It results from compression of the LFCN where it crosses between the anterior superior iliac spine (ASIS) and the inguinal ligament to enter the thigh^{4,5}. Because the LFCN is purely sensory, clinical symp-

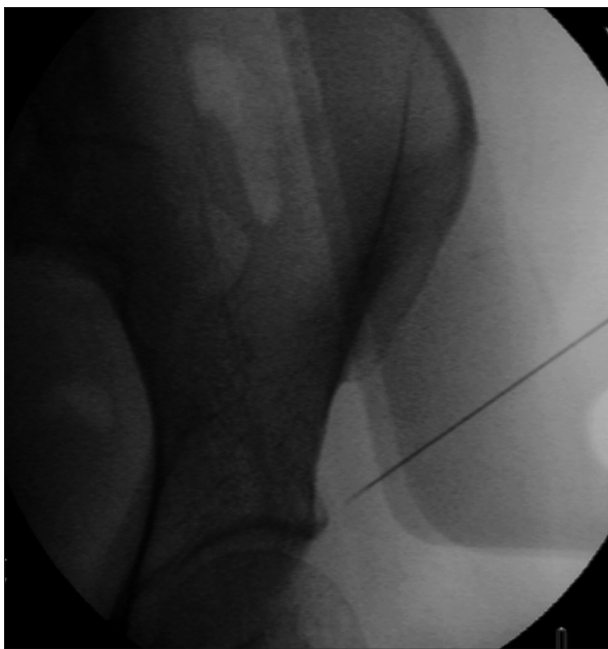


Fig. 1. An anteroposterior radiograph showing the entry point of the radiofrequency needle inserted to block the lateral femoral cutaneous nerve below the anterior superior iliac spine under the inguinal ligament.

toms are characterized by numbness, tingling, pain, or a burning sensation without motor symptoms in the anterior lateral thigh¹⁵.

More than half of patients with MP are successfully managed with conservative treatment, including weight reduction, avoidance of a tight belt, and medication. A small group derive lasting relief from an LFCN block¹¹. When patients do not respond to these treatments, physicians consider spinal cord stimulation, PRF, chemical or surgical neurolysis, or surgical nerve transection^{1,8,11,12}. In this case, LFCN blocks provided temporary pain relief, but symptoms recurred within 1 week. Moreover, our patient strongly refused surgery. Thus, we recommended PRF neuromodulation treatment.

Two types of radiofrequency lesioning are clinically used, conventional radiofrequency and PRF. PRF neuromodulation is non-destructive but can relieve pain by delivering an electrical field to neural tissue^{10,16}. While the effects of conventional radiofrequency thermal lesioning have a clear pathophysiological background in the destruction of nerve tissue and the subsequent blockade of pain transmission, the mechanism of PRF is still unknown. One theory that explained PRF suggests a neuromodulatory effect via changes in gene expression in pain processing neurons^{2,3,7}. There are several advantages to using PRF for pain control: 1) it may provide long lasting pain relief with less side effects; 2) it can be repeated if the pain recurs, since no tissue has been destroyed¹⁰; and 3) many published reports have revealed the efficacy of PRF for peripheral nerve lesions^{10,12,14}. Thus, PRF is a promising treatment for patients with chronic pain refractory to conservative treatment.

The LFCN typically arises from the dorsal branches of the ventral rami of the L2 and L3 spinal nerves. After emerging from the lateral border of the psoas major, the LFCN travels across the iliac muscle toward the ASIS, and then enters the anterior lateral thigh by passing under, through, or above the inguinal ligament. In most individuals, the LFCN crosses into the anterior lateral thigh approximately 1 cm medial to the ASIS. However, the relationship of the LFCN to the ASIS is quite variable. The nerve may cross into the anterior lateral thigh as much as 2 cm lateral or 6 cm medial to the ASIS. A bifurcation into anterior and posterior divisions occurs approximately 5-12 cm below the anterior superior iliac spine^{9,13}. Kosiyatrakul et al.⁹ reported that 58.3% of LFCNs passed medial to the ASIS, 22.9% passed at the ASIS, and 18.8% passed lateral to it. While the medial branch, dorsal root ganglion, and suprascapular nerve have confident bony landmarks for local injection and PRF neuromodulation, the LFCN landmarks are relatively uncertain. Thus, it is difficult to accurately target the LFCN due to its anatomical variations⁹. On the other hand, nerve blocks with injections may deliver their effects through diffusion to the surrounding tissue, which means relatively inaccurate targeting can be tolerated. However, when ablating the nerve with radiofrequency, the practitioner should be aware of the exact anatomy, because lesion creation should be more restricted and exact. In this case, the nerve was found and

targeted somewhat inferior to the usual location of the LFCN block (Fig. 1). More clinical trials and studies are needed for better identification of the target point.

CONCLUSION

Experience and documentation of PRF neuromodulation of the LFCN is rare. But, PRF neuromodulation of the LFCN may offer an effective, low risk treatment in patients with meralgia paresthetica who are refractory to conservative treatment or are unwilling or unfit to undergo surgery. Further controlled prospective studies are necessary to evaluate the exact effects and long term outcomes of this method.

References

- Barna SA, Hu MM, Buxo C, Trella J, Cosgrove GR : Spinal cord stimulation for treatment of meralgia paresthetica. *Pain Physician* 8 : 315-318, 2005
- Cahana A, Vutskits L, Muller D : Acute differential modulation of synaptic transmission and cell survival during exposure to pulsed and continuous radiofrequency energy. *J Pain* 4 : 197-202, 2003
- Cosman ER Jr, Cosman ER Sr : Electric and thermal field effects in tissue around radiofrequency electrodes. *Pain Med* 6 : 405-424, 2005
- de Ridder VA, de Lange S, Popta JV : Anatomical variations of the lateral femoral cutaneous nerve and the consequences for surgery. *J Orthop Trauma* 13 : 207-211, 1999
- Dias Filho LC, Valença MM, Guimarães Filho FA, Medeiros RC, Silva RA, Morais MG, et al. : Lateral femoral cutaneous neuralgia : an anatomical insight. *Clin Anat* 16 : 309-316, 2003
- Friedlander WJ : Meralgia paresthetica. *U S Armed Forces Med J* 3 : 1857-1862, 1952
- Higuchi Y, Nashold BS Jr, Sluijter M, Cosman E, Pearlstein RD : Exposure of the dorsal root ganglion in rats to pulsed radiofrequency currents activates dorsal horn lamina I and II neurons. *Neurosurgery* 50 : 850-855; discussion 856, 2002
- Khalil N, Nicotra A, Rakowicz W : Treatment for meralgia paraesthetica. *Cochrane Database Syst Rev* : CD004159, 2008
- Kosiyatrakul A, Nuansalee N, Luenam S, Koonchornboon T, Prachaporn S : The anatomical variation of the lateral femoral cutaneous nerve in relation to the anterior superior iliac spine and the iliac crest. *Musculoskelet Surg* 94 : 17-20
- Munglani R : The longer term effect of pulsed radiofrequency for neuropathic pain. *Pain* 80 : 437-439, 1999
- Nouraei SA, Anand B, Spink G, O'Neill KS : A novel approach to the diagnosis and management of meralgia paresthetica. *Neurosurgery* 60 : 696-700; discussion 700, 2007
- Philip CN, Candido KD, Joseph NJ, Crystal GJ : Successful treatment of meralgia paresthetica with pulsed radiofrequency of the lateral femoral cutaneous nerve. *Pain Physician* 12 : 881-885, 2009
- Ray B, D'Souza AS, Kumar B, Marx C, Ghosh B, Gupta NK, et al. : Variations in the course and microanatomical study of the lateral femoral cutaneous nerve and its clinical importance. *Clin Anat* 23 : 978-984, 2010
- Rohof OJ : Radiofrequency treatment of peripheral nerves. *Pain Pract* 2 : 257-260, 2002
- Seror P, Seror R : Meralgia paresthetica : clinical and electrophysiological diagnosis in 120 cases. *Muscle Nerve* 33 : 650-654, 2006
- Son JH, Kim SD, Kim SH, Lim DJ, Park JY : The efficacy of repeated radiofrequency medial branch neurotomy for lumbar facet syndrome. *J Korean Neurosurg Soc* 48 : 240-243, 2010