2011. Vol.32. No.6. *117-121*
The Journal of Korean Oriental Medicine

Case Report

# Successful Treatment of Pleural Effusion in Small Cell Lung Cancer Patient with *Gunreyngtang-gagambang*

Henja Yun

Department of Oriental Medicine Prescription, Oriental Medical School, Wonkwang University

**Objectives:** We report one patient with pleural effusion and effusion-related symptoms in small cell lung cancer (SCLC) successfully treated with *Gunreyngtang-gagambang*.
**Methods:** *Gunreyngtang-gagambang* was administered at 30 minutes after mealtime, three times a day, for two months. Except for herbal medicine, the patient did not take any treatment including pharmaceutical or non pharmaceutical for effusion.
**Result:** Two months later, the symptoms and the pleural effusion had disappeared from chest X-ray.
**Conclusion:** *Gunreyngtang-gagambang* was effective for treatment of malignant pleural effusion due to small cell lung cancer.

***Key Words*** : *Gunreyngtang-gagambang*, pleural effusion, lung cancer, shortness of breath

## Introduction

Malignant pleural effusions occur in 7-15% of patients with lung cancer[1]. The accumulated fluids of symptomatic pleural effusion have to be removed in order to improve quality of life and reduce symptoms such as shortness of breath, chest pain, and coughing[2]. On lung cancer patients, thoracentesis can be performed to remove the fluid, but it frequently returns. To prevent fluid from accumulating, a pleurodesis may be conducted[2-6].

In the oriental medical area, there are some case reports of pleural effusions treated with herbal medicine. *Sibimiguanjung-tang*[7], *Joweeseungcheong-tang*[8] and *banhabokreyng-tang*[9] improved pleural effusion-related symptoms or got rid of accumulated fluid. However, these cases were not in lung cancer but in pneumonia[7,9] or cerebral infarction patients[8]. In this case report, *Gunreyngtang-gagambang* was shown to be effective in improving the symptoms and removing the loculated pleural effusion from the right major fissure of a small cell lung carcinoma patient.

## Case report

A 73-year old male visited an oriental medical clinic with shortness of breath coinciding with moving, a feeling of pressure on his chest, dizziness, lethargy and anorexia from three weeks ago. The patient had already received diagnosis for a chest disease in a western medical hospital one week ago. The radiologist read chest CT and X-ray image as a probable lung

· Received : 20 October 2011 · Revised : 27 October 2011 · Accepted : 27 October 2011
· Correspondence to : Henja Yun
Department of Oriental Medicine Prescription, Oriental Medical School, Wonkwang University
344-2 Shinyong-dong, Iksan-si, Jeollabuk-do, South Korea
Tel : +82-62-710-7575, Fax : +82-70-8620-7575, Email : bubudoctor@gmail.com

cancer involving a mediastinal pleura of the right lung upper lobe (5×4cm) and loculated pleural effusion (10×5cm) in the right major fissure. But the patient didn't take biopsy to confirm the cancer cell.

Laboratory examination revealed that hemoglobin (10.0g/dL), hematocrit (31.7%), RBC count (3.52 10^6/uL), MCHC (31.5%) platelet distribution width (9.30fL), albumin (3.6g/dL) and bilirubin total (0.2mg/dL) were lower, and eosinophil (25.0 5), CRP (1.05mg/dL), glucose (132mg/dL) and BUN (21mg/dL) were higher than a normal range. All urological examination factors were within normal limits. The patient's past medical history was anemia and gout. From an oriental medical diagnostic perspective, the pathological condition of the patient was categorized as a Gi deficiency and *damp-phlegm* on lung meridian.

*Gunreyngtang-gagambang* was administered at 30 minutes after mealtime three times a day for two months. The patient was on a diet to take eel. Except for herbal medicine, the patient didn't take any treatment, including western medical treatment. The prescription was composed as per Table 1.

The compounds for each 10 days were decocted in 6000ml water for two hours. The liquid was packed with 30-pouch packs, 100ml per a pack. Three weeks after administrating *Gunreyngtang-gagambang,* the symptoms, shortness of breath coinciding with moving, feeling a pressure on his chest, dizziness, lethargy and anorexia, regressed, and at the two months later, it was confirmed that loculated pleural effusion (10×5cm) in the right major fissure had disappeared from chest X-ray. However, there remained a probable lung cancer in the mediastinal pleura of the right lung upper lobe with suspicious invasion to the trachea and esophagus on chest CT.

On the biopsy, it was confirmed as small cell carcinoma. Hemoglobin (10.2 g/dL), hematocrit (32.1%), RBC count (3.74 10^6/uL), MCHC (27.4%) platelet distribution width (9.30fL), albumin (4.2g/dL) and bilirubin total (0.2mg/dL) were higher, and eosinophil (14.8%), CRP (1.0mg/dL) and BUN (17mg/dL) were lower compared with the previous examination. After identifying small cell lung cancer, chemotherapy was undertaken(Fig. 1).

## Consideration

The outcome of this case shows that *Gunreyngtang-gagambang* successfully treated pleural effusion and effusion-related symptoms in small cell lung cancer (SCLC). The patient had experienced shortness of

Table 1. Prescription of *Gunreyngtang-gagambang* Per Pack

| Herbal Medicine Name | Drug Name | Weight(gr) |
|---|---|---|
| *Insam* | *Radix Ginseng* | 8 |
| *Baekchul* | *Rhizoma Atractylodis Macrocephalae* | 8 |
| *Baekbokreyng* | *Poria* | 8 |
| *Singok* | *Massa Fermentata Medicinalis* | 4 |
| *Gwakhyang* | *Herba Pogostemonis* | 4 |
| *Jinpi* | *Pericarpium Citri* | 4 |
| *Sain* | *Amomi* | 4 |
| *Baekdugu* | *Fructus Amomi rotundus* | 4 |
| *Taeksa* | *Rhizoma Arismatis* | 6 |
| *Jeoreyng* | *Polyporus* | 6 |
| *Geongang* | *Rhizoma Zingiberi Fructus* | 4 |
| Total amount | | 60 |

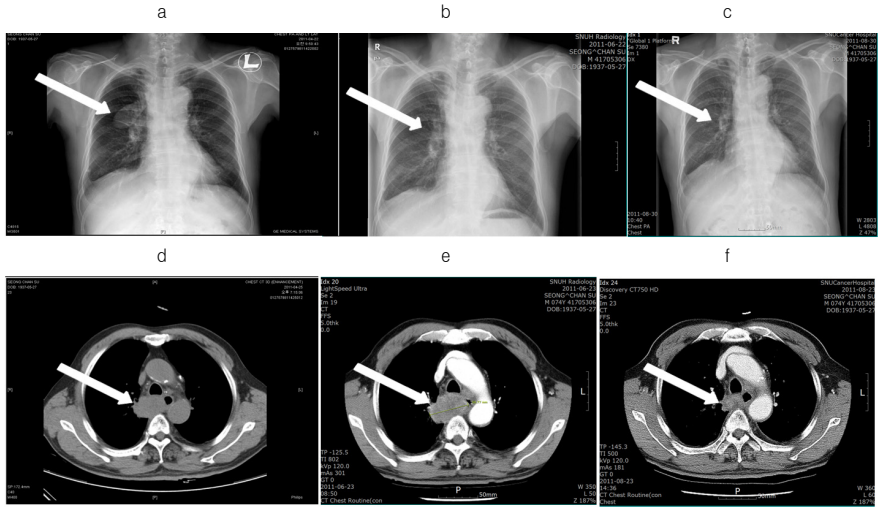


Fig. 1. Radiographic Images of Chest PA X-ray and CT Before and After Treatment with *Gunreyngtang-gagambang* and Chemotherapy.
(a) Loculated pleural effusion (10×5 cm) is shown in major fissure of right lung.
(b) When the patient takes a radiographic diagnosis after two months of receiving *Gunreyngtang-gagambang,* loculated pleural effusion has disappeared completely on a chest X-ray.
(c) Two months after terminating treatment of *Gunreyngtang-gagambang,* loculated pleural effusion is not still shown.
(d) Mass is shown in a mediastinal pleura of right lung upper lobe on chest CT at the same period of time with (a).
(e) After two months of administering *Gunreyngtang-gagambang,* mass is slightly grown at the same period of time with (b).
(f) Aftertwo cycles of chemotherapy, mass is shrunk at the same period of time with (c).

breath coinciding with moving, feeling a pressure on his chest, coughing, sputum, dizziness, lethargy and anorexia for three weeks before visiting a hospital to diagnose. The symptoms improved gradually from three weeks after administrating *Gunreyngtang-gagambang.* At six weeks after administration, shortness of breath, coughing and sputum had disappeared completely. Dizziness, anorexia and lethargy got better, but still remained. Typically, patients of pleural effusion manifest with the symptoms of coughing, shortness of breath, decreased exercise tolerance, and chest pain[2]. Therefore, it is thought that *Gunreyngtang-gagambang* has a therapeutic effect on pleural effusion-related symptoms. Dizziness seems to have manifested not from pleural effusion, but by anemia which the patient also had.

Diagnosis of pleural effusion is usually accomplished with a simple chest X-ray, although further radiographic tests, ultrasound and CT scan of the chest, may be needed to confirm the presence of pleural fluid[3]. In this case, the patient was diagnosed with probable lung cancer and loculated pleural effusion through radiographic diagnosis in a western medical hospital one week prior to visiting an oriental medical clinic. Loculated pleural effusion was in the major fissure of the right lung into 10×5cm size on a chest X-ray. When the patient took a radiographic diagnosis after two months of taking *Gunreyngtang-gagambang,* loculated pleural effusion had disappeared completely on a chest X-ray. Two months after terminating treatment of *Gunreyngtang-gagambang,* the pleural effusion also didn't show up in a follow-up X-ray image. Pleural effusions may be the presenting sign of cancer and are an important prognostic factor for survival[2]. Malignant pleural effusions occur in 7~15% of patients with lung cancer, most commonly in patients with adenocarcinomas[1].

The cytologic appearance of small cell carcinoma cells in the pleural fluid was first described in

1946[10]. The management of a malignant pleural effusion is necessary to improve quality of life and reduce symptoms such as shortness of breath[2]. Thoracentesis can be performed to remove the fluid, but it frequently returns[3]. To prevent fluid from accumulating, a procedure called a pleurodesis may be done[3], with a probability of success of 60 to 90% in malignant pleural patients[5,11]. Although this result is just one case, *Gunreyngtang-gagambang* showed a dramatic effect on malignant pleural effusion. It indicates that oriental herbal medicine may be an alternative therapeutic agent for malignant pleural effusion.

The cancer found in the mediastinal pleura of the right lung upper lobe on first enhancement CT scans of the patient slightly grew by two months later. Small cell lung cancer exhibits aggressive behavior, with rapid growth and early spread to distant sites[12-13]. From this perspective, mild growth of lung cancer was not likely due to *Gunreyngtang-gagambang*

*Gunreyngtang-gagambang* is a prescription composed of *Sagunja-tang* and *Oreyng-san* used to treat the fluid metabolism disorder of *Gi deficiency* people in an oriental medical area[14]. In this case, *Gunreyngtang-gagambang* successfully treated pleural effusion and effusion-related symptoms without deleterious effects on carcinoma itself in the small cell type lung cancer patient. These results suggest that *Gunreyngtang-gagambang* may be an alternative pharmaceutical for malignant pleural effusion.

## References


1. Conway AB, Hart MK, Jessurun J, Pambuccian SE. "Cannonballs" and Psam- moma Bodies: Unusual cytologic features of metastatic pulmonary small-cell carcinoma in a Pleural Effusion. Diagnostic Cytopathology. DOI 10.1002/dc.
2. Uzbeck MH, Almeida FA, Sarkiss MG, Morice RC, Jimenez CA, Eapen GA, Kennedy MP. Management of malignant pleural effusions. Adv Ther. 2010; 27(6):334-347.
3. Fenton KN, Richardson JD. Diagnosis and management of malignant pleural effusions. Am J Surg. 1995; 170:69-74.
4. Seaton KG, Patz EF, Goodman PC. Palliative treatment of malignant pleural effusions: value of small-bore catheter thoracostomy and doxycycline sclerotherapy. American Journal of Roentgenology. 1995; 164(3):589-591.
5. Patz EF Jr, McAdams HP, Goodman PC, Blackwell S, Crawford J. Ambulatory sclerotherapy for malignant pleural effusions. Radiology. 1996; 199(1):133-135.
6. Goff BA, Mueller PR, Muntz HG, Rice LW. Small chest-tube drainage followed by bleomycin sclerosis for malignant pleural effusions. Obstetrics and Gynecology. 1993; 81(6):993-996.
7. Ha JH, Choi AR, Kim ST, Goo DM. A case report of Soeumin diagnosed to pleural effusion. J of Sasang constitutional medicine. 2011; 23(1):125-131.
8. Choi KJ, Lee TG, Lee Sk, Koh BH, Song IB. A case of Taeumin diagnosed to pleural effusion. J of Sasang constitutional medicine. 2004; 16(1):162-167.
9. Kim SU, Moon SH, Heo YR, Han IS, Choi JH, Son JS, et al. A case of atypical pneumonia with pleural effusion. Korean J. Oriental Med. 2001; 22(3):489-494.
10. Bamforth J. The examination of the sputum and pleural fluid in the diagnosis of malignant disease of the lung. Thorax. 1946; 1:118-127.
11. Reshad K, Inui K, Takeuchi Y, Takahashi Y, Hitomi S. Treatment of malignant pleural effusion. Chest. 1985 Sep; 88(3):393-7.
12. Boffetta P, Trichopoulos D. Cancer of the lung, larynx, and pleura. In: Adami H, Hunter D, Trichopoulos D, eds. Textbook of *Cancer Epidemiology*. 2nd ed. New York, NY: Oxford University

Press. 2008:349-67.

13. Krug LM, Kris MG, Rosenzweig K, Travis WD. Cancer of the lung. In: DeVita VT Jr, Hellman S, Rosenberg SA, eds. *Cancer: Principles & Practice of Oncology*. 8th ed. Philadelphia, Pa: Lippincott Williams Wilkins. 2008:947-66.

14 Hwang DY. Bangyakhappeyn. Haenglim. 1983: 104-105.