

Case Report

Endovascular Treatment Using Graft-Stent for Pseudoaneurysm of the Cavernous Internal Carotid Artery

Jun Kyeung Ko, M.D.,¹ Tae Hong Lee, M.D.,² Jae Il Lee, M.D.,¹ Chang Hwa Choi, M.D.¹

Departments of Neurosurgery,¹ Diagnostic Radiology,² School of Medicine, Pusan National University, Busan, Korea

A 57-year-old man presented with a 2-day history of left oculomotor palsy. Digital subtraction angiography revealed a pseudoaneurysm of the left cavernous internal carotid artery (ICA) measuring 37×32 mm. The pseudoaneurysm was treated with a balloon expandable graft-stent to occlude the aneurysmal neck and preserve the parent artery. A post-procedure angiogram confirmed normal patency of the ICA and complete sealing of the aneurysmal neck with no opacification of the sac. After the procedure, the oculomotor palsy improved gradually, and had completely resolved 3 months after the procedure. A graft-stent can be an effective treatment for a pseudoaneurysm of the cavernous ICA with preservation of the parent artery.

Key Words : Internal carotid artery · Pseudoaneurysm · Graft-stent · Oculomotor palsy.

INTRODUCTION

A pseudoaneurysm of the cranial internal carotid artery (ICA) is a rare, but can be a serious complication following blunt or penetrating trauma. Traditional surgical repair of these lesions is often technically demanding and associated with a high rate of morbidity and mortality¹⁴. An endovascular approach to pseudoaneurysms of the cranial ICA limits the risk of operative damage to surrounding structures and the potential for substantial blood loss^{8,14}. Placement of graft-stents as treatment for pseudoaneurysms of the cranial ICA has recently been reported^{13-15,17,18}. The advantages of this minimally invasive approach make such a therapeutic strategy very attractive.

We describe a case successfully treated by application of graft-stent for pseudoaneurysm of the cavernous ICA to ensure a normal patency of the ICA.

CASE REPORT

This case involves a 57-year-old man with a significant history of smoking and alcohol abuse. Upon presentation to the emergency department, the patient had 2-day history of left ptosis and

disturbance of eye movement with pupillary dilatation. An ophthalmologist suggested that an intracranial lesion was causing an oculomotor palsy. The patient did not recall any trauma, but his family provided several occasions of trauma related to his alcohol abuse. His initial Glasgow Coma Scale score was 15 (eye, 4; motor, 6; verbal, 5) and his left pupil was dilated approximately 6 mm and was not reactive.

The initial magnetic resonance imaging (MRI) and MR angiography revealed a large aneurysm of the left cavernous ICA protruding into the sphenoid sinus (Fig. 1). Computed tomography showed mucosal thickening within the sphenoid sinus with fracture of the lateral wall. Digital subtraction angiography, performed under local anesthesia, confirmed an aneurysm of the left cavernous ICA, measuring 37×32 mm (Fig. 2A). Radiological findings and the history of the head trauma led us to the diagnosis of carotid pseudoaneurysm. Balloon test occlusion (BTO) was performed to assess the risk of stroke following total ICA trapping, but was not tolerated for 20 minutes with decreased visual acuity (Fig. 2B). Because of poor tolerance to the BTO, a balloon expandable graft-stent was deployed to occlude the aneurysmal neck and preserve the parent artery.

The patient was fully awake during the procedure, and the electrocardiogram, arterial oxygen saturation, and blood pressure were appropriately monitored. Baseline activated clotting times (ACT) were obtained before the procedure. Percutaneous access was obtained via the right femoral artery, and a 6F sheath was inserted. Systemic heparinization and a bolus injection of heparin (3000 IU) were administered before the therapeutic

• Received : November 12, 2010 • Revised : January 6, 2011
• Accepted : July 1, 2011
• Address for reprints : Tae Hong Lee, M.D.
Department of Diagnostic Radiology, Pusan National University Hospital,
179 Gudeok-ro, Seo-gu, Busan 602-739, Korea
Tel : +82-51-240-7354, Fax : +82-51-244-7534
E-mail : drcello@pusan.ac.kr

procedure; an additional 1,000 IU bolus of heparin was administered every hour to maintain an ACT >250 seconds throughout the procedure. A 6F guiding catheter (Envoy; Cordis Endovascular Corporation, Miami, FL, USA) was navigated into the cavernous ICA segment, and pre-procedural angiograms were obtained in orthogonal planes. The mean size of involved ICA was 3.6 mm in diameter. A 300-cm long, 0.014-in microwire (Transend 14; Target/Boston Scientific, Natick, MA, USA) was navigated into the third segment of the MCA (M3). A 4/19 mm-sized graft-stent (GraftMaster; Abbott Vascular Devices, Amersfoort, The Netherlands) was then advanced over the microwire and positioned across the neck of the pseudoaneurysm by using roadmap imaging and external stent markings, and the position was angiographically-confirmed (Fig. 2C). We then deployed the stent using the roadmap image, inflating slowly up to 12 atm, at which the graft-stent diameter increased to 4.21 mm (Fig. 2D). Following stent deployment, the post-procedure angiogram confirmed the normal patency of the ICA and perfect sealing of the aneurysm neck with no opacification of the sac (Fig. 2E).

Pre-medication was not given, as the patient underwent emergency treatment. However, after the procedure, the patient received 100 mg aspirin and 75 mg clopidogrel (Plavix; Sanofi-Synthelabo, Seoul, Korea) daily for one year according to our protocol for graft-stent placement in cerebral vessels. After the procedure, the oculomotor palsy improved gradually and had completely resolved 3 months after the procedure.

A follow-up angiography 10 months post-operatively demonstrated stable occlusion of the pseudoaneurysm and no alteration in the patency of the ICA (Fig. 2F).

DISCUSSION

A pseudoaneurysm of the intracranial ICA is a rare complication after a blunt or penetrating traumatic injury, previous dissection of the vessel, inflammation, or previous surgery. Theoretically, patients with pseudoaneurysms of the cranial ICA are at risk for distal thromboembolism, continued enlargement with vessel occlusion, and rebleeding with intracranial hemorrhage¹⁵.

Historically, such pseudoaneurysms have been managed with anticoagulants, surgical repair, coils, bare stent placement with or without coil embolization, and coronary covered stents^{5,8,13-15,17,18}. Although recent reports support an improvement in outcome for patients managed with surgical reconstruction

compared with observation or anticoagulation therapy alone, surgical repair of carotid pseudoaneurysms is often technically demanding and associated with a high rate of morbidity and mortality^{6,10,12}. An endovascular approach to these pseudoaneurysms limits the risk of operative damage to surrounding structures and the potential for substantial blood loss.

Endovascular treatment of a pseudoaneurysm in the ICA includes sacrifice or preservation of the carotid artery. If a BTO is well-tolerated, trapping or parent artery occlusion is an option. However, 5-22% of patients passing the BTO develop ischemic complications, including cerebral infarcts^{9,16}. Therefore, preserving the patency of the carotid artery as far as possible is a

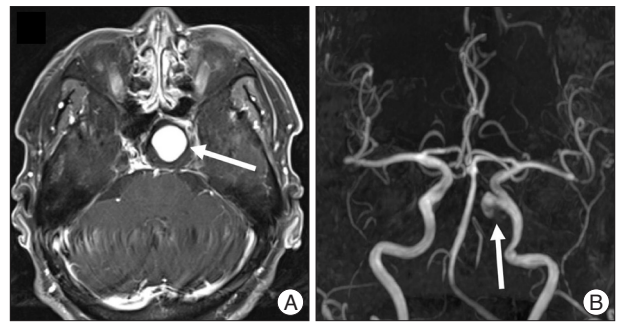


Fig. 1. Pre-treatment magnetic resonance and angiographic images. T1-weighted post-gadolinium magnetic resonance image (A) and magnetic resonance angiography (B) showing a large aneurysm (arrows) arising from the left cavernous internal carotid artery and protruding into the sphenoid sinus.

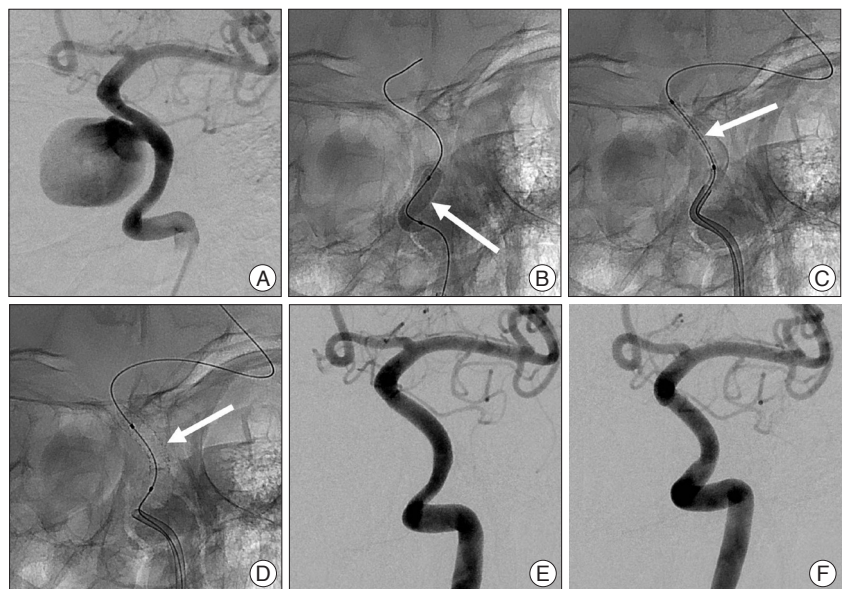


Fig. 2. A left internal carotid artery (ICA) angiogram (A) revealing the pseudoaneurysm in the cavernous portion, measuring 37×32 mm. Radiography (B) showing the balloon test occlusion (arrow) using a 4×20 mm balloon. Radiography (C) demonstrating a 4/26 mm-sized graft-stent (arrow) which was advanced over the microwire and positioned across the neck of the pseudoaneurysm just before stent deployment. After successful deployment of the graft-stent (arrow) across the aneurysmal neck (D), left ICA angiogram (E) revealing normal patency of the ICA and perfect sealing of the aneurysm neck with no opacification of the sac. A left ICA angiogram (F) obtained 10 months after the intervention showing the stable occlusion of the pseudoaneurysm and no alteration of the patency of the ICA.

more desirable goal. Moreover, sacrifice of the ICA was not an option in our case because of poor collateral circulation. Coil embolization and stent-assisted embolization of ICA pseudoaneurysms have been used for preservation of carotid artery patency. However, the lack of a true wall in these pseudoaneurysms and the absence of normal healthy tissue within the sella may result in extrusion of the coil and enlargement of the pseudoaneurysm^{1,4,7,11,19}. Graft-stents have been used more recently to overcome these problems in treating ICA pseudoaneurysms^{2,5,13-15,18}. Several issues have been raised regarding the therapy of ICA pseudoaneurysms, including anticoagulation treatment, time of stenting, potential for stent thrombosis, restenosis by intimal hyperplasia, type of stent used, and relative contraindications to stent implantation¹⁵. Ultimately, we decided to utilize a balloon expandable graft-stent to occlude the aneurysmal neck and preserve the parent artery. Although the graft-stent was deployed successfully with no procedure-related complications, in our case a significant limitation to the use of the stents intracranially is their large profile and inflexibility, which makes it difficult to negotiate the tortuous vascular segments at the skull base. Also, none of these graft-stents have been specifically designed for intracranial use. Although long-term follow-up and larger samples are required to evaluate efficacy, the usefulness and versatility of placement of a graft-stent in the rapid treatment of pseudoaneurysms of the cranial ICA was demonstrated in this case. In particular, graft-stents have the advantage of parent artery preservation in cases of contralateral ICA occlusion or with an intolerable BTO. Moreover, graft-stents that are designed and developed for intracranial vessels are necessary before their use can be recommended on a broader basis³.

CONCLUSION

We have presented a case successfully treated by application of graft-stent for a pseudoaneurysm of the cavernous ICA to ensure normal patency of the ICA. However, greater experience with the described technique would allow the role and long-term patency of graft-stent placement in the treatment of intracranial pseudoaneurysms to be better defined.

• Acknowledgements

This work was supported by clinical research grant from Pusan National University Hospital 2010.

References

- Ahn JY, Han IB, Kim TG, Yoon PH, Lee YJ, Lee BH, et al. : Endovascular treatment of intracranial vertebral artery dissections with stent placement or stent-assisted coiling. *AJNR Am J Neuroradiol* 27 : 1514-1520, 2006
- Alexander MJ, Smith TP, Tucci DL : Treatment of an iatrogenic petrous carotid artery pseudoaneurysm with a Symbiot covered stent : technical case report. *Neurosurgery* 50 : 658-662, 2002
- Arat A, Turkbey B, Cil BE, Canyigit M, Cekirge S : Emergent treatment of an Iatrogenic arterial injury at femoral puncture site With Symbiot self-expanding PTFE-covered coronary stent-graft. *Australas Radiol* 51 Suppl : B331-B333, 2007
- Bush RL, Lin PH, Dodson TF, Dion JE, Lumsden AB : Endoluminal stent placement and coil embolization for the management of carotid artery pseudoaneurysms. *J Endovasc Ther* 8 : 53-61, 2001
- Celil G, Engin D, Orhan G, Barbaros C, Hakan K, Adil E : Intractable epistaxis related to cavernous carotid artery pseudoaneurysm : treatment of a case with covered stent. *Auris Nasus Larynx* 31 : 275-278, 2004
- Charbel FT, Gonzales-Portillo G, Hoffman W, Cochran E : Distal internal carotid artery pseudoaneurysms : technique and pitfalls of surgical management : two technical case reports. *Neurosurgery* 45 : 643-648; discussion 648-649, 1999
- Chow MW, Chan DT, Boet R, Poon WS, Sung JK, Yu SC : Extrusion of a coil from the internal carotid artery through the middle ear. *Hong Kong Med J* 10 : 215-216, 2004
- Cox MW, Whittaker DR, Martinez C, Fox CJ, Feuerstein IM, Gillespie DL : Traumatic pseudoaneurysms of the head and neck : early endovascular intervention. *J Vasc Surg* 46 : 1227-1233, 2007
- Eckert B, Thie A, Carvajal M, Groden C, Zeumer H : Predicting hemodynamic ischemia by transcranial Doppler monitoring during therapeutic balloon occlusion of the internal carotid artery. *AJNR Am J Neuroradiol* 19 : 577-582, 1998
- Fabian TC, Patton JH Jr, Croce MA, Minard G, Kudsk KA, Pritchard FE : Blunt carotid injury. Importance of early diagnosis and anticoagulant therapy. *Ann Surg* 223 : 513-522; discussion 522-525, 1996
- Fiorella D, Albuquerque FC, Deshmukh VR, Woo HH, Rasmussen PA, Masaryk TJ, et al. : Endovascular reconstruction with the Neuroform stent as monotherapy for the treatment of uncoilable intradural pseudoaneurysms. *Neurosurgery* 59 : 291-300; discussion 291-300, 2006
- Kadyrov NA, Friedman JA, Nichols DA, Cohen-Gadol AA, Link MJ, Piepgras DG : Endovascular treatment of an internal carotid artery pseudoaneurysm following transphenoidal surgery. Case report. *J Neurosurg* 96 : 624-627, 2002
- Leung GK, Auyeung KM, Lui WM, Fan YW : Emergency placement of a self-expandable covered stent for carotid artery injury during transphenoidal surgery. *Br J Neurosurg* 20 : 55-57, 2006
- Li MH, Li YD, Gao BL, Fang C, Luo QY, Cheng YS, et al. : A new covered stent designed for intracranial vasculature : application in the management of pseudoaneurysms of the cranial internal carotid artery. *AJNR Am J Neuroradiol* 28 : 1579-1585, 2007
- Maras D, Lioupi C, Magoufis G, Tsamopoulos N, Moulakakis K, Andrikopoulos V : Covered stent-graft treatment of traumatic internal carotid artery pseudoaneurysms : a review. *Cardiovasc Intervent Radiol* 29 : 958-968, 2006
- Origitano TC, al-Mefty O, Leonetti JP, DeMonte F, Reichman OH : Vascular considerations and complications in cranial base surgery. *Neurosurgery* 35 : 351-362; discussion 362-363, 1994
- Saatci I, Cekirge HS, Ozturk MH, Arat A, Ergungor F, Sekerci Z, et al. : Treatment of internal carotid artery aneurysms with a covered stent : experience in 24 patients with mid-term follow-up results. *AJNR Am J Neuroradiol* 25 : 1742-1749, 2004
- Van Nieuwenhove Y, Van den Brande B, van Tussenbroek F, Debing E, von Kemp K : Iatrogenic carotid artery pseudoaneurysm treated by an autologous vein-covered stent. *Eur J Vasc Endovasc Surg* 16 : 262-265, 1998
- Zhuang Q, Buckman CR, Harrigan MR : Coil extrusion after endovascular treatment. Case illustration. *J Neurosurg* 106 : 512, 2007