

Clinical Article

Endovascular Treatment of Wide-Necked Intracranial Aneurysms : Techniques and Outcomes in 15 Patients

Jin-Wook Kim, M.D., Yong-Seok Park, M.D., Ph.D.

Department of Neurosurgery, Kosin University College of Medicine, Busan, Korea

Objective : It is technically difficult to treat wide-necked intracranial aneurysms by the endovascular method. Various tools and techniques have been introduced to overcome the related technical limitations. The purpose of this study was to evaluate the radiologic and clinical results of wide-necked intracranial aneurysm treatment using the endovascular method.

Methods : Fifteen aneurysms in 15 patients were treated by the endovascular method from October 2009 to August 2010. Seven patients presented with subarachnoid hemorrhage (SAH), seven patients had unruptured aneurysms, and one patient had an intracerebral hemorrhage and intraventricular hemorrhage due to an incompletely clipped aneurysm. The mean dome-to-neck ratio was 1.1 (range, 0.6-1.7) and the mean height-to-neck ratio was 1.1 (range, 0.6-2.0). We used double microcatheters instead of a stent or a balloon for the first trial. When we failed to make a stable coil frame with two coils, we used a stent-assisted technique.

Results : All aneurysms were successfully embolized. Eleven aneurysms (73%) were embolized by the double microcatheter technique without stent insertion, and four aneurysms (27%) were treated by stent-assisted coil embolization. One case had subclinical procedure-related intraoperative hemorrhage. Another case had procedure-related thromboembolism in the left distal anterior cerebral artery. During the follow-up period, one patient (7%) had a recanalized aneurysmal neck 12 months after coil embolization. The recurrent aneurysm was treated by stent-assisted coil embolization.

Conclusion : We successfully treated 15 wide-necked intracranial aneurysms by the endovascular method. More clinical data with longer follow-up periods are needed to establish the use of endovascular treatment for wide-necked aneurysm.

Key Words : Intracranial aneurysm · Embolization · Stent.

INTRODUCTION

Endovascular treatment of intracranial aneurysms is associated with lower morbidity and mortality rates compared with traditional microsurgical clipping¹⁶⁾. However, despite advances in devices and techniques, aneurysms with wide necks, defined by neck diameters greater than 4 mm or dome-to-neck ratios less than 2, are the most difficult to treat with the endovascular method. In wide-necked intracranial aneurysms, complete coil embolization is often technically difficult owing to the risks of distal coil migration or coil impingement on the parent vessel^{4,7,8,10,21)}.

Various tools and techniques have been introduced to overcome these technical limitations including three-dimensional coils^{3,22)}, multiple microcatheter^{1,11,12)}, balloon-remodeling tech-

nique^{14,17)}, and intracranial stents^{6,23,24)}. However, the introduction of additional devices into small intracranial vessels is not only technically demanding, but also may increase the risk of vascular injury and thromboembolism.

We used double microcatheters instead of stents or balloons in the first trial. The key concept upon which this technique is based is the creation of a stable coil frame with two coils through two microcatheters. When we failed to make a stable coil frame with two coils, we used a stent assisted-technique. These two techniques are not new concepts^{1,6,11)}. In this report, we present our experiences with 15 wide-necked intracranial aneurysms.

MATERIALS AND METHODS

Patient sample

Between October 2009 and August 2010, 15 wide-necked intracranial aneurysms were treated using the endovascular method. In this series, wide-necked intracranial aneurysm was defined as a neck diameter greater than 4 mm or a dome-to-neck ratio less than 2. Seven patients presented with a subarachnoid hemorrhage (SAH), seven patients had unruptured aneurysms, and one patient (case 13) had intracerebral hemorrhage and in-

• Received : November 18, 2010 • Revised : January 19, 2011

• Accepted : February 4, 2011

• Address for reprints : Yong-Seok Park, M.D., Ph.D.

Department of Neurosurgery, Kosin University College of Medicine,

34 Amnam-dong, Seo-gu, Busan 602-702, Korea

Tel : +82-51-990-6124, Fax : +82-51-990-3042

E-mail : ysparkns@kosinmed.or.kr

traventricular hemorrhage due to an incompletely clipped aneurysm that was found through follow-up angiography at 4 weeks after clipping. The mean dome-to-neck ratio was 1.1 (range, 0.6-1.7) and the mean height-to-neck ratio was 1.1 (range, 0.6-2.0). Detailed information, including the patient's age and sex, aneurysm location, clinical manifestations (Hunt and Hess grade, Fisher grade), aneurysm morphology (neck, height, width, length), and endovascular treatment strategy, were carefully reviewed. Initial and follow-up angiographic results were also reviewed.

Overall, the clinical follow-up ranged from 2 to 12 months, with a mean of 6 months. Magnetic resonance angiographic (MRA) follow-up was performed at 6 months after operation and transfemoral angiographic (TFCA) follow-up was performed at 12 months after operation. TFCA was also performed before discharge. Clinical modified Rankin Scale (mRS) scores were recorded at 24 hours, 2 weeks, 6 months, and 12 months (or at the last follow-up) after the operation. The angiographic results were classified according to the Raymond-Roy classification system^{18,20} as follows: Class 1, no filling of the aneurysm neck or dome; Class 2, residual filling of the neck, but not the dome; and Class 3, residual filling of the neck and dome.

Techniques

All operations were performed under general anesthesia. All patients except those with SAH were pretreated with clopidogrel and aspirin. A 3,000 IU heparin bolus was administered after guiding catheter placement in the case of the unruptured

aneurysms and after deployment of the first or second coil in the case of the ruptured aneurysm. Intermittent boluses of 1,000 IU/hour of heparin were then administered.

With diagnostic angiography and 3D angiographic reconstruction, the morphologic characteristics of the aneurysm were carefully evaluated, including the size of the neck, height, width and length; the diameter and tortuosity of the parent artery; and major branches originating from the aneurysmal neck. The detailed strategies for the coil embolization technique depended on the angiographic findings. On the basis of the above considerations, detailed points were decided, including working angle of fluoroscopy, shape of microcatheter tip, first coil loop size, stent size, total coil volume needed and expected packing density.

At first, we tried to apply a double microcatheter technique, so we placed two microcatheters in the aneurysmal sac. When the height of the aneurysm was less than 3 mm, we placed two microcatheters at the aneurysmal neck to prevent perforation of the aneurysmal sac. The directions of the two coils were different to achieve an initial full covering coil frame for the aneurysm. Therefore, the two microcatheter tips used were of different shapes. The first coil loop size should be smaller than the height of aneurysm. The second coil loop size should be smaller than the first coil loop size. Technically, a stable coil frame should be achieved with the initial two coils. The coils used in this series included various types of Guglielmi detachable coils (Boston Scientific, Natick, MA, USA; 3D, standard helical, ultrasoft), Microplex coils (MicroVention, Aliso Viejo, CA, USA). When we failed to make a stable coil frame with two coils, we used a stent-assisted

technique. After bilateral femoral arteries were punctured, another guiding catheter was placed at a site proximal to the parent artery. Initially, two microcatheters were placed at the aneurysmal sac, and then a stent was deployed to prevent coil protrusion into the parent artery. After jailing the two microcatheters, we started coil embolization with the two microcatheters. We used Neuroform stents (Boston Scientific, Natick, MA). The technical details of the double microcatheter technique and stent-assisted technique are shown in Fig. 1-3.

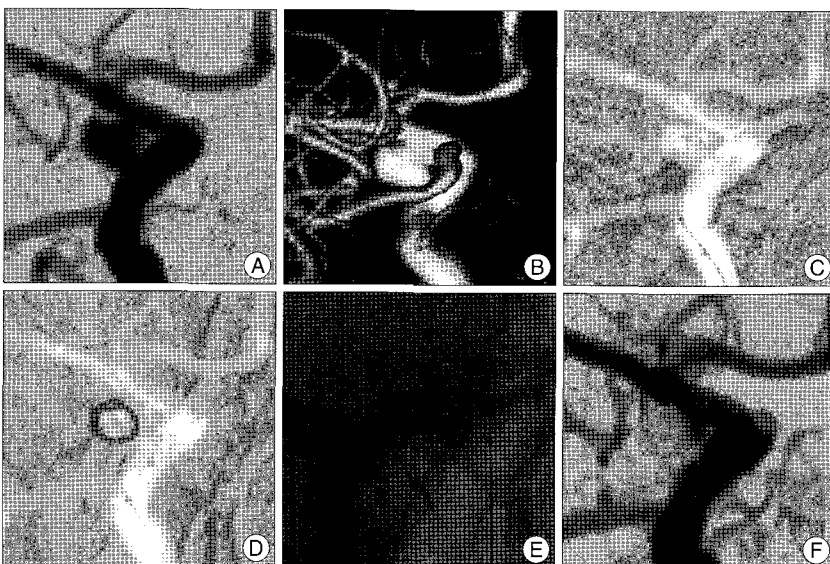


Fig. 1. Case 5; a 54-year-old man with subarachnoid hemorrhage (SAH). A : The left internal carotid artery (ICA) angiogram shows the aneurysm before treatment. B : 3D reconstruction image shows a wide-necked posterior communicating artery (PCoA) aneurysm (neck×height×width×length : 4.6×4.3×5.3×6.8 mm). C : Two microcatheters are positioned within the aneurysm. One has a 90° angled distal tip and the other has a J-shaped distal tip. D : First coil (360° Guglielmi detachable coil 4×8 mm) being deployed. E : Second coil (360° Guglielmi detachable coil 3×6 mm) being deployed via another microcatheter. F : Immediately after treatment, a right ICA angiography shows no contrast dye filling of the aneurysm neck or dome, but the patient died of severe vasospasm on the 10th day after coil embolization.

RESULTS

Angiographic results

All aneurysms were successfully embolized. Eleven aneurysms (73%) were embolized by the double microcatheter technique without stent insertion and four aneurysms (27%) were treated by stent-assisted coil embolization. Immediate postembolization angiography

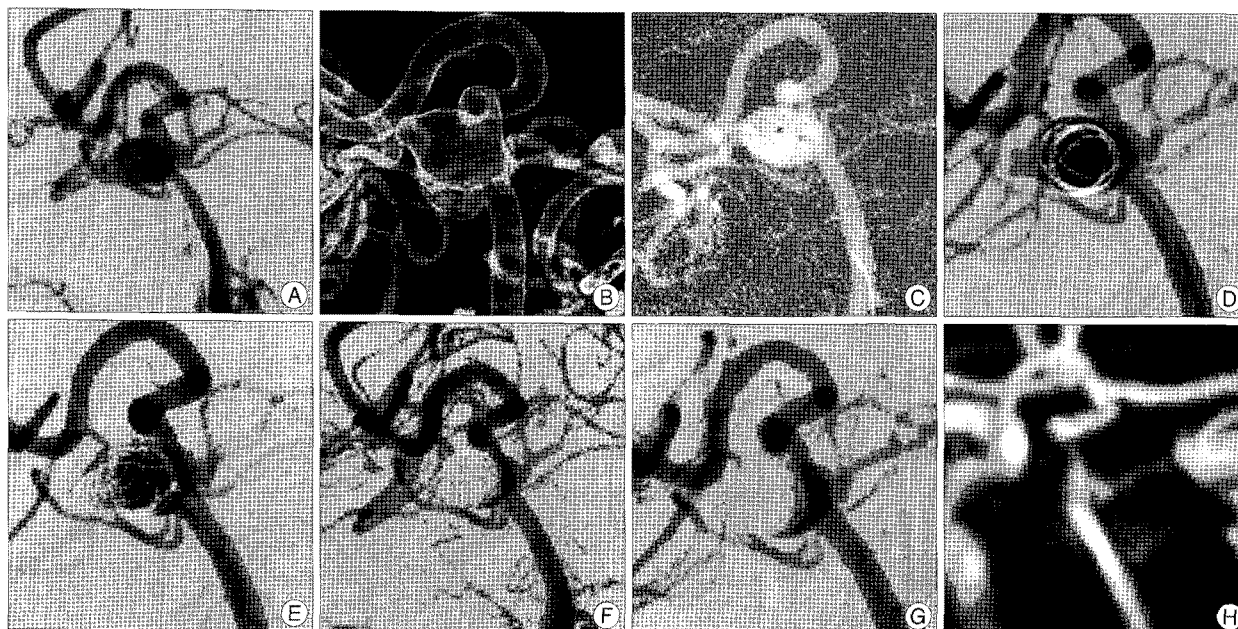


Fig. 2. Case 9; a 63-year-old woman with SAH. A : The left vertebral artery angiogram shows the aneurysm before treatment. B : 3D reconstruction image shows wide-necked right superior cerebellar artery aneurysm (neck \times height \times width \times length : 5.0 \times 7.1 \times 5.3 \times 6.2 mm). C : Two microcatheters are positioned within the aneurysm. One has a 45° angled distal tip and the other has a 90° angled distal tip. D : First coil (360° Guglielmi detachable coil 7 \times 15 mm) being deployed. E : Second coil (Microplex coil Complex 5 \times 15 mm) being deployed via another microcatheter. F : Immediately after embolization, angiogram shows compact occlusion of the aneurysmal sac and patent right SCA. There is a small remnant neck around the right SCA. G : Two months after embolization, an angiogram shows no interval change and stable coils. H : Six months after embolization, magnetic resonance angiogram shows no interval change and stable coils.

showed four cases (27%) of Class 2 (Table 1).

We performed follow-up angiography in all patients at 12 months after operation. One patient (7%) had a recanalized aneurysmal neck (Class 2) 12 months after coil embolization. This recurrent aneurysm was treated by stent-assisted coil embolization.

Complications

There were two cases (13%) of procedure-related complications in our patients. In one case, there was subclinical procedure-related intraoperative bleeding (Case 1). In another case, there was procedure-related thromboembolism at the left distal anterior cerebral artery (Case 14). Except for these two cases, there were no evidence of other procedure-related complications such as coil protrusion, coil migration and spasm during the procedure.

DISCUSSION

Despite advances in devices and techniques, some intracranial aneurysms remain difficult to treat with coils. Wide-necked

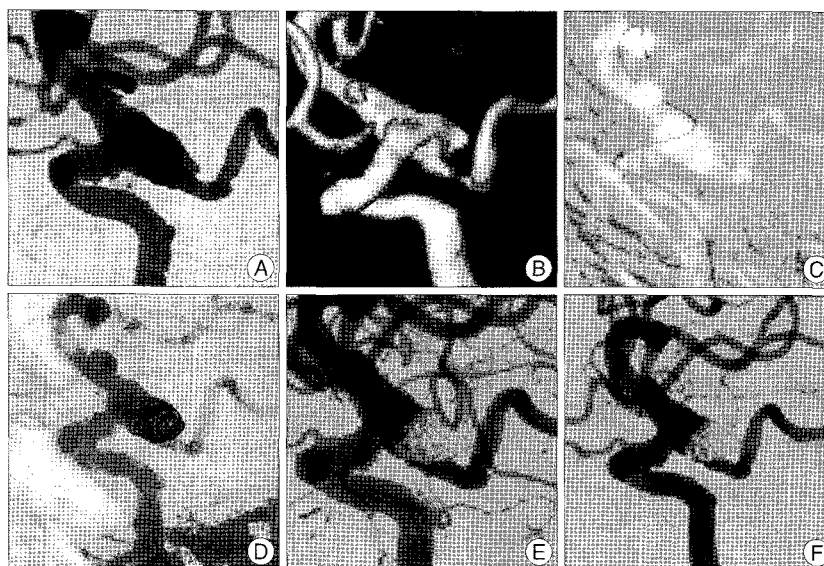


Fig. 3. Case 14; a 73-year-old woman with SAH. A : The left ICA angiogram shows the aneurysm before treatment. B : 3D reconstruction image shows wide-necked PCoA aneurysm (neck \times height \times width \times length : 10.6 \times 6.5 \times 7.2 \times 7.3 mm). C : Neuroform stent (4.5 \times 15 mm) was deployed resulting in jailing two microcatheters. The microcatheters have different distal shapes; one has a 45° angled distal tip and the other has a 90° angled distal tip. D : Two coils (360° Guglielmi detachable coil 6 \times 11 mm, Microplex coil Complex 5 \times 15 mm) being deployed via two microcatheters. E : Immediately after treatment, a left ICA angiography shows residual contrast dye filling the neck to preserve the fetal type PCoA. The dome of the aneurysm is compactly occluded. But, there was a procedure-related thromboembolism at the left distal anterior cerebral artery. F : Two months after embolization, the angiogram showed no interval change and stable coils.

intracranial aneurysms represent one of the most unfavorable aneurysm configurations. Various devices and techniques have

Table 1. Summary of the 15 patients with 15 aneurysms

Case	Age	Sex	Location	Neck (mm)	Height (mm)	Width (mm)	Length (mm)	Technique	Angiographic results		F/U period (months)	mRS last
									Initial	F/U		
1*	39	F	PCoA	4.2	4.5	5.3	7.2	Stent assisted	Class II	Class II	12	0
2*	49	F	PCoA	3.1	4.5	4.6	5.2	Double MC	Class I	Class II	12	0
3*	50	M	ACoA	2.7	3.4	3.3	3.4	Double MC	Class I	Class I	12	0
4	81	M	ACoA	3.7	7.4	6.4	6.6	Double MC	Class I	Class I	9	0
5*	54	M	PCoA	4.6	4.3	5.3	6.8	Double MC	Class I			6
6*	42	F	MCAb	2.7	4.5	2.8	4.6	Double MC	Class I	Class I	9	0
7	61	F	BA top	3.2	2.5	3.1	3.2	Double MC	Class I	Class I	8	4
8	71	F	SCA	5.9	6.2	8.3	8.5	Double MC	Class I	Class I	6	0
9*	63	F	SCA	5.0	7.1	5.3	6.2	Double MC	Class II	Class II	5	0
10	49	F	SHyA	2.5	2.1	2.5	3.0	Double MC	Class I	Class I	4	0
11	60	F	SHyA	2.4	3.5	3.5	3.9	Double MC	Class I	Class I	3	0
12	44	M	SHyA	4.2	2.7	3.1	4.5	Stent assisted	Class II	Class II	2	0
13*†	71	F	ACoA	2.0	1.7	2.1	2.5	Double MC	Class I	Class I	2	4
14*	73	F	PCoA	10.6	6.5	7.2	7.3	Stent assisted	Class II	Class II	2	4
15	76	F	BA top	2.7	2.1	1.7	2.5	Y stent assisted	Class I	Class I	2	0

Class 1 : no filling of the aneurysm neck or dome, Class 2 : residual filling of the neck but not the dome. * Ruptured aneurysm, †Rebleeding due to incompletely clipped aneurysm, Width : the short axis dome measurement in cylindrical aneurysms, Length : the long axis dome measurement in cylindrical aneurysms, The dome/neck ratio is based on the width/neck ratio. One patient (case 5) died of severe vasospasm. Two patients (cases 7, 13) were unable to walk due to preexisting disease without any procedure-related complications. Case 7 had old cerebral infarction. Case 13 had old cerebral hemorrhage. We evaluated the follow-up angiographic results of the cases in which the follow-up period was less than 6 months on the basis of MR or transfemoral angiographic results. F/U : follow-up, mRS : modified Rankin Scale, PCoA : posterior communicating artery, ACoA : anterior communicating artery, MCAb : middle cerebral artery bifurcation, BA : basilar artery, SCA : superior cerebellar artery, SHyA : superior hypophyseal artery, MC : microcatheter

been introduced to overcome the technical limitations associated with treating wide-necked intracranial aneurysms, including three-dimensional coils³), multiple microcatheter^{1,11,12}), balloon remodeling technique¹⁷), intracranial stents⁶), flow diverter devices¹⁵) and neck-bridge device^{5,19}).

We aimed to identify the best choice for treatment of wide-necked intracranial aneurysms. First, we tried to apply the double microcatheter technique by placing two microcatheters at the aneurysmal sac. If we failed to make a stable coil frame with the two coils, we used a stent-assisted technique.

We did not use the balloon remodeling technique. There is a risk of vascular stretching and intimal injury during balloon manipulation. Rupture of the aneurysm is another potential complication because higher intraaneurysmal forces can be generated when the aneurysm neck is occluded with a balloon. Once detached, the coils can also shift their position and herniate into the parent vessel. This shifting occurs most commonly when coils are added to an already detached coil^{14,17}). We did not use flow diverter devices or a neck-bridge device, as they are not available yet in our country.

The technique of using two microcatheters has several advantages over the stent- or balloon-assisted techniques. No additional femoral puncture is required and the risks directly associated with bulky devices are low. The most important aspect of this technique is the achievement of coil stability with the initial two coils without compromising the parent artery or major branches. When we failed to make a stable coil frame, we selected an adjuvant method among the several available devices

and techniques.

We could use three or more microcatheters to achieve coil stability, but there are several potential complications associated with multiple microcatheters including thromboembolism, coil stretching, coil breakage or coil interlocking during the coil manipulation¹²). Multiple microcatheter techniques take more time to achieve an initial full covering coil frame for the aneurysm in comparison to the double microcatheter technique, because they are more likely to require careful manipulation of coils and they are more prone to procedure-related complications. If we had a chance to use an adjuvant stent while struggling with the triple microcatheters, we might have to deal with the issue of the triple microcatheters preventing us from crossing the stent system over the aneurysm. Therefore, we did not use three or more microcatheters.

Adjuvant stenting was proposed in the mid 1990's, initially for fusiform aneurysms⁹), and more recently to support the neck region of intracranial saccular aneurysms and to prevent recurrence^{6,23,24}). An intracranial stent prevents coil migration or protrusion, enables dense packing in aneurysms, induces significant intra-aneurysmal flow modification, and provides a framework for endothelial growth resulting in permanent separation of the aneurysm from the parent vessel. The use of an intracranial stent is attractive to surgeons in terms of complete obliteration of wide-necked aneurysms, but they require the use of long-term antiplatelet agents to prevent thromboembolism. In-stent stenosis is another problem^{13,23,24}) and vascular dissection may occur during stent manipulation. Stent malposi-

tion also may occur²⁾. These issues make surgeons hesitant to use an intracranial stent¹³⁾.

We tried our best not to deploy intracranial stents. In all, four cases (27%) were treated by stent-assisted technique. In terms of recanalization, the use of an adjuvant stent may have some advantages, but the double catheter method without stent offers long-term durability. In our series, we have different angiographic results based on one-year follow-up angiograms of two cases in which we did not use adjuvant stents. Case 2 showed recanalization of the aneurysm, but case 3 revealed no interval change. More clinical data with longer follow-up periods are needed to evaluate whether an adjuvant stent can be used for long-term durability.

In our opinion, the double microcatheter technique is the best option for treatment of wide-necked intracranial aneurysms, whereas the stent-assisted technique is the final option for wide-necked intracranial aneurysm. This report has some limitations. The clinical and angiographic follow-up periods were short and the number of cases included was small. Therefore, further follow-up and more clinical data are necessary to determine further the role of endovascular treatment of wide-necked intracranial aneurysm.

CONCLUSION

We successfully treated 15 wide-necked intracranial aneurysms with the endovascular method. More clinical data with longer follow-up period are needed to establish the role of endovascular treatment of wide-necked intracranial aneurysms.

References

- Baxter BW, Rosso D, Lownie SP : Double microcatheter technique for detachable coil treatment of large, wide-necked intracranial aneurysms. *AJNR Am J Neuroradiol* 19 : 1176-1178, 1998
- Broadbent LP, Moran CJ, Cross DT 3rd, Derdeyn CP : Management of neuroform stent dislodgement and misplacement. *AJNR Am J Neuroradiol* 24 : 1819-1822, 2003
- Cloft HJ, Joseph GJ, Tong FC, Goldstein JH, Dion JE : Use of three-dimensional Guglielmi detachable coils in the treatment of wide-necked cerebral aneurysms. *AJNR Am J Neuroradiol* 21 : 1312-1314, 2000
- Debrun GM, Aletich VA, Kehrli P, Misra M, Ausman JI, Charbel F : Selection of cerebral aneurysms for treatment using Guglielmi detachable coils: the preliminary University of Illinois at Chicago experience. *Neurosurgery* 43 : 1281-1295; discussion 1296-1297, 1998
- De Keuleleire K, Vanlangenhove P, Defreyne L : Evaluation of a neck-bridge device to assist endovascular treatment of wide-neck aneurysms of the anterior circulation. *AJNR Am J Neuroradiol* 29 : 73-78, 2008
- de Paula Lucas C, Piotin M, Spelle L, Moret J : Stent-jack technique in stent-assisted coiling of wide-neck aneurysms. *Neurosurgery* 62 : ONS414-ONS416; discussion ONS416-ONS417, 2008
- Fernandez Zubillaga A, Guglielmi G, Viñuela F, Duckwiler GR : Endovascular occlusion of intracranial aneurysms with electrically detachable coils : correlation of aneurysm neck size and treatment results. *AJNR Am J Neuroradiol* 15 : 815-820, 1994
- Gonzalez N, Sedrak M, Martin N, Vinuela F : Impact of anatomic features in the endovascular embolization of 181 anterior communicating artery aneurysms. *Stroke* 39 : 2776-2782, 2008
- Higashida RT, Smith W, Gress D, Urwin R, Dowd CE, Balousek PA, et al. : Intravascular stent and endovascular coil placement for a ruptured fusiform aneurysm of the basilar artery : case report and review of the literature. *J Neurosurg* 87 : 944-949, 1997
- Hope JK, Byrne JV, Molyneux AJ : Factors influencing successful angiographic occlusion of aneurysms treated by coil embolization. *AJNR Am J Neuroradiol* 20 : 391-399, 1999
- Kwon OK, Kim SH, Kwon BJ, Kang HS, Kim JH, Oh CW, et al. : Endovascular treatment of wide-necked aneurysms by using two microcatheters: techniques and outcomes in 25 patients. *AJNR Am J Neuroradiol* 26 : 894-900, 2005
- Kwon OK, Kim SH, Oh CW, Han MH, Kang HS, Kwon BJ, et al. : Embolization of wide-necked aneurysms with using three or more microcatheters. *Acta Neurochir (Wien)* 148 : 1139-1145; discussion 1145, 2006
- Lanzino G, Wakhloo AK, Fessler RD, Hartney ML, Guterman LR, Hopkins LN : Efficacy and current limitations of intravascular stents for intracranial internal carotid, vertebral, and basilar artery aneurysms. *J Neurosurg* 91 : 538-546, 1999
- Levy DI, Ku A : Balloon-assisted coil placement in wide-necked aneurysms. Technical note. *J Neurosurg* 86 : 724-727, 1997
- Lubicz B, Collignon L, Raphaeli G, Pruvo JP, Bruneau M, De Witte O, et al. : Flow-diverter stent for the endovascular treatment of intracranial aneurysms: a prospective study in 29 patients with 34 aneurysms. *Stroke* 41 : 2247-2253, 2010
- Molyneux A, Kerr R, Stratton I, Sandercock P, Clarke M, Shrimpton J, et al. : International Subarachnoid Aneurysm Trial (ISAT) of neurosurgical clipping versus endovascular coiling in 2143 patients with ruptured intracranial aneurysms : a randomised trial. *Lancet* 360 : 1267-1274, 2002
- Moret J, Cognard C, Weill A, Castaing L, Rey A : The "Remodelling Technique" in the treatment of wide neck intracranial aneurysms. Angiographic results and clinical follow-up in 56 cases. *Interv Neuroradiol* 3 : 21-35, 1997
- Raymond J, Roy D, Leblanc P, Roorda S, Janicki C, Normandeau L, et al. : Endovascular treatment of intracranial aneurysms with radioactive coils : initial clinical experience. *Stroke* 34 : 2801-2806, 2003
- Raymond J, Guilbert F, Roy D : Neck-bridge device for endovascular treatment of wide-neck bifurcation aneurysms : initial experience. *Radiology* 221 : 318-326, 2001
- Raymond J, Guilbert F, Weill A, Georganos SA, Juravsky L, Lambert A, et al. : Long-term angiographic recurrences after selective endovascular treatment of aneurysms with detachable coils. *Stroke* 34 : 1398-1403, 2003
- Turjman F, Massoud TF, Sayre J, Viñuela F : Predictors of aneurysmal occlusion in the period immediately after endovascular treatment with detachable coils : a multivariate analysis. *AJNR Am J Neuroradiol* 19 : 1645-1651, 1998
- Vallée JN, Pierot L, Bonafé A, Turjman F, Flandroy P, Berge J, et al. : Endovascular treatment of intracranial wide-necked aneurysms using three-dimensional coils : predictors of immediate anatomic and clinical results. *AJNR Am J Neuroradiol* 25 : 298-306, 2004
- Wakhloo AK, Lanzino G, Lieber BB, Hopkins LN : Stents for intracranial aneurysms : the beginning of a new endovascular era? *Neurosurgery* 43 : 377-379, 1998
- Yun JH, Cho CS : Experiences of neuroform stent applications for ruptured anterior communicating artery aneurysms with small parent vessel. *J Korean Neurosurg Soc* 48 : 53-58, 2010