

## Clinical Article

# C7 Posterior Fixation Using Intralaminar Screws : Early Clinical and Radiographic Outcome

Sang Hoon Jang, M.D.,<sup>1</sup> Jae Taek Hong, M.D., Ph.D.,<sup>1</sup> Il Sup Kim, M.D.,<sup>1</sup> In Sung Yeo, M.D.,<sup>2</sup> Byung Chul Son, M.D.,<sup>1</sup> Sang Won Lee, M.D.<sup>1</sup>

Department of Neurosurgery,<sup>1</sup> St. Vincent's Hospital, The Catholic University of Korea, Suwon, Korea

Department of Neurosurgery,<sup>2</sup> Daejeon St. Mary's Hospital, The Catholic University of Korea, Daejeon, Korea

**Objective :** The use of segmental instrumentation technique using pedicle screw has been increasingly popular in recent years owing to its biomechanical stability. Recently, intralaminar screws have been used as a potentially safer alternative to traditional fusion constructs involving fixation of C2 and the cervicothoracic junction including C7. However, to date, there have been few clinical series of C7 laminar screw fixation in the literature. Thus, the purpose of this study is to report our clinical experiences using C7 laminar screw and the early clinical outcome of this rather new fixation technique.

**Methods :** Thirteen patients underwent C7 intralaminar fixation to treat lesions from trauma or degenerative disease. Seventeen intralaminar screws were placed at C7. The patients were assessed both clinically and radiographically with postoperative computed tomographic scans.

**Results :** There was no violation of the screw into the spinal canal during the procedure and no neurological worsening or vascular injury from screw placement. The mean clinical and radiographic follow up was about 19 months, at which time there were no cases of screw pull-out, screw fracture or non-union. Complications included two cases of dorsal breach of intralaminar screw and one case of postoperative infection.

**Conclusion :** Intralaminar screws can be potentially safe alternative technique for C7 fixation. Even though this technique cannot be used in the cases of C7 laminar fracture, large margin of safety and the ease of screw placement create a niche for this technique in the armamentarium of spine surgeons.

**KEY WORDS :** Cervical spine · Posterior screw fixation · Intralaminar screw · C7.

## INTRODUCTION

Techniques for cervical posterior fixation have advanced greatly over the past two decades. Primary bone graft inlay without fixation was replaced by wiring techniques to reduce motion and to maintain solid graft interfaces<sup>(6,14)</sup>. In the modern era, a number of rigid internal screw fixation techniques have been developed, greatly improving our ability to stabilize the vertebral column<sup>(17,18)</sup>.

Many techniques have been described for posterior cervical instrumentation<sup>(1,8,13,26)</sup>. Although lateral mass screws are relatively safe and easy constructs to insert, they can sometimes cause failure due to screw loosening or avulsion, particularly

at the level of C7 where the thin nature of the lateral mass results in decreased pullout strength<sup>(3)</sup>.

Screw fixation into the cervical pedicle has been proposed as an alternative to overcome these limitations<sup>(2,10)</sup>. Pedicle screw fixation is known to be most biomechanically stable when performed through a posterior-only approach<sup>(12)</sup>. However, its use in the cervical spine region can be technically difficult and potentially dangerous, as the cervical pedicle is small and is closely surrounded by delicate structures : laterally by the vertebral artery, medially by the spinal cord, and vertically by adjacent nerve roots<sup>(24)</sup>.

Recently, intralaminar screws have been used as a potentially safer alternative to traditional fusion constructs involving fixation of C2 and the cervicothoracic junction including C7<sup>(8,21)</sup>. The intralaminar screw method is useful for avoiding vascular injuries, especially when there is a high riding vertebral artery (VA) around C2 or the VA traverses through the C7 transverse foramen. This technique has two key advantages to currently used surgical options : first, it is simpler and

• Received : February 17, 2010 • Revised : July 12, 2010

• Accepted : August 3, 2010

• Address for reprints : Jae Taek Hong, M.D., Ph.D.

Department of Neurosurgery, St. Vincent's Hospital, The Catholic University of Korea, 423 Ji-dong, Paldal-gu, Suwon 442-723, Korea  
Tel : +82-31-249-7196, Fax : +82-31-249-5208

E-mail : jatagi15@paran.com

does not require the use of any navigational instruments, and second, it is not limited by the position of known vascular structures<sup>21</sup>). Therefore, the potential patient population that could benefit from this procedure is large. However, to date, only a few clinical series have been reported on this technique. Thus, the purpose of this study is to describe the results of our clinical experiences using the C7 intralaminar screw technique.

## MATERIALS AND METHODS

### Patient demographics and surgical indications

Thirteen patients who presented to our institution between June 2005 and August 2009 with spinal disorders necessitating C7 intralaminar screw fixation were included in this study. Patient age, sex, cause, specific procedure, follow up duration are presented in Table 1. The average age of patients was 51.8 years (range, 23-71 yr), and male : female ratio was 12 : 1. Preoperative computed tomography (CT) scan was performed to confirm a capacious C7 lamina. Indications for surgery included traumatic instability in eleven patients and posterior augmented fusion for pseudoarthrosis in two patients. A total seventeen screws were placed in C7 lamina.

### Surgical technique

The technique for C7 screw placement was described by Hong<sup>8,9</sup>). Length of intralaminar screw was assessed on axial CT imaging preoperatively and it was measured from a defined entry point in the spinolaminar junction to the junction between lamina and lateral mass. After dorsal exposure of the spinous process and lamina, a determination was made

as to the slope angle of the lamina. A high-speed drill was used to open a small starter hole at the spinolaminar junction. The entry points for the intralaminar screws were staggered at the base of the spinous processes so that the two screws did not collide or violate the laminal cortex. With a hand drill, the contralateral side lamina was drilled to a preoperatively estimated depth (20-30 mm,) along the trajectory for the screw to be inserted from the target side. The screw trajectory is different from another C7 screw trajectories (Fig. 1) and was created along the thickest part of the lamina. Usual trajectory of C7 intralaminar screw was at the junction between the middle and inferior third of the lamina at C7. Although the angle of C7 intralaminar screw trajectory is stiffer than that of C7 pedicle screw, posterior neck muscle usually does not cause any trouble to insert intralaminar screw, because the entry point of intralaminar screw is more medially located compared to that of pedicle or lateral mass screw.

The length of the hole was then palpated with a probe to ensure that cortical bone had not violated the spinal canal space and tapped with a 3.0 mm tap. Either Summit (Depuy Spine, Raynham, MA, USA) or Vertex (Medtronic Sofamor Danek, Memphis, TN, USA) 3.5 mm diameter titanium polyaxial screws were then carefully placed along the trajectory of the hole.

Screws were inserted manually without radiographic monitoring. The polyaxial heads were left exposed to allow movement. Pure titanium rods were then measured and cut so that they spanned the heads of the following adjacent pairs of screws. A specialized lateral connector was used when it was difficult to connect the rod directly to the screw head. The set screws were tightened to a specific torque.

**Table 1.** Demographic of patients undergoing C-7 intra laminar screw fixation

Case No.	Age	Sex	F/U (month)	Diagnosis	Level of laminar screw	Fusion Level	Complication	VAS (preop)	VAS (preop)
1	23	M	38	C6-7 Fx dislocation	Rt C7, Rt T1	C6-T1		8	2
2	51	M	45	C6-7 subluxation	Both C7	C5-C7	Dorsal breach	8	1
3	49	M	44	Pseudoarthrosis	Lt C7	C5-C7		7	2
4	27	F	48	C6-7 instability	Lt C7	C6-C7		7	1
5	42	M	10	C6-7-T1 subluxation	Rt C7, Rt T1	C6-T1		9	3
6	68	M	10	Multiple facet Fx, OPLL, cord contusion	Lt C7	C3-C7	Dorsal breach	8	2
7	66	M	6	C6-7 subluxation	Lt C7	C5-C7		7	2
8	62	M	8	C5-6 dislocation	Both C7	C5-C7		8	1
9	59	M	9	Pseudoarthrosis	Rt C7	C5-C7		7	2
10	39	M	6	C5 bursting Fx, C3-5 facet Fx	Both C7	C3-C7		9	2
11	71	M	8	C7T1 subluxation	Lt C7	C6-T1	Wound infection	7	1
12	52	M	7	C6-7 Subluxation	Lt C7	C6-T1		6	2
13	64	M	6	C5-6 Subluxation	Both C7	C5-C7		6	1
Mean	51.8		18.8					7.5	1.7

F/U : follow-up duration, Fx : fracture, Lt : left, OPLL : ossified posterior longitudinal ligament, Rt : right, VAS : Visual Analogue Pain Scale

## RESULTS

### Intraoperative findings

There was no intraoperative complication during the procedure. There was no excessive bleeding and no cases of cerebrospinal fluid leakage related to hardware placement. In two cases, there were dorsal breaches of the C7 lamina during the screw placement. However, there was no hardware failure or non-union during the follow-up.

Lateral connector was very helpful to connect the rod to C7 intralaminar screw and there was no adverse effect of lateral connector for the strength of the construct.

### Clinical and radiographic outcomes

The follow-up duration averaged 18.8 months (range, 6-48 months). Postoperative CT scans were obtained for all patients. Seventeen C7 intralaminar screws were used. In two instances, a T1 intralaminar screw was used together with a C7 intralaminar screw. Bilateral crossing laminar screws were inserted in four cases (Fig. 2) and a unilateral laminar screw was implanted in the remaining nine cases (Fig. 3).

Two screws demonstrated some dorsal breach of the C7 lamina. However, violation of the dorsal lamina was limited to some exposure of the screw threads without causing any clinical outcome. The rest of the intralaminar screws were successfully placed within the laminae. There were no cases of spinal canal violation by the screw or vascular injuries from hardware placement.

All patients underwent iliac bone harvesting except one patient whose bilateral iliac bone had been used for a previous lumbar fusion. Allograft iliac bone was used for the exceptional case. Every patient was treated with a cervical collar postoperatively for 3 months. One case of postoperative infection was successfully managed by closed irrigation without any clinical consequence. All patients in this cohort were regularly followed for 6 months. A more extended follow-up was conducted, but several patients did not appear after their appointments at 18-month period. Thus, the overall mean follow-up duration for all patients was 18.8 months, and successful posterolateral bone fusion and stability was noted in all of 13 patients which was estimated using follow up CT scan and dynamic X-ray. Perioperative visual analogue scale (VAS) score for the neck pain (mean preoperative VAS score = 7.5, mean postoperative VAS score = 1.7) show marked improvement of VAS score after surgery.

## DISCUSSION

Pedicle screws are the most biomechanically stable screws<sup>3,16</sup>. However, their use in cervical spine carries a high risk of

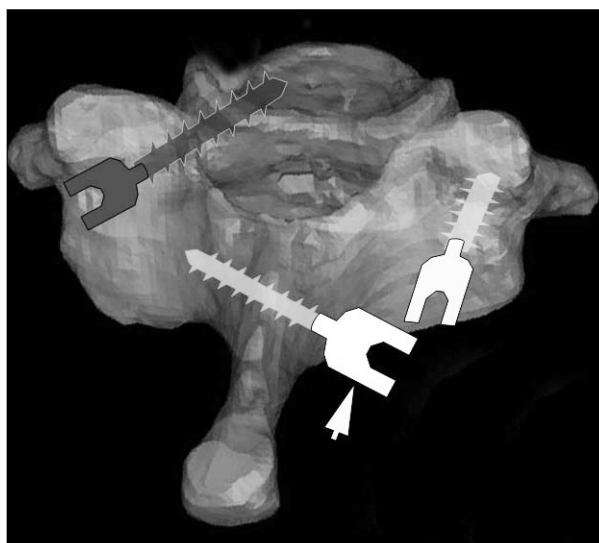


Fig. 1. Illustration shows the C7 specimen and three different C7 fixation methods. Lateral mass screws (white), pedicle screw (black) and intralaminar screws (white, arrow) are inserted.

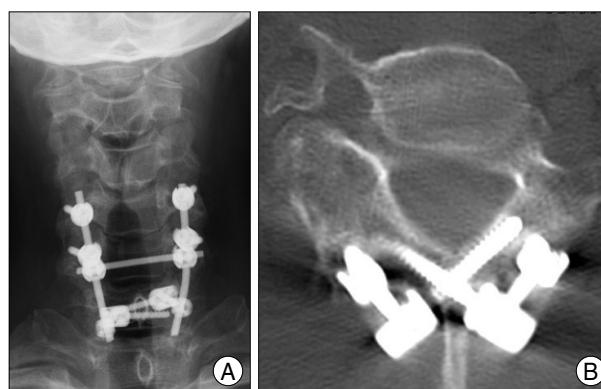


Fig. 2. Postoperative image of C7 fixation using bilateral crossing intralaminar screw. A : Postoperative radiograph shows bilateral C5-6 lateral mass screws that are connected to C7 intralaminar screw with rod construct. B : Postoperative computed tomography scan demonstrates bilateral crossing intralaminar screw connected to lateral connector at C7 lamina.

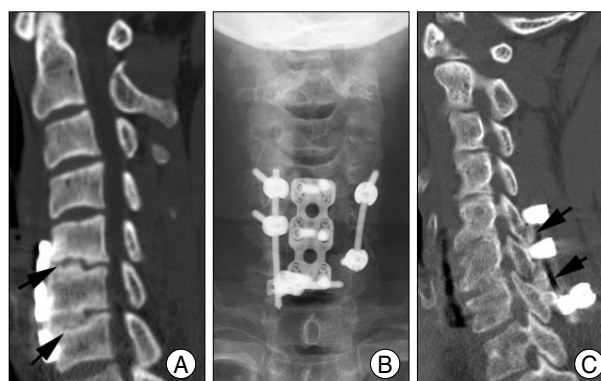


Fig. 3. Case of C7 fixation using unilateral intralaminar screw. A : Preoperative imaging study shows pseudoarthrosis (arrows) after anterior cervical fusion. B : Postoperative X-ray shows unilateral C7 intralaminar screw on the right side and contralateral pedicle screw. C : Sagittal CT image shows the bone fusion which is successful around the lateral mass (arrows).

neurovascular complications<sup>19,23,25</sup>). This occurs because the cervical pedicle is small and surrounded by critical neurovascular structures. Although C7 pedicle is larger than that of other subaxial cervical spine, VA location at C7 is rather variable and the VA may enter the C7 transverse foramen up to 5.4% of cases<sup>2,4,7</sup>. In addition, complicated biomechanical forces are present at this transition between the flexible cervical and rigid thoracic spines. Lateral mass screws, while easier and safer to insert, cannot always be placed into C7 and are known to exhibit lower pullout strengths<sup>11</sup>. Recently, authors described a novel technique of laminar screw fixation of the subaxial cervical spine<sup>9</sup>.

One major advantage of this technique is to eliminate the risk of injury to neurovascular structures by screw placement as the translaminar screws remain in the posterior element<sup>9</sup>. When the VA courses into the C7 transverse foramen (TF), insertion of a C7 pedicle screw carries the risk of injuring either the adjacent VA or spinal cord. The use of laminar screws allows for immobilization of the C7 without risk to the VA in these cases. Another important advantage of laminar screw fixation is that the use of a fluoroscope or navigation system is not longer necessary, because the screw can be placed under direct vision of outer cortex of the lamina and all relevant structures<sup>20</sup>. Also, tactile feedback can help not to violate spinal canal. Recently, some biomechanical studies suggested that using lamina screws as salvage technique at C7 provides similar fixation strength as the index pedicle screw<sup>5</sup>. Therefore, if the pedicle screw fails, intralaminar screws seem to be a biomechanically sound salvage technique.

In spite of this, there are three major concerns about the C7 laminar screw. First one is the risk of damage to the ventral spinal cord. If this is a concern, a slightly more dorsal trajectory can be used to avoid ventral penetration into the spinal canal. In this case, even if penetration of the dorsal cortex occurs, we have not experienced any associated unwanted clinical consequences. Using gear-shift technique, surgeon can avoid the ventral cortical breach and violation into the spinal canal. Moreover, the dorsal laminar surface serves as a guide for the screw trajectory for C7 intralaminar screw placement. However, most important step to prevent ventral cortical breach is not to make an entry point anterior to the spinolaminar junction. A second cause of concern is that the anatomy of the C-7 posterior elements may prohibit successful placement of 3.5 or 4 mm diameter screw. Anatomical studies showed that the C7 laminae of women are smaller than those of men and some C7 laminae are not thick enough to afford C7 laminar screw fixation<sup>15,22</sup>. And, C7 intralaminar screw cannot be used in cases with laminar fracture. Therefore, preoperative radiographic evaluation is necessary to choose optimal fixation technique. Third, and lesser, cause of

concern is the lack of a report in the literature on clinical and radiological outcome of C7 intralaminar screws fixation to prove the long term stability and fusion rate. Thus, the objective of this study was to investigate the posterior cervical construct stability afforded by this novel C7 intralaminar screw technique in terms of clinical and radiographic outcome.

In this clinical series, intralaminar screw was used as the primary C7 fixation option for the case of abnormal V2 segment or small C7 pedicle and chose as salvage fixation technique when pedicle screw was failed and head alignment of C6 lateral mass screw and C7 pedicle screw was difficult due to their proximity. In reviewing our patients treated with C7 intralaminar screws, it is clear that technical placement is feasible with good long-term results in patients from diverse spectrum of age disease origin, presenting symptom, and construct length.

In our series of 13 patients who were followed for longer than 18 months, three patients showed complications; one was postoperative wound infection and the others were dorsal breach of C7 intralaminar screw without any clinical problem.

Biomechanical study showed that mean pullout forces of intralaminar screw were similar to that of the index pedicle screws. However, mean lamina screw peak insertion torque (IT) was significantly lower than mean index pedicle screw peak IT<sup>5</sup>. These results suggest that pedicle screws provide the strongest fixation in C7. But, in the cases where pedicle screw is not favorable or when pedicle screw should fail, the use of C7 intralaminar screws seems to be better than lateral mass screw. Because C7 intralaminar screw is a stronger and more reproducible fixation than employing lateral mass screws based on this *in vitro* biomechanical study<sup>5</sup>. Moreover, C7 intralaminar screw has some important anatomical advantages. Contrary to the anatomy around C1-2 joint, there are no neurovascular structures (nerve root and venous plexus) located posterior to the C6-7 facet joint and covered bone fusion surface around C7. In addition, C7 has a much larger bone graft surface compared with C2, such as the lateral mass and the rather large transverse process, which could help the fusion process<sup>9</sup>. Therefore, we believe C7 intralaminar screw is a viable option for C7 fixation even though further clinical analysis is necessary.

## CONCLUSION

Intralaminar screw fixation provides the surgeon with an alternative technique for C7 fixation. This technique is rather simple and easily adopted. Even though this technique cannot be used in the cases of C7 intralaminar fracture, large margin of safety and the ease of screw placement create a niche for this technique in the armamentarium of spine surgeons.



• Acknowledgements

This study is funded by the Clinical Research Fund of St. Vincent's Hospital in 2009.

References

- An HS, Gordin R, Renner K : Anatomic considerations for plate-screw fixation of the cervical spine. *Spine (Phila Pa 1976)* 16 : S548-S551, 1991
- Barrey C, Cotton F, Jund J, Mertens P, Perrin G : Transpedicular screwing of the seventh cervical vertebra : anatomical considerations and surgical technique. *Surg Radiol Anat* 25 : 354-360, 2003
- Bozkus H, Ames CP, Chamberlain RH, Nottmeier EW, Sonntag VK, Papadopoulos SM, et al. : Biomechanical analysis of rigid stabilization techniques for three-column injury in the lower cervical spine. *Spine (Phila Pa 1976)* 30 : 915-922, 2005
- Bruneau M, Cornelius JF, Marneffe V, Triffaux M, George B : Anatomical variations of the V2 segment of the vertebral artery. *Neurosurgery* 59 : ONS20-ONS24; discussion ONS20-ONS24, 2006
- Cardoso MJ, Dmitriev AE, Helgeson MD, Stephens F, Campbell V, Lehman RA, et al. : Using lamina screws as a salvage technique at C-7 : computed tomography and biomechanical analysis using cadaveric vertebrae. Laboratory investigation. *J Neurosurg Spine* 11 : 28-33, 2009
- Geisler FH, Mirvis SE, Zrebeet H, Joslyn JN : Titanium wire internal fixation for stabilization of injury of the cervical spine : clinical results and postoperative magnetic resonance imaging of the spinal cord. *Neurosurgery* 25 : 356-362, 1989
- Hong JT, Park DK, Lee MJ, Kim SW, An HS : Anatomical variations of the vertebral artery segment in the lower cervical spine : analysis by three-dimensional computed tomography angiography. *Spine (Phila Pa 1976)* 33 : 2422-2426, 2008
- Hong JT, Sung JH, Son BC, Lee SW, Park CK : Significance of laminar screw fixation in the subaxial cervical spine. *Spine (Phila Pa 1976)* 33 : 1739-1743, 2008
- Hong JT, Yi JS, Kim JT, Ji C, Ryu KS, Park CK : Clinical and radiologic outcome of laminar screw at C2 and C7 for posterior instrumentation-review of 25 cases and comparison of C2 and C7 intralaminar screw fixation. *Surg Neurol* 2009 [Epub ahead of print]
- Johnston TL, Karaikovic EE, Lautenschlager EP, Marcu D : Cervical pedicle screws vs. lateral mass screws : uniplanar fatigue analysis and residual pullout strengths. *Spine J* 6 : 667-672, 2006
- Jones EL, Heller JG, Silcox DH, Hutton WC : Cervical pedicle screws versus lateral mass screws. Anatomic feasibility and biomechanical comparison. *Spine (Phila Pa 1976)* 22 : 977-982, 1997
- Kothe R, Rütther W, Schneider E, Linke B : Biomechanical analysis of transpedicular screw fixation in the subaxial cervical spine. *Spine (Phila Pa 1976)* 29 : 1869-1875, 2004
- Kotil K, Bilge T : Accuracy of pedicle and mass screw placement in the spine without using fluoroscopy : a prospective clinical study. *Spine J* 8 : 591-596, 2008
- Murphy MJ, Daniaux H, Southwick WO : Posterior cervical fusion with rigid internal fixation. *Orthop Clin North Am* 17 : 55-65, 1986
- Nakanishi K, Tanaka M, Sugimoto Y, Misawa H, Takigawa T, Fujiwara K, et al. : Application of laminar screws to posterior fusion of cervical spine : measurement of the cervical vertebral arch diameter with a navigation system. *Spine (Phila Pa 1976)* 33 : 620-623, 2008
- Papagelopoulos PJ, Currier BL, Neale PG, Hokari Y, Berglund LJ, Larson DR, et al. : Biomechanical evaluation of posterior screw fixation in cadaveric cervical spines. *Clin Orthop Relat Res* : 13-24, 2003
- Rath SA, Moszko S, Schäffner PM, Cantone G, Braun V, Richter HP, et al. : Accuracy of pedicle screw insertion in the cervical spine for internal fixation using frameless stereotactic guidance. *J Neurosurg Spine* 8 : 237-245, 2008
- Sciubba DM, Noggle JC, Vellimana AK, Conway JE, Kretzer RM, Long DM, et al. : Laminar screw fixation of the axis. *J Neurosurg Spine* 8 : 327-334, 2008
- Shin EK, Panjabi MM, Chen NC, Wang JL : The anatomic variability of human cervical pedicles : considerations for transpedicular screw fixation in the middle and lower cervical spine. *Eur Spine J* 9 : 61-66, 2000
- Wang MY : Cervical crossing laminar screws : early clinical results and complications. *Neurosurgery* 61 : 311-315; discussion 315-316, 2007
- Wright NM : Posterior C2 fixation using bilateral, crossing C2 laminar screws : case series and technical note. *J Spinal Disord Tech* 17 : 158-162, 2004
- Xu R, Burgar A, Ebraheim NA, Yeasting RA : The quantitative anatomy of the laminae of the spine. *Spine (Phila Pa 1976)* 24 : 107-113, 1999
- Xu R, Ebraheim NA, Tang G, Stanescu S : Location of the vertebral artery in the cervicothoracic junction. *Am J Orthop (Belle Mead NJ)* 29 : 453-456, 2000
- Xu R, Haman SP, Ebraheim NA, Yeasting RA : The anatomic relation of lateral mass screws to the spinal nerves. A comparison of the Magerl, Anderson, and An techniques. *Spine (Phila Pa 1976)* 24 : 2057-2061, 1999
- Xu R, Kang A, Ebraheim NA, Yeasting RA : Anatomic relation between the cervical pedicle and the adjacent neural structures. *Spine (Phila Pa 1976)* 24 : 451-454, 1999
- Yukawa Y, Kato F, Yoshihara H, Yanase M, Ito K : Cervical pedicle screw fixation in 100 cases of unstable cervical injuries : pedicle axis views obtained using fluoroscopy. *J Neurosurg Spine* 5 : 488-493, 2006