

## Clinical Article

# Clinical Features and Treatments of Upper Lumbar Disc Herniations

Duk-Sung Kim, M.D., Jung-Kil Lee, M.D., Jae-Won Jang, M.D., Byung-Soo Ko, M.D., Jae-Hyun Lee, M.D., Soo-Han Kim, M.D.

Department of Neurosurgery, Chonnam National University Medical School & Research Institute of Medical Sciences, Gwangju, Korea

**Objective :** Disc herniations at the L1-L2 and L2-L3 levels are different from those at lower levels of the lumbar spine with regard to clinical characteristics and surgical outcome. Spinal canals are narrower than those of lower levels, which may compromise multiple spinal nerve roots or conus medullaris. The aim of this study was to evaluate the clinical features and surgical outcomes of upper lumbar disc herniations.

**Methods :** We retrospectively reviewed the clinical features of 41 patients who had undergone surgery for single disc herniations at the L1-L2 and L2-L3 levels from 1998 to 2007. The affected levels were L1-L2 in 14 patients and L2-L3 in 27 patients. Presenting symptoms and signs, patient characteristics, radiologic findings, operative methods, and surgical outcomes were investigated.

**Results :** The mean age of patients with upper lumbar disc was 55.5 years (ranged 31 to 78). The mean follow-up period was 16.6 months. Most patients complained of back and buttock pain (38 patients, 92%), and radiating pain in areas such as the anterior or anterolateral aspect of the thigh (32 patients, 78%). Weakness of lower extremities was observed in 16 patients (39%) and sensory disturbance was presented in 19 patients (46%). Only 6 patients (14%) had undergone previous lumbar disc surgery. Discectomy was performed using three methods : unilateral laminectomy in 27 cases, bilateral laminectomy in 3 cases, and the transdural approach in 11 cases, which were performed through total laminectomy in 10 cases and unilateral laminectomy in 1 case. With regard to surgical outcomes, preoperative symptoms improved significantly in 33 patients (80.5%), partially in 7 patients (17%), and were aggravated in 1 patient (2.5%).

**Conclusion :** Clinical features of disc herniations at the L1-L2 and L2-L3 levels were variable, and localized sensory change or pain was rarely demonstrated. In most cases, the discectomy was performed successfully by conventional posterior laminectomy. On the other hand, in large central broad based disc herniation, when the neural elements are severely compromised, the posterior transdural approach could be an alternative.

**KEY WORDS :** Clinical feature · Disc herniation · Transdural · Upper lumbar.

## INTRODUCTION

Due to the unique anatomy of the upper lumbar spine, upper lumbar disc herniations are different from those that occur at lower levels of the lumbar spine. Compared to the lower one, upper lumbar spine results in fewer cases of spondylosis, disc generation, and fewer herniated discs. Use of the term "upper lumbar" disc has been controversial. Upper lumbar discs have been reported as only L1-L2 and L2-L3 by some authors, and by others as T12-L1, L1-L2, and L2-

L3<sup>3,5,8</sup>. Most previous studies of upper lumbar disc herniations included the L1-L2, L2-L3, and L3-L4 levels. Upper lumbar disc herniations have been reported to occur with a frequency of less than 5% of all disc herniations<sup>2,17</sup>. Among these reported cases, herniations at the L3-L4 level comprise 70-83% of all upper lumbar disc herniations<sup>2,15,19</sup>. However, the anatomical characteristics of L3-L4 discs are more similar to lower levels, and its surgical outcome is significantly different from that of L1-L2 and L2-L3<sup>13,17</sup>. Therefore, the L3-L4 level might be excluded from the upper lumbar disc. Incidence of herniated upper lumbar discs defined as only L1-L2 and L2-L3 are known to comprise approximately 1 to 2% of all herniated lumbar discs<sup>5,10</sup>.

Compared with those of lower levels, upper lumbar disc herniations have a less favorable outcome after surgery<sup>16</sup>. Spinal canals are narrower than those of lower levels, which may compromise multiple spinal nerve roots or conus medul-

• Received : February 5, 2010 • Revised : July 4, 2010

• Accepted : August 3, 2010

• Address for reprints : Jung-Kil Lee, M.D.

Department of Neurosurgery, Chonnam National University Medical School & Research Institute of Medical Sciences, 8 Hak-dong, Dong-gu, Gwangju 501-757, Korea

Tel : +82-62-220-6606, Fax : +82-62-224-9865

E-mail : jkl@chonnam.ac.kr

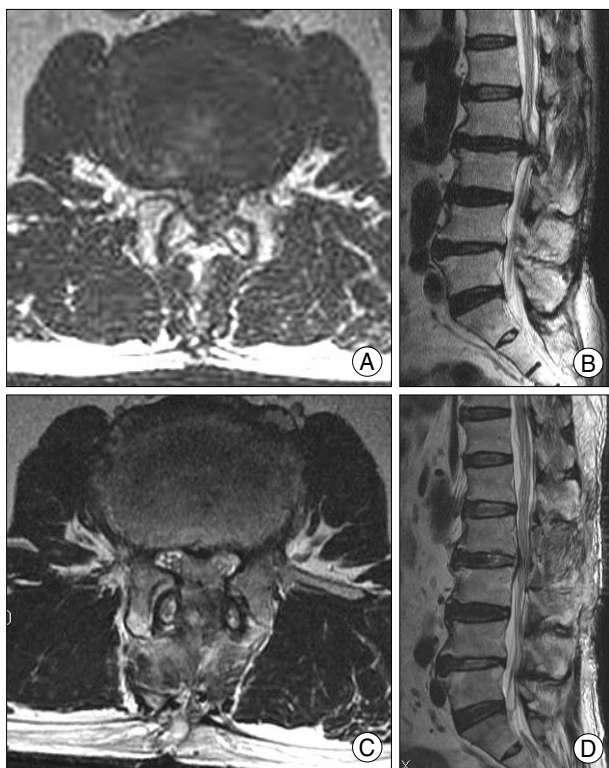laris. Lengths of the lamina are shorter, location of pain varies, and direct cord compression may occur. Because of this unique anatomy, selection of a surgical approach is difficult. In this article, through retrospective review of our patients' data, we investigated the clinical features and surgical outcomes of upper lumbar disc herniations, and evaluated the predictive factors for determination of surgical methods.

### MATERIALS AND METHODS

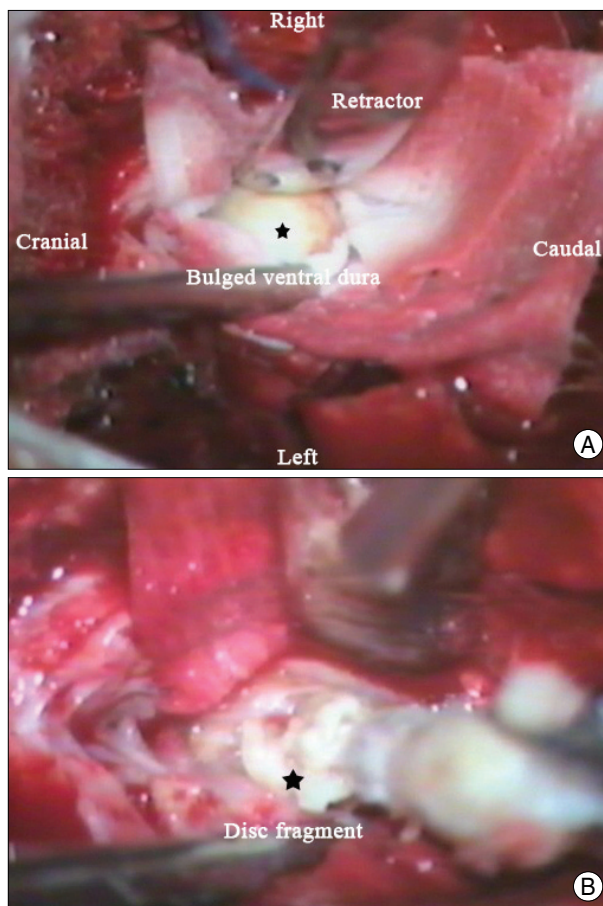
We retrospectively reviewed the medical records, radiological examinations and operative findings of 41 patients with symptomatic L1-L2 and L2-L3 disc herniation who underwent surgery in our institute between January 1998 and December 2007. Patients with the following conditions were excluded : obvious spondylosis or ossification of the ligamentum flavum or far lateral disc herniation. Preoperative data collected during review of patient medical records included the presence or absence of lower back and radicular pain, motor or sensory deficit, reflex changes, and sphincter dysfunction. Accurate distribution of sensory change was also evaluated. On preoperative magnetic resonance (MR) imaging or computerized tomography (CT) scan, we measured

the area of the spinal canal and protruded disc material at the compressive level. Disc consistency, direction, and size were also investigated on T2WI of MRI.

All patients underwent a discectomy via a posterior approach. Three surgical methods that included unilateral laminectomy, bilateral laminectomy, and a transdural approach were used. Under general anesthesia, the patient is usually prone positioned on an operating frame. The accurate level of herniated disc was checked by intraoperative fluoroscopy. Unilateral hemilaminectomy in symptomatic lesions and medial resection of the zygoapophyseal joints were performed in order to gain sufficient exposure of the discs. After retracting the compressed dural sac and discectomy, the nerve root was decompressed positively. Bilateral laminectomy was chosen if the patient complained of bilateral radiating pain. If dural sac or root retraction was not possible due to a large-sized central disc herniation, a transdural approach was selected to reduce the risk of nerve root injury (Fig. 1). After laminectomy, the incised dorsal dura was tacked, and the cauda equina rootlets were gently retracted. An intention-



**Fig. 1.** Seventy year-old male presented with radiating pain in both legs for 3 months. Preoperative axial (A) and sagittal (B) T2-weighted MR images show a marked, diffuse central disc at the L2-L3 level. Postoperative axial (C) and sagittal (D) T2-weighted MR images demonstrate complete decompression of the L2-L3 disc protrusion after the transdural approach.



**Fig. 2.** Intraoperative photographs. A : Photograph after laminectomy and dural opening demonstrating central bulging of the ventral dura. B : Photographs after ventral durotomy showing the disc removal by pituitary forceps through the dural hole.

nal durotomy, over its maximal bulging of the ventral dura, was performed (Fig. 2). Adequate decompression with removal of calcified disc fragments and osteophytes was accomplished after meticulous dissection of dense adhesions between the disc herniation and the dural sac.

Patients underwent postoperative radiograph prior to discharge. They were then followed up at 1, 3, 6, and 12 months postoperatively, and then annually. In addition to radiographic analysis, postoperative follow-up evaluation included a review of medical records and a postoperative visit to the outpatient clinic. Radiographs included standing anteroposterior, lateral lumbar views, and dynamic flexion/extension radiographs for determination of the stability status. Patients' outcomes were assessed using a modified Odom's criteria. Motor and sensory examinations were graded by the operating surgeon as improved, unchanged, or worse. Postoperative back pain and radicular pain were graded in the same manner. As an outcome-based study, the primary end-point of evaluation was based on radiographic findings and clinical improvement. Additional information was obtained via telephone interview with the authors of this study who were not the operating surgeons.

Statistical analysis of the data was performed using SPSS statistical software (version 15.0, Chicago, IL, USA). The multiple logistic regression test was used for the statistical analysis. Statistical significance was set at a probability value of less than 0.05.

## RESULTS

The study included 25 men and 16 women with a mean age of 55.52 years (range, 31-78 years). Average follow-up time was 16.6 months (range, 3-120.8 months). Of the entire group, 14 patients had L1-L2 disc herniations and 27 had L2-L3 disc herniations. Six patients had a previous history of lumbar surgery. Two of these patients had posterior screw fixation on levels L2-L3 and L3-L4-L5, and the others had simple laminectomy and discectomy on lower level disc herniation. Eighteen patients had coinciding disc herniation; one had T12-L1, 5 had L3-L4, 10 had

L4-L5, and 2 had L5-S1 disc herniation. Clinical symptoms associated with accompanying disc herniation were excluded.

Clinical features are shown in Fig. 3. Most patients had nonspecific leg and back pain, similar to that of lower lumbar disc herniation. Distribution of pain or sensory change is presented in Fig. 4. Patients complained of pain in the buttocks (n = 8), posterior and posterolateral thigh (n = 10), anterior aspect of the thigh (n = 4), anterolateral aspect of the thigh (n = 5), calf area (n = 2), sole area (n = 3), and foot dorsum (n = 2). Only one patient showed sensory change in the inguinal area, which was correspond to the L1 sensory dermatome. Nine patients showed sensory change in the anterior and anterolateral thigh, which was in agreement with the L2 sensory dermatome. Radiologic findings of disc consistency, direction and distribution are presented in Table

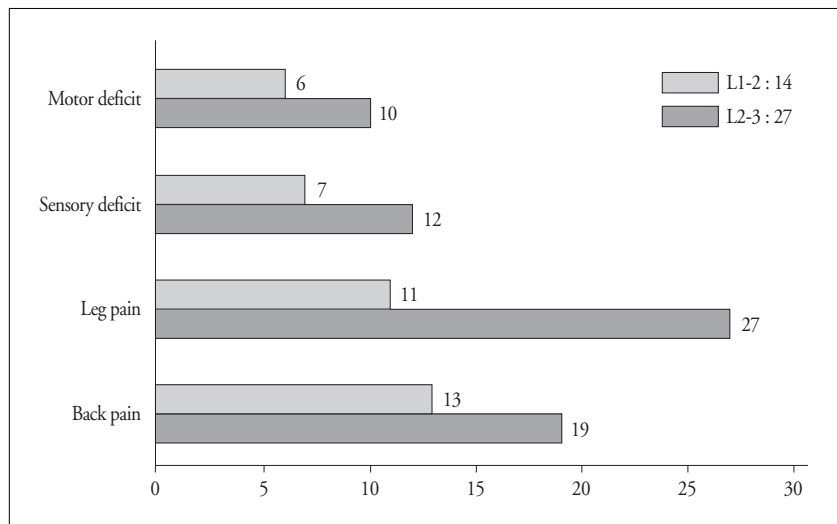


Fig. 3. Clinical features of L1-L2 and L2-L3 disc herniations.

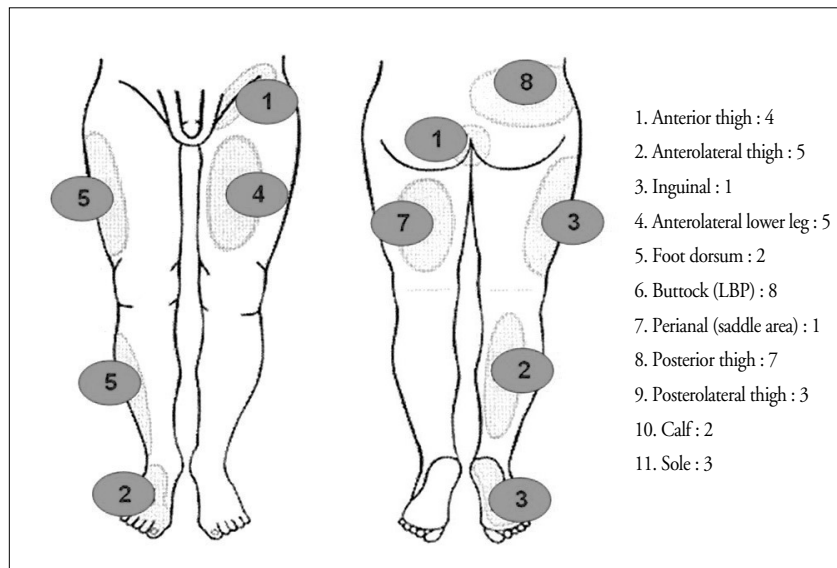


Fig. 4. Schematic drawings showing distribution of pain or sensory change.

**Table 1.** Radiologic findings of herniated disc

Level	Disc consistency		Direction		Distribution	
	Hard	Soft	Central	Lateral	Diffuse	Focal
L1-L2	6	8	8	6	6	8
L2-L3	9	18	9	18	9	18

**Table 2.** Surgical method according to disc consistency, direction, and size

Operation method	Disc consistency		Direction		Distribution	
	Hard	Soft	Central	Lateral	Diffuse	Focal
Unilateral laminectomy	7	20	6	21	7	20
Bilateral laminectomy	2	1	2	1	2	1
Transdural approach	6	5	9	2	6	5

**Table 3.** Modified Odom's criteria

Excellent	Improvement in most (at least 80%) of the preoperative signs and symptoms, with little deterioration (not more than 10%)
Good	Improvement in some (at least 70%) of the preoperative signs and symptoms, with some deterioration(not more than 15%)
Fair	Improvement in half (at least 50%) of the preoperative signs and symptoms, with little deterioration (not more than 20%)
Poor	Improvement in few (at least 50%) of the preoperative signs and symptoms, with little deterioration (more than 20%)

Excellent : complete recovery and return to previous activity, Good : occasional back or leg pain and return to previous activity, Fair : partial recovery and modified activities, Poor : no relief of the original symptoms or worsening of symptoms

**Table 4.** Surgical outcomes according to herniated disc level

Outcome	L1-L2 (%)	L2-L3 (%)	Total(%)
Excellent	8 (57)	15 (56)	23 (56)
Good	3 (21)	7 (26)	10 (25)
Fair	2 (14)	5 (18)	7 (17)
Poor	1 (7)	0 (0)	1 (2)

Excellent : complete recovery and return to previous activity, Good : occasional back or leg pain and return to previous activity, Fair : partial recovery and modified activities, Poor : no relief of the original symptoms or worsening of symptoms

**Table 5.** Surgical outcomes according to surgical method

Outcome	Unilateral (%)	Bilateral (%)	Transdural (%)	Total (%)
Excellent	18 (67)	2 (67)	3 (27)	23 (56)
Good	4 (15)	1 (33)	5 (45)	10 (25)
Fair	5 (18)	0 (0)	2 (18)	7 (17)
Poor	0 (0)	0 (0)	1 (9)	1 (2)

Excellent : complete recovery and return to previous activity, Good : occasional back or leg pain and return to previous activity, Fair : partial recovery and modified activities, Poor : no relief of the original symptoms or worsening of symptoms

1. Surgical methods according to radiologic findings are presented in Table 2; unilateral laminectomy (n = 27), bilateral laminectomy (n = 3), and transdural approach (n = 11). Clinical outcomes were assessed by Odom's criteria (Table 3). Thirty three patients (81%) had "Good" and "Excellent" for outcome (Table 4). Eight patients had unsatisfactory outcome; 7 patients (17%) were partially relieved and 1 patient (2.5%) was aggravated.

Clinical outcomes according to surgical method are shown in Table 5. Surgical results for the transdural approach appeared to be worse than those of the unilateral approach. However, in result of multiple logistic regression analysis, there

were no significant correlations between clinical outcomes and variables such as disc consistency, disc direction, disc distribution and surgical methods (odds ratio = 1.239, *p* = 0.849, 95% CI 0.136-11.308). There were no major complications related to the surgery. Complications related to the transdural approach, such as leakage of cerebrospinal fluid or intraoperative cauda equina injury did not occur.

## DISCUSSION

Clinical symptoms and neurological findings associated with upper lumbar disc herniations are non-specific. Also, presenting symptoms of upper lumbar disc herniations are often useless for accurate diagnosis of the level of disease. Unique characteristics of upper lumbar disc herniation include ill-defined polyradiculopathies that cannot be clearly categorized into typical muscle group weakness, dermatomal sensory deficits, or reflex deficits<sup>17</sup>. These polyradiculopathies may be associated with a narrower upper lumbar spinal canal compared with the lower spinal canal, resulting in compromise of multiple roots by a single disc herniation<sup>6,17,18</sup>. In this study, clinical symptoms are quite variable, and localized sensory change or pain was rarely demonstrated. An accurate diagnosis is often difficult. The positive femoral stretch test is known as a relatively good diagnostic method in 84 to 94% of upper lumbar disc herniation<sup>2,13,18</sup>. Pain provocation by the femoral stretch test is believed to be caused by stretching of the femoral nerve. Because the L2, L3, or L4 spinal nerve roots are the main components of the femoral nerve, cases with symptomatic upper lumbar disc herniation may have more opportunities to show positive results for the femoral stretch test compared to cases with lower lumbar disc herniation<sup>7,13</sup>. However, in our cases, it was not helpful in differentiation of diagnosis. Most patients had nonspecific and generalized symptoms, such as lower back pain, buttock pain, and posterior thigh radiating pain. The typical clinical symptom of upper lumbar herniation, anterior thigh pain or inguinal



pain, was demonstrated in only 10 patients (24%). Only one patient (2.4%) had symptoms of autonomic (bowel/bladder sphincter) dysfunction from a cauda equina lesion. Previous studies have reported a rate disturbance as high as 27% in autonomic function with upper lumbar discs<sup>2,4</sup>. Location of the conus medullaris in association with a high lumbar disc herniation may be a cause of predisposal to these symptoms. MR images are helpful in revealing the location of the conus medullaris and lesions of the upper lumbar level more clearly. Radiographic techniques, including MRI and CT, are essential for diagnosis of the lesion and for identification of the precise location. Therefore, preoperative careful investigation would be useful for differential diagnosis and prevention of misdiagnosis in cases of upper lumbar disc herniation.

Treatment of upper lumbar disc herniation presents additional problems for the spinal surgeon due to low incidence and delay in diagnosis resulting from the absence of classic clinical characteristics<sup>17</sup>. Surgical outcome for disc herniation at the upper lumbar levels (L1-L2 and L2-L3) is less satisfactory than for those treated at lower lumbar levels<sup>2,16,17</sup>. Albert et al.<sup>2</sup> reported that good or excellent surgical outcome was noted in 80% of 141 patients and Sanderson et al.<sup>17</sup> found good or excellent prognosis in 53% of patients with upper lumbar disc herniation. In this series, 33 out of 41 patients (81%) showed favorable surgical outcomes.

The choice of the surgical approach is an important issue when treating patients with disc herniation in the upper lumbar spine. A patient's age or medical problems, kyphotic change or scoliosis of the thoracolumbar vertebra, and the type of disc herniation are considered carefully. Factors considered important for determination of the surgical approach include: disc size, location, extent of calcification, surgeon's experience, degree of spinal cord deformation, and the general medical condition of the patient. Radiologic findings for L1-L2 and L2-L3 disc herniations are one of the important criteria for selection of the surgical approach. Several operative procedures for treatment of patients with upper lumbar disc herniations have been introduced<sup>1,6,11-13</sup>. Anterior approaches can be used for treatment of disc herniations that are primarily anterior to the spinal cord. For anterior decompression and fusion, several surgical morbidities, such as nonunion, graft problems, and donor site complications could be associated. Postoperative external orthosis is also necessary for enhancement of graft incorporation. An endoscopic approach could be selected for an alternative to traditional open surgery. Compared with open surgery, endoscopy provides identical visualization and exposure of the spine, with reduced incidence of operative morbidity, less pain, cosmetic benefit and rapid recovery<sup>1,6,9</sup>. Endoscopic decompression, however, is a technically demanding procedure. Safe performance

of the procedure requires extensive skill and dedicated laboratory practice. The steep learning curve and unfamiliar surgical technique make this procedure less practical for surgeons who do not perform it frequently. In addition, the effectiveness has not been proven. Due to its familiarity among spinal surgeons, the posterior approach for treatment of upper lumbar disc herniation is usually preferred. The disc is commonly approached by gentle medial retraction of the nerve root using a narrow blunt retractor. This approach is particularly suitable for removal of disc material if a disc herniation is small, focal, soft, and located laterally in the spinal canal. Preoperative determination of the nature and amount of disc material is an important parameter. Simple laminectomy is suitable for focal, unilateral, and soft disc herniation. If patients with upper lumbar disc herniation have bilateral symptoms and corresponding bilateral radiological evidence, bilateral laminectomy can be considered. If necessary, medial facetectomy can be used for removal of ruptured fragments according to the direction of disc migration, due to the fact that unilateral or bilateral medial facetectomy has not had an impact on postoperative instability<sup>14</sup>. None of the patients in our study showed radiographic evidence of instability on flexion/extension lumbar spine X-rays.

However, use of the conventional posterior approach to an upper lumbar disc herniation may sometimes increase the risk of damage to the spinal cord or the exiting nerve root due to insufficient operative field caused by the narrow lamina window of the upper lumbar spine. For avoidance of such problems, an oblique paraspinous approach has been introduced<sup>11,13</sup>. On the other hand, we adopted a transdural approach for large, central, broad based, and hard-calcified disc herniation. Under a microscopic view, the transdural approach offers direct access to the pathological entities and makes a possible the removals of them sufficiently without too much retraction of the compromised nerve root. With this approach, awareness of the actual position of the caudal end of the spinal cord on MRI is important. The caudal end of the spinal cord is most frequently located between the lower half of the L1 vertebral body and the upper half of the L2 vertebral body; however, individual variations are considerable<sup>18</sup>. In this study, three patients had unsatisfactory postoperative results after the transdural approach. One patient had preoperative cauda equina syndrome, and showed no improvement because the operation may have been delayed for too long. Two other patients had transient urinary dysfunction and motor weakness resulting from large central L1-L2 disc herniation. However, they recovered completely during the follow-up period. The transdural approach is a safe and useful procedure that can be used to achieve sufficient decompression of the dura without retrac-

tion of the compromised nerve root and postoperative spinal instability for patients with central calcified disc herniation of the upper lumbar spine. Although the follow-up period was limited, the transdural approach can avoid nerve root injury, postoperative spinal instability, graft morbidity, and routine use of postoperative orthosis. Careful selection of a modified posterior approach according to disc herniation type appears to have great importance in the effort to achieve better surgical outcomes.

## CONCLUSION

Clinical features of upper lumbar disc herniations were different from those of lower lesions. Due to unexpectedly large differences in neurologic findings and clinical manifestations among the herniated disc levels, an accurate workup is needed to avoid misdiagnosis. In our series, discectomy was successfully performed by unilateral or bilateral laminectomy. On the other hand, the posterior transdural approach could be an alternative if the neural elements are severely compromised by large, central, or broad based disc herniation. Therefore, in upper lumbar disc herniation, favorable clinical outcomes can be expected by adequate selection of surgical methods in consideration of each herniated disc nature such as consistency, direction, and distribution.

## References

- Ahn Y, Lee SH, Lee JH, Kim JU, Liu WC : Transforaminal percutaneous endoscopic lumbar discectomy for upper lumbar disc herniation : clinical outcome, prognostic factors, and technical consideration. *Acta Neurochir (Wien)* 151 : 199-206, 2009
- Albert TJ, Balderston RA, Heller JG, Herkowitz HN, Garfin SR, Tomany K, et al. : Upper lumbar disc herniations. *J Spinal Disord* 6 : 351-359, 1993
- Bartolomei L, Carbonin C, Cagnin G, Toso V : Unilateral swelling of the lower abdominal wall. Unusual clinical manifestation of an upper lumbar disc herniation. *Acta Neurochir (Wien)* 117 : 78-79, 1992
- Billet FP, Ponssen H, Veenhuizen D : Unilateral paresis of the abdominal wall : a radicular syndrome caused by herniation of the L1-2 disc? *J Neurol Neurosurg Psychiatry* 52 : 678, 1989
- Bosacco SJ, Berman AT, Raisia LW, Zamarin RI : High lumbar disk herniations. Case reports. *Orthopedics* 12 : 275-278, 1989
- Choi JW, Lee JK, Moon KS, Hur H, Kim YS, Kim SH : Transdural approach for calcified central disc herniations of the upper lumbar spine. Technical note. *J Neurosurg Spine* 7 : 370-374, 2007
- Estridge MN, Rouhe SA, Johnson NG : The femoral stretching test. A valuable sign in diagnosing upper lumbar disc herniations. *J Neurosurg* 57 : 813-817, 1982
- Fontanesi G, Tartaglia I, Cavazzuti A, Giancetti F : Prolapsed intervertebral disc at the upper lumbar level. Diagnostic difficulties. A report on 12 cases. *Ital J Orthop Traumatol* 13 : 501-507, 1987
- Hovorka I, de Peretti F, Damon F, Arcamone H, Argenson C : Five years' experience of the retroperitoneal lumbar and thoracolumbar surgery. *Eur Spine J* 9 : S30-S34, 2000
- Hsu K, Zucherman J, Shea W, Kaiser J, White A, Schofferman J, et al. : High lumbar disc degeneration. Incidence and etiology. *Spine (Phila Pa 1976)* 15 : 679-682, 1990
- Kim JS, Lee SH, Moon KH, Lee HY : Surgical results of the oblique paraspinous approach in upper lumbar disc herniation and thoracolumbar junction. *Neurosurgery* 65 : 95-99; discussion 99, 2009
- Krauss WE, Edwards DA, Cohen-Gadol AA : Transthoracic discectomy without interbody fusion. *Surg Neurol* 63 : 403-408; discussion 408-409, 2005
- Lee SH, Choi SM : L1-2 disc herniations : clinical characteristics and surgical results. *J Korean Neurosurg Soc* 38 : 196-201, 2005
- Morinaga T, Takahashi K, Yamagata M, Chiba T, Tanaka K, Takahashi Y, et al. : Sensory innervation to the anterior portion of lumbar intervertebral disc. *Spine (Phila Pa 1976)* 21 : 1848-1851, 1996
- Pásztor E, Szarvas I : Herniation of the upper lumbar discs. *Neurosurg Rev* 4 : 151-157, 1981
- Saberi H, Isfahani AV : Higher preoperative Oswestry Disability Index is associated with better surgical outcome in upper lumbar disc herniations. *Eur Spine J* 17 : 117-121, 2008
- Sanderson SP, Houten J, Errico T, Forshaw D, Bauman J, Cooper PR : The unique characteristics of "upper" lumbar disc herniations. *Neurosurgery* 55 : 385-389; discussion 389, 2004
- Tokuhashi Y, Matsuzaki H, Uematsu Y, Oda H : Symptoms of thoracolumbar junction disc herniation. *Spine (Phila Pa 1976)* 26 : E512-E518, 2001
- Wei CP, Cheng WC, Chang CN, Lee ST, Lui TN, Wang AD : Upper lumbar disc herniation. *Changeng Yi Xue Za Zhi* 12 : 193-199, 1989