

## Clinical Article

# Intentional Sparing of Daughter Sac from Coil Packing in the Embolization of Aneurysms Causing the Third Cranial Nerve Palsy : Initial Clinical and Radiological Results

Chang-Woo Kang, M.D., Hyon-Jo Kwon, M.D., Se-Jin Jeong, M.D., Hyeon-Song Koh, M.D., Seung-Won Choi, M.D., Seon-Hwan Kim, M.D.  
*Department of Neurosurgery, Chungnam National University Hospital & Medical School, Daejeon, Korea*

**Objective :** Cerebral aneurysms which cause oculomotor nerve [cranial nerve (CN) III] palsy, are frequently found with a daughter sac of the aneurysm dome. We assumed that CN III might be compressed by the daughter sac and it would be more helpful not to fill the daughter sac with coils than vice versa during endosaccular embolization for recovering from CN III palsy, because it may give a greater chance for the daughter sac to shrink by itself later. We reviewed the initial results of our experiences of such cases.

**Methods :** Among 9 aneurysms accompanied by CN III palsy, 7 (6 unruptured, 1 ruptured) showed a daughter sac. We tried to fill the main dome completely and spare the daughter sac from coil filling to increase the possibility of decompression. We evaluated the short-term effectiveness of this concept using medical records and angiograms.

**Results :** After initial embolization, all of CN III palsy caused by unruptured aneurysms (6/6) resolved completely after various periods (3-90 days) of time. No adverse effects were noted during and after the procedures except for one case of harmless coil stretching during coil filling using double microcatheter.

**Conclusion :** During the coil embolization of the cerebral aneurysm causing CN III palsy, sparing the daughter sac from coil packing while tightly packing the main dome, can be helpful in increasing the effectiveness of decompression. However, a long-term follow-up will be required.

**KEY WORDS :** Cerebral aneurysm · Embolization · Oculomotor nerve palsy · Decompression.

## INTRODUCTION

It is widely known that some cerebral aneurysms can cause oculomotor nerve [cranial nerve (CN) III] palsy either completely or partially by direct mechanical compression<sup>3,5,6,14</sup>. It can be induced by an increase in aneurysm volume, with or without accompanying subarachnoid hemorrhage (SAH).

Complete or partial recovery of CN III palsy after clipping has been widely reported while the recovery rate after coiling has been documented only in a small number of reports and is

not as good as that of clipping<sup>1-3,6,8,16</sup>. In contrast to clipping, which can shrink or puncture the aneurysm dome at the end of the operation for more effective decompression<sup>3,15,16</sup>, coiling by its nature tends to maintain the original size of the dome by filling in detachable coils after successful embolization.

The authors found that most of the aneurysms causing CN III palsy have a daughter sac at the distal end of the long axis of the aneurysm dome which is thought to be the compressing portion of CN III. During embolization of such aneurysms, we tried to fill the main dome completely while intentionally sparing the distal daughter sac from coil packing. We thought that by sparing the daughter sac we could decompress CN III more efficiently because the daughter sac may have a greater chance of involution when there is no coil in it (Fig. 1). We report the initial clinical and radiological outcomes after embolization using such a concept.

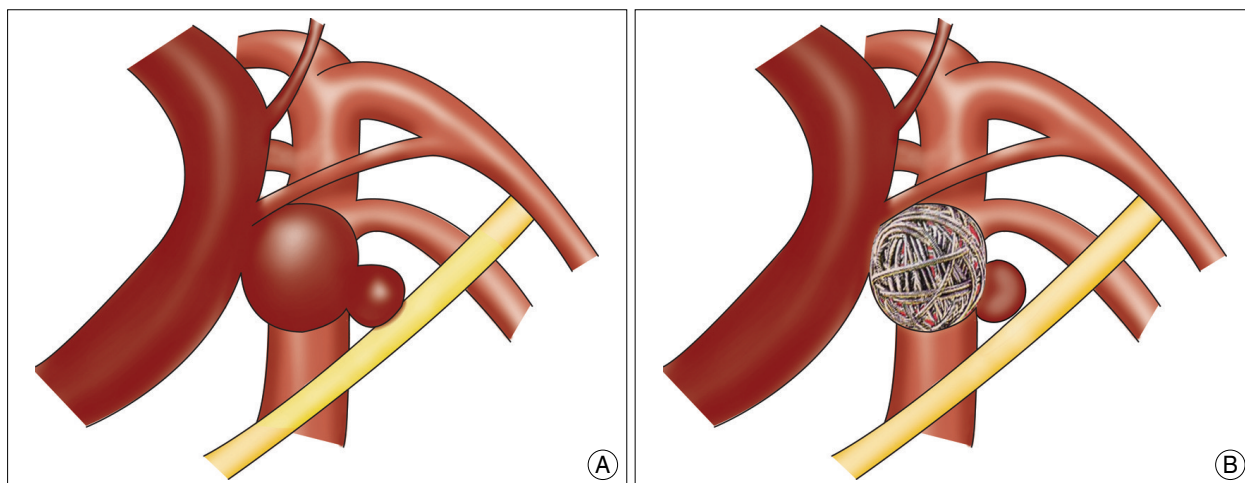
• Received : April 24, 2010 • Revised : July 11, 2010

• Accepted : August 9, 2010

• Address for reprints : Hyon-Jo Kwon, M.D.

Department of Neurosurgery, Chungnam National University Hospital & Medical School, 33 Munhwa-ro, Jung-gu, Daejeon 301-721, Korea  
Tel : +82-42-280-8372, Fax : +82-42-280-7363

E-mail : solesoul@cnuh.co.kr



**Fig. 1.** Concept schema. Initial (A) and completely filling the main dome with coil while intentionally sparing the distal daughter sac resulting in involution of daughter sac later (B).

**Table 1.** Clinical and radiological findings of patients

Patient No	Age (yrs)/sex	Symptom duration (hr)	Aneurysm size (mm)	Daughter sac size (mm)	Coil mass size (mm)	Aneurysm neck size (mm)	Aneurysm projection	Presence of SAH	Palsy type	Recovery type	Recovery time (days)	Radiologic results	Operation time (hr : min)
1	86/F	48	12.3	4.5	7.7	5.8	Inf. & Post.	×	Complete	Complete	60	RN	3 : 55
2	49/F	5	5.3	1.7	3.7	2.2	Inf. & Post.	×	Partial	Complete	3	CO	2 : 20
3	50/M	120	6.0	2.0	3.9	2.1	Inf. & Post.	×	Complete	Complete	14	CO	2 : 10
4	68/F	155	10.0	5.2	6.1	2.8	Inf. & Post.	×	Complete	Complete	60	RN	2 : 15
5	82/F	7	10.1	4.3	6.2	5.5	Inf. & Post.	○	Complete	Undetermined*		CO	1 : 15
6	74/F	48	4.7	1.9	4.0	3.2	Inf. & Post.	×	Complete	Complete	27	CO	1 : 50
7	60/F	168	13.3	3.2	9.8	6.5	Inf. & Post.	×	Complete	Complete	90	RN	1 : 35

\*Expired after 2 months due to lung problem. CO : complete obliteration, hr : hours, Inf. : inferior, min : minutes, Post. : posterior, SAH : subarachnoid hemorrhage, RN : residual neck

**MATERIALS AND METHODS**

From April 2006 to September 2009, 9 cases of aneurysm-induced unilateral CN III palsy were treated with endovascular coil embolization at our institution. All of the aneurysms were located at the distal internal carotid artery and seven of them were composed of daughter sacs presumed to compress directly on CN III. Seven aneurysms with daughter sacs are included in this study. There were 6 women and 1 man with a mean age of 67 years (range, 49-86 years) at the time of treatment. Initial complete CN III palsy was seen in 6 patients and partial in one. Most (6 of 7) patients showed CN III palsy as the only symptom except for 1 patient who presented with concomitant SAH (patient no. 5) (Table 1). Mean aneurysm size including daughter sac was 8.8 mm (range, 4.7-13.3 mm), mean aneurysmal neck size was 4.0 mm (range, 2.1-6.5 mm), and mean daughter sac size was 3.3 mm (range, 1.7-4.5 mm). All of the aneurysms showed an inferoposterior projection from the parent artery. The average duration of CN III palsy before treatment was 80 hours (range, 5 hours-7 days) (Table 1). The criteria for complete preoperative CN III palsy were as follows : 1) reports of

diplopia, 2) ptosis, 3) ophthalmoplegia, and 4) pupillary dysfunction<sup>3,6</sup>. Complete recovery was defined as recovery from all of these symptoms<sup>3,6</sup>. We determined the degree of recovery by reviewing the patients' medical records.

**Embolization**

In all cases we used current technique of endosaccular embolization using detachable platinum coils under general anesthesia<sup>10</sup>. Attempts were made not to fill the daughter sac with coils and we used the double microcatheter technique in 4 cases (patient no. 1, 4, 5, 7) and stent-assisted technique in 1 (patient no. 6). The double microcatheter technique was useful for both relatively wide aneurysmal neck and making a stable coil frame for the main dome only. The mean operation time was 2 hours 11 minutes (range, 1 hour 15 minutes-3 hours 55 minutes). Assessment criteria for postoperative radiological results were complete obliteration, residual neck, and residual aneurysm<sup>12</sup>.

**RESULTS**

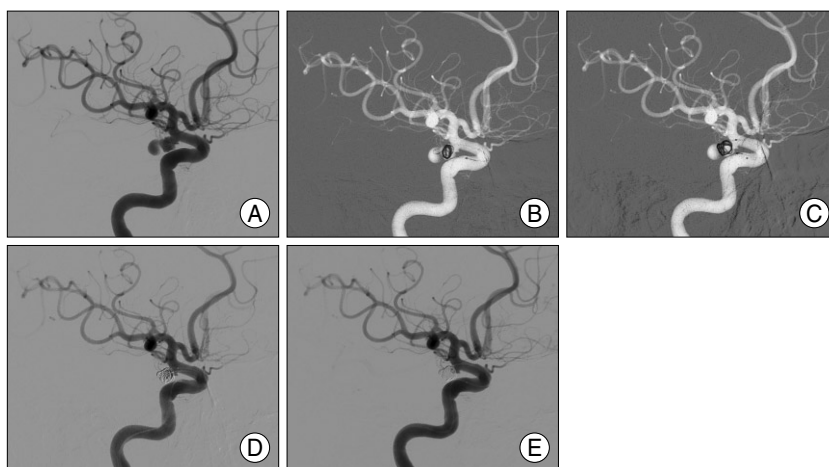
In all cases, we performed coil embolization by filling the

main dome while intentionally sparing the daughter sac. Postoperative radiologic results were as follows : 1) complete obliteration in 4 cases (Fig. 2), 2) residual neck in 3 cases, and 3) no case of residual aneurysm. The mean size of the coil masses (5.9 mm) is smaller than that of the pre-embolized aneurysm (8.8 mm) by 67%, by sparing the daughter sac from coil filling (Table 1). There were no serious complications associated such as thromboembolism or rupture but one case of harmless coil stretching during coil filling using double microcatheter (patient no. 1). All of the patients recovered completely from CN III palsy except for one patient who had concomitant SAH and expired from lung problems after 2 months (patient no. 5). The average time of recovery was 42 days (range, 3-90 days).

## DISCUSSION

Coil packing is known to decompress CN III by reducing the pulsatile expansion of the aneurysm dome<sup>6,8,15</sup>. However, it is generally accepted that clipping is superior to coiling because there is the possibility of intraoperative decompression such as resection or shrinkage of the dome<sup>3,15,16</sup>. The average recovery rate after embolization is lower than that of clipping and even two (1 permanent) cases of new CN III palsy after embolization of aneurysms have been reported<sup>2,3</sup>. There are also reports that embolized aneurysms usually become larger than initial ones<sup>17</sup> and can cause surrounding edema, especially when the aneurysm is located close to the brain parenchyme<sup>7</sup>. However, there has been no other report on improvement of the recovery rate after embolization except for early intervention of the partially affected patients<sup>6,8</sup>.

Our observations led us to assume that it is usually the daughter sac at the distal end of the main dome which causes the compression of the CN III and attempts were made to spare the daughter sac from coil packing. Our hypothesis is that when the daughter sac is free from coils, it can have more chance of involution to a smaller size which can help decompress the CN III (Fig. 1). There is also a possibility of aggravating the symptoms after sparing the daughter sac from coil filling because of the size increase as the thrombosis proceeds. We think that the size increase is a transient event which will, in time, eventually become a smaller size. De Gast et al.<sup>4</sup> documented similar results from parent artery occlusion for large and giant aneurysms. They confirmed spontaneous



**Fig. 2.** Serial embolization images of patient no. 4. Pretreatment (A), coli packing (B, C, and D), and pretreatment with tiny neck remnant (E). It shows a coil loop entering the daughter sac temporarily (B), but withdrawn to the main dome afterward.

involution of large and giant aneurysms after complete occlusion of the parent artery only. Although sizes of the daughter sacs are much smaller than those of large and giant aneurysms, we thought that even a minute involution of the daughter sac can help the decompression, especially in aneurysms with large size and long duration of symptoms. In some cases we tried to find the changes in size of the daughter sacs after sparing them from coil filling by taking thin sliced MRI. However, we could not compare the sizes of the daughter sacs precisely because they were too small.

Radiologically, we cannot confirm whether the CN III is compressed by the spared daughter sac. However, the authors think that the possibility of daughter sacs being the culprits of CN III compression is high because all of the aneurysms in this study projected inferoposteriorly from the distal internal carotid artery<sup>16</sup>. Also, all of the daughter sacs were found at the very distal end, along the long axes of the aneurysms. We think that it is more likely for an aneurysm to grow along the long axis than in any other direction, so the chances of compression are high with distal daughter sacs of aneurysms which project inferoposteriorly from a distal internal carotid artery. Although the exact influences of our concept on decompression are hard to measure, our relatively better recovery rate, compared to previous reports, supports our hypothesis of a more effective decompression than usual embolization.

Sparing the daughter sac from coil packing can decrease the need for the catheter tip to be situated deeply in the aneurysm dome, which can diminish the risk of rupture. On the other hand, technical difficulty of sparing the daughter sac can lengthen the procedure time, which can increase the possibilities of thromboembolic complications<sup>9</sup>. Our initial results indicate that there is no additional risk of such adverse effects in sparing the daughter sac. However, because we left

the daughter sac unpacked, other adverse effects such as the compaction of the coil mass<sup>13)</sup>, recurrence of CN III palsy<sup>2)</sup> and even bleeding should be closely monitored and follow-up of patients both clinically and radiologically for a long period of time is needed<sup>11)</sup>.

## CONCLUSION

During the coil embolization of the cerebral aneurysms causing CN III palsy, sparing the daughter sac from coil filling while tightly packing the main dome, can be helpful in increasing the effectiveness of decompression. Long-term follow-up is mandatory.

### • Acknowledgements

The authors thank to Sung-Kyung Kang for illustration.

## References

- Birchall D, Khangure MS, McAuliffe W : Resolution of third nerve paresis after endovascular management of aneurysms of the posterior communicating artery. *AJNR Am J Neuroradiol* 20 : 411-413, 1999
- Bulsara KR, Jackson D, Galvan GM : Rate of third nerve palsy recovery following endovascular management of cerebral aneurysms. *Neurosurg Rev* 30 : 307-310; discussion 310-311, 2007
- Chen PR, Amin-Hanjani S, Albuquerque FC, McDougall C, Zabramski JM, Spetzler RF : Outcome of oculomotor nerve palsy from posterior communicating artery aneurysms : comparison of clipping and coiling. *Neurosurgery* 58 : 1040-1046; discussion 1040-1046, 2006
- de Gast AN, Sprengers ME, van Rooij WJ, Lavini C, Sluzewski M, Majoie CB : Midterm clinical and magnetic resonance imaging follow-up of large and giant carotid artery aneurysms after therapeutic carotid artery occlusion. *Neurosurgery* 60 : 1025-1029; discussion 1029-1031, 2007
- Feely M, Kapoor S : Third nerve palsy due to posterior communicating artery aneurysm : the importance of early surgery. *J Neurol Neurosurg Psychiatry* 50 : 1051-1052, 1987
- Hanse MC, Gerrits MC, van Rooij WJ, Houben MP, Nijssen PC, Sluzewski M : Recovery of posterior communicating artery aneurysm-induced oculomotor palsy after coiling. *AJNR Am J Neuroradiol* 29 : 988-990, 2008
- Horie N, Kitagawa N, Morikawa M, Tsutsumi K, Kaminogo M, Nagata I : Progressive perianeurysmal edema induced after endovascular coil embolization. Report of three cases and review of the literature. *J Neurosurg* 106 : 916-920, 2007
- Kim DJ, Kim DI, Lee SK, Kim SY : Unruptured aneurysms with cranial nerve symptoms : efficacy of endosaccular Guglielmi detachable coil treatment. *Korean J Radiol* 4 : 141-145, 2003
- Kim HK, Hwang SK, Kim SH : Types of thromboembolic complications in coil embolization for intracerebral aneurysms and management. *J Korean Neurosurg Soc* 46 : 226-231, 2009
- Murayama Y, Nien YL, Duckwiler G, Gobin YP, Jahan R, Frazee J, et al. : Guglielmi detachable coil embolization of cerebral aneurysms : 11 years' experience. *J Neurosurg* 98 : 959-966, 2003
- Raymond J, Guilbert F, Weill A, Georganos SA, Juravsky L, Lambert A, et al. : Long-term angiographic recurrences after selective endovascular treatment of aneurysms with detachable coils. *Stroke* 34 : 1398-1403, 2003
- Roy D, Milot G, Raymond J : Endovascular treatment of unruptured aneurysms. *Stroke* 32 : 1998-2004, 2001
- Sluzewski M, van Rooij WJ, Slob MJ, Bescós JO, Slump CH, Wijnalda D : Relation between aneurysm volume, packing, and compaction in 145 cerebral aneurysms treated with coils. *Radiology* 231 : 653-658, 2004
- Soni SR : Aneurysms of the posterior communicating artery and oculomotor paresis. *J Neurol Neurosurg Psychiatry* 37 : 475-484, 1974
- Yanaka K, Matsumaru Y, Mashiko R, Hyodo A, Sugimoto K, Nose T : Small unruptured cerebral aneurysms presenting with oculomotor nerve palsy. *Neurosurgery* 52 : 553-557; discussion 556-557, 2003
- Yerramneni VK, Chandra PS, Kasliwal MK, Sinha S, Suri A, Gupta A, et al. : Recovery of oculomotor nerve palsy following surgical clipping of posterior communicating artery aneurysms. *Neurol India* 58 : 103-105, 2010
- Yu SC, Wong WC, Chung AC, Lee KT, Wong GK, Poon WS : Does endoluminal coil embolization cause distension of intracranial aneurysms? *Neuroradiology* 48 : 653-660, 2006