

## Case Report

# Surgical Experience of Neglected Lower Cervical Spine Fracture in Patient with Ankylosing Spondylitis

Dae-Jean Jo, M.D.,<sup>1</sup> Sung-Min Kim, M.D.,<sup>1</sup> Ki-Tack Kim, M.D.,<sup>2</sup> Eun-Min Seo, M.D.<sup>3</sup>

Departments of Neurosurgery,<sup>1</sup> Orthopedic Surgery,<sup>2</sup> Spine Center, Kyung Hee University East-West Neo Medical Center, Seoul, Korea  
Department of Orthopedic Surgery,<sup>3</sup> Chunchon Sacred Heart Hospital, Hallym University College of Medicine, Chuncheon, Korea

The management of lower cervical fractures in patients with ankylosing spondylitis (AS) differs from normal cervical fractures. Patients with AS are highly susceptible to extensive neurologic injuries and spinal deformities after cervical fractures from even minor traumatic forces. These injuries are uniquely complex, require careful imaging assessment, and aggressive surgical management to optimize spinal stability and functional outcomes.

**KEY WORDS :** Ankylosing spondylitis · Lower cervical spine fracture

## INTRODUCTION

Ankylosing spondylitis (AS) is a progressive, systemic inflammatory arthritic condition with a genetic disposition involving the HLA-B27 antigen in the majority of cases<sup>1</sup>. AS mainly affects the sacroiliac joints and spine. Spine involvement in AS is characterized by ossification of the ligaments, intervertebral discs, endplates, and apophyseal structures<sup>8</sup>. Thus, AS transforms the flexible spinal column into a stiff rod<sup>17</sup>.

The rigid spinal segment presents a long lever arm which is unable to accommodate various forces and is susceptible to injury in comparison to a normal spine<sup>15</sup>. AS is also associated with vertebral osteoporosis, which weakens the spine and contributes to the risk of injury<sup>9</sup>. Because of the brittle nature of the spine in patients with AS, the development of a fracture can occur with minor trauma or even unknown trauma<sup>10-13,18,19</sup>. These injuries often result in neurologic deficits that necessitate early diagnosis and treatment. Diagnosis can be difficult due to pre-existing spinal alterations. The con-

ventional radiographs are inadequate to fully evaluate fractures due to osteoporosis and the position of the shoulders.

The aim of this report was to present the surgical experience of lower cervical fractures occurring in patients with AS and to highlight the difficulties that exist with respect to the diagnosis and surgical management.

## CASE REPORT

A 53-year-old male with an unknown history of AS slipped and fell in a construction field striking his head and neck. Immediately after the accident he experienced posterior neck pain. The patient was first brought to a local clinic. No fractures or dislocation of the spine was detected on the conventional plain radiographs of the cervical, thoracic, and lumbar spine, although the typical radiographic features of AS were apparent.

Two days later, however, there was aggravation of the neck pain with quadriparesis below C6. The patient was transferred to our hospital with his neck fixed by a rigid cervical collar. In our emergency room, a neurologic examination was performed. Based on the standard classification of spinal cord injuries developed by the American Spinal Injury Association (ASIA)<sup>4</sup>, the strength of the key muscles of the upper limbs ranged from grade 2-3, and the strength of the key muscles of the lower limbs ranged from grade 0-1. The patient did not experience a deterioration of muscle strength during the

• Received : October 20, 2009 • Revised : December 24, 2009

• Accepted : June 10, 2010

• Address for reprints : Dae-Jean Jo, M.D.

Department of Neurosurgery, Spine Center, Kyung Hee University East-West Neo Medical Center, 149 Sangil-dong, Gangdong-gu, Seoul 134-727, Korea

Tel : +82-2-440-6147 Fax : +82-2-440-7494

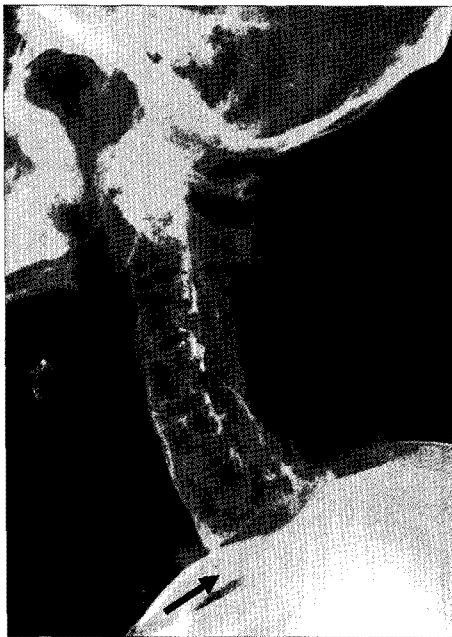E-mail : apuzzo@hanmail.net

hospital transfer. Hypoesthesia to pin pricking was noted below the C6 dermatome.

The conventional plain radiographs were carefully reviewed. The cervical spine radiographs revealed a displaced fracture with an obvious gap in the anterior column at C6-7 (Fig. 1). An emergent high resolution 3-dimensional (3D) CT scan and MRI confirmed the displaced fracture with anterior subluxation at the superior portion of the C7 vertebrae; the fracture line extended to the posterior element between C6 and 7 (Fig. 2). This injury resulted in narrowing of the spinal canal by the C6 lamina, C7 body, and posterior epidural hematoma with compression of the spinal cord (Fig. 2B).

As the neurologic deficits were slowly progressive, emergency surgical decompression of the spinal cord with internal fixation of the fracture was considered to be necessary to prevent further deterioration. He was treated surgically using combined anterior and posterior approaches of the cervical spine. The anterior approach was used for reduction of the displaced fracture with an anterior cervical interbody fusion by autologous iliac bone with plating at C6-7. The posterior approach was used for posterior stabilization and spinal cord decompression through complete C6 and C7 laminectomies. The posterior stabilization was achieved using lateral mass fixation between C4 and C6, and pedicle screw fixation at T1 and T2. Anatomic reduction and three-column rigid fixation was achieved. Intra-operatively, posterior autologous iliac bone grafting was performed (Fig. 3).

Because the combined anterior and posterior internal

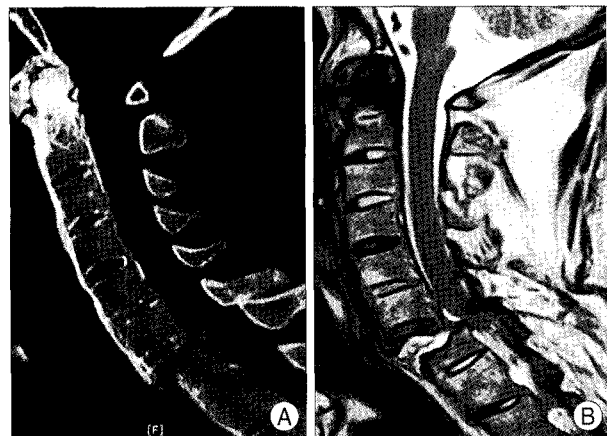


**Fig. 1.** Conventional lateral plain radiograph of cervical spine vaguely shows a displaced fracture together with an obvious gap (arrow) in the anterior column at C6-7 because the rigid elevation of the shoulders prevents adequate imaging at the cervico-thoracic junction.

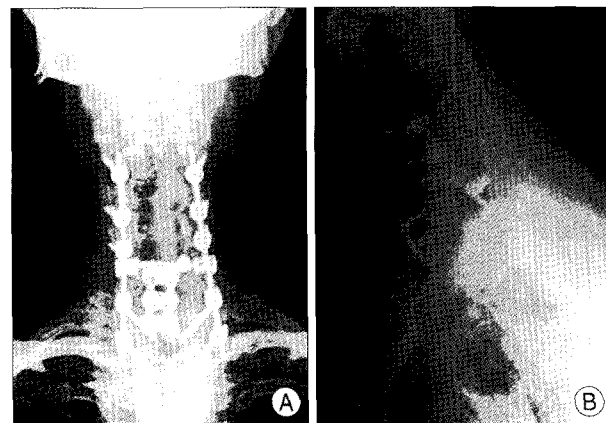
fixation had achieved immediate three-column stability in the operation, a post-operative halo-vest was placed with a rigid cervicothoracic brace for external immobilization. The muscle strength of key muscles of the upper limbs rapidly recovered to grade 4-5 by post-operative week 1. The lower limbs recovered to grade 2-3. Allodynia of the hands and hypoesthesia of the trunk had almost disappeared. He was transferred to the rehabilitation department on the 7th post-operative day, with an improvement in neurologic deficits to ASIA grade D.

## DISCUSSION

Greater than 50% of patients with AS will suffer from moderate-to-severe spinal restriction in the late stage of the disease, and they are usually complicated by vertebral osteo-



**Fig. 2.** These films show a displaced fracture with anterior subluxation at the superior portion of the C7 vertebrae, fracture line extended to the posterior element between C6-7, and narrowing the spinal canal by the C6 lamina, C7 body, and posterior epidural hematoma with compression of the spinal cord. A : High-resolution 3-dimensional (3D) computed tomography scan. B : Sagittal magnetic resonance T2-weighted image.



**Fig. 3.** Post-operative conventional radiographs of cervical spine show a anterior cervical iliac autograft with plating at C6-7 and the posterior stabilization using lateral mass fixation between C4 and C6, pedicle screw fixation at T1-2. A : Antero-posterior view. B : Swimmer's lateral view.

porosis because of prolonged immobilization<sup>2</sup>). In long-standing disease, ossification of the ligaments and joints of the involved spine occurs and leads to universal spinal syndesmophytosis. Spinal fractures are 3.5 times more common in AS patients than in the normal population<sup>6</sup>. Even in the face of minor external stress, the rigid and brittle fused spine is easily broken because of altered biomechanics, which leads to the spine behaving much like an osteoporotic long bone rather than an elastic spine<sup>5,17</sup>. The lower cervical spine is especially prone to such injuries because the protecting muscle is weak and the supporting paravertebral soft tissues are ossified<sup>6,14,16</sup>. Fractures tend to occur at the level of the intervertebral disc as a result of incomplete ossification of the nucleus pulposus, often allowing displacement<sup>11</sup>. Therefore, relatively minor accidents, such as a simple fall from standing, can lead to cervical fractures<sup>12,13</sup>. The lower cervical spine is the most commonly affected site in the patient with AS.

A fracture in AS always extends across all anterior and posterior elements. It most frequently occurs through the level of an ossified intervertebral disc, and is extremely unstable<sup>11,14,18</sup>. Fractures of the cervical spine in AS patients are accompanied by a high incidence of severe neurologic deficits and mortality<sup>12,13</sup>. Murray and Persellin<sup>10</sup> reported a 57% rate of severe neurologic deficits (quadriplegia and paraplegia), and a 35% mortality rate associated with vertebral fractures in AS patients (3 and 2 times more frequently than the normal population, respectively). The prognosis of severe neurologic deficits (quadriplegia or paraplegia) associated with vertebral fractures in AS patients is generally poor. Thus, early diagnosis and treatment of lower cervical spine fractures is very important in AS patients.

However, an early diagnosis of lower cervical spine fractures in patients with AS is often difficult to make. Because the lower cervical region is obscured by a rigid elevation of the shoulders, it is difficult to see on conventional plain radiographs<sup>7,14</sup>. Furthermore, osteoporotic changes make visualization of fractures more difficult, particularly in the presence of thin fracture lines. The latter, without any primary dislocation, can be missed in plain films<sup>9</sup>. The radiologic imaging of lower cervical spine fractures in patients with AS demands special attention since these injuries are frequently missed and the diagnosis is delayed<sup>3,5,14</sup>. Despite a high clinical suspicion, if conventional plain radiographs do not reveal any evidence of a spinal fracture, the use of high resolution 3D CT scan of the entire spinal column with sagittal reconstructed views, as in the current case, is clearly advantageous because of the increased sensitivity in documenting the fracture<sup>20</sup>.

The definitive treatment of cervical spine fractures in AS patients remains controversial with various treatment modal-

ities and various outcomes reported in the literature. AS is a systemic disease in which multiple organs are involved and great risks exist in surgery. In the past, patients with AS suffering from cervical fractures were treated conservatively, consisting of skull traction, a halo-vest, or head and chest casts. Skull traction cannot satisfactorily reduce or stabilize the cervical spine due to the stiff spine and the irreducible surrounding soft tissues. Neurologic deterioration has been reported as a result of distraction at the fracture site while applying traction<sup>12,13</sup>. Simple external fixation cannot eliminate the movement between the fracture sites, leading to pseudoarthroses<sup>6,13</sup>. Therefore, surgical treatment is an effective way to stabilize the vulnerable spine because it can offer direct decompression, and avoid complications caused by long-time traction and external fixation. Solid internal fusion cannot be achieved by simple anterior or posterior surgery. The failure rate of anterior internal fixation is 50% because anterior implants are unable to resist or absorb the tension from the posterior spinal column in three-column spinal injuries<sup>5</sup>.

Although simple posterior instrumented fusion is successful in some cases, single posterior fusion was prone to fail because there was too much stress on the posterior internal fixation without the anterior support<sup>18</sup>. For these reasons, the combined anterior and posterior approach should be a suitable method of stabilization in severely unstable injuries, particularly with a gap in the anterior column. Technically, posterior fixation must be performed with lateral mass screws from C3-6 and pedicle screws from C7-T2 in conjunction with plates or rods, including at least two segments above and below the fracture<sup>18</sup>. Because the cervical and upper thoracic spine is ankylosed, no motion is lost from multilevel fixation, whereas biomechanical resistance and therefore fracture healing is promoted. This type of approach should prevent delayed neurologic deficits, reduce the incidence of non-union, and allow early rehabilitation without external immobilization, restriction of respiratory excursion, and hence reduce the risk of pulmonary complications.

## CONCLUSION

Clinicians must be cautious in assessing patients with AS following any degrees of trauma despite the presence of initial negative imaging methods, not even neurologic deficits. The high resolution 3D CT scans may be helpful in demonstrating occult fractures patients with AS. The operative treatment of these injuries is useful and effective for these patients. Both anterior and posterior stabilization offer better support.

## References

1. Braun J, Bollow M, Remlinger G, Eggens U, Rudwaleit M, Distler A,

- et al. : Prevalence of spondylarthropathies in HLA-B27 positive and negative blood donors. *Arthritis Rheum* 41 : 58-67, 1998
2. Carette S, Grahan D, Little H, Rubenstein J, Rosen P : The natural disease course of ankylosing spondylitis. *Arthritis Rheum* 26 : 186-190, 1983
  3. Cornefjord M, Alemany M, Olerud C : Posterior fixation of subaxial cervical spine fractures in patients with ankylosing spondylitis. *Eur Spine J* 14 : 401-408, 2005
  4. Ditunno JF Jr, Young W, Donovan WH, Creasey G : The international standards booklet for neurological and functional classification of spinal cord injury. American Spinal Injury Association. *Paraplegia* 32 : 70-80, 1994
  5. Einsiedel T, Schmelz A, Arand M, Wilke HJ, Gebhard F, Hartwig E, et al. : Injuries of the cervical spine in patients with ankylosing spondylitis : experience at two trauma centers. *J Neurosurg Spine* 5 : 33-45, 2006
  6. Fox MW, Onofrio BM, Kilgore JE : Neurological complications of ankylosing spondylitis. *J Neurosurg* 78 : 871-878, 1993
  7. Geusens P, Vosse D, van der Linden S : Osteoporosis and vertebral fractures in ankylosing spondylitis. *Curr Opin Rheumatol* 19 : 335-339, 2007
  8. Kanter AS, Wang MY, Mummaneni PV : A treatment algorithm for the management of cervical spine fractures and deformity in patients with ankylosing spondylitis. *Neurosurg Focus* 24 : E11, 2008
  9. Koivikko MP, Kiuru MJ, Koskinen SK : Multidetector computed tomography of cervical spine fractures in ankylosing spondylitis. *Acta Radiol* 45 : 751-759, 2004
  10. Murray GC, Persellin RH : Cervical fracture complicating ankylosing spondylitis : a report of eight cases and review of the literature. *Am J Med* 70 : 1033-1041, 1981
  11. Olerud C, Frost A, Bring J : Spinal fractures in patients with ankylosing spondylitis. *Eur Spine J* 5 : 51-55, 1996
  12. Park YS, Kuh SU, Cho YE, Kim YS : Treatment of cervical cord injury in ankylosing spondylitis. *J Korean Neurosurg Soc* 34 : 389-392, 2003
  13. Rowed DW : Management of cervical spinal cord injury in ankylosing spondylitis : the intervertebral disc as a cause of cord compression. *J Neurosurg* 77 : 241-246, 1992
  14. Sapakas G, Kateros K, Papadakis SA, Galanakis S, Brilakis E, Machairas G, et al. : Surgical outcome after spinal fractures in patients with ankylosing spondylitis. *BMC Musculoskelet Disord* 10 : 96, 2009
  15. Samartzis D, Anderson DG, Shen FH : Multiple and simultaneous spine fractures in ankylosing spondylitis : case report. *Spine* 30 (Phila Pa 1976) : E711-E715, 2005
  16. Shen FH, Samartzis D : Cervical spine fracture in the ankylosing spondylitis patient. *J Am Coll Surg* 200 : 632-633, 2005
  17. Shen FH, Samartzis D : Surgical management of lower cervical spine fracture in ankylosing spondylitis. *J Trauma* 61 : 1005-1009, 2006
  18. Taggard DA, Traynelis VC : Management of cervical spinal fractures in ankylosing spondylitis with posterior fixation. *Spine* 25 (Phila Pa 1976) : 2035-2039, 2000
  19. Vosse D, Feldtkeller E, Erendsson J, Geusens P, van der Linden S : Clinical vertebral fractures in patients with ankylosing spondylitis. *J Rheumatol* 31 : 1981-1985, 2004
  20. Wintermark M, Mouhsine E, Theumann N, Mordasini P, van Melle G, Leyvaz PF, et al. : Thoracolumbar spine fractures in patients who have sustained severe trauma : depiction with multi-detector row CT. *Radiology* 227 : 681-689, 2003