

Consideration of Lateral Cortical Bone Thickness and IAN Canal Location During Mandibular Ramus Bone Grafting for Implant Placement

Nam-Hoon Lee, Joo-Young Ohe, Baek-Soo Lee, Yong-Dae Kwon,
Byung-Joon Choi, Sung-Moon Bang

Department of Oral and Maxillofacial Surgery, Kyung Hee University School of Dentistry (KHUSD),
Seoul, Korea

Corresponding Author

Joo-Young Ohe, DDS

Department of Oral and Maxillofacial Surgery, School of Dentistry, KyungHee University
1 Heogi-dong, Dongdaemun-gu, Seoul 130-702, Korea
TEL: +822-958-9440 FAX: +822-966-4572 E-mail: ojyoung81@hanmail.net

Received for publication Oct 29, 2010; returned after revision Nov 29, 2010;
Accepted for publication Nov 30, 2010

• Abstract

Purpose: This study aimed at examining the thickness of lateral cortical bone in the mandibular posterior body and the location of the inferior alveolar nerve canal as well as investigating the clinically viable bone grafting site(s) and proper thickness of the bone grafts.

Subjects and Methods: The study enrolled a total of 49 patients who visited the Department of Oral and Maxillofacial Surgery at Kyung Hee University Dental Hospital to have their lower third molar extracted and received cone beam computed tomography (CBCT) examinations. Their CBCT data were used for the study. The thickness of lateral cortical bone and the location of inferior alveolar nerve canal were each measured from the buccal midpoint of the patients' lower first molar to the mandibular ramus area in the occlusal plane of the molar area.

Results: Except in the external oblique ridge and alveolar ridge, all measured areas exhibited the greatest cortical bone thickness near the lower second molar area and the smallest cortical bone thickness in the retromolar area. The inferior alveolar nerve canal was found to be located in the innermost site near the lower second molar area compared to other areas. In addition, the greatest thickness of the trabecular bone was found between the inferior alveolar nerve canal and the lateral cortical bone.

Conclusions: In actual clinical settings involving bone harvesting in the posterior mandibular body, clinicians are advised to avoid locating the osteotomy line in the retromolar area to help protect the inferior alveolar nerve canal from damage. Harvesting the bone near the lower second molar area is judged to be the proper way of securing cortical bone with the greatest thickness.

• Key word : cortical bone thickness, inferior alveolar nerve, ramus bone graft

• J Kor Dent Sci. 2010; 3(2) : 4 - 11

I. Introduction

Alongside the growing number of cases of prosthetic treatment of edentulous patients in recent years have been the increasing demands for bone grafting procedure to rebuild the edentulous space in the mandible and restore the damaged area surrounding implants. If the damaged area is limited, bone substitutes such as allogeneic bone and xenogenic bone can be used. If the defective area is extensive, autogenous bone grafting is considered mandatory. Autogenous bone is the only grafting material¹⁾ with all of the bone conduction, induction, and formation abilities. The bone triggers no immune response from the host and shows minimized resorption by osteoclasts²⁾. In addition, a number of studies using autogenous bone grafting followed by titanium mesh implementation have reported success rates matching those of the existing bone. Based on research findings, autogenous bone grafting remains the best method available for mandibular reconstruction³⁻⁸⁾. Its benefits notwithstanding, the autogenous procedure is not without weaknesses, e.g., technical difficulties, time consumption, post-surgical complications in the operated area, and constraints in the size and adequacy of bone grafts. However, these problems are promoting research and development in synthetic bone substitutes.

In most cases, harvesting autogenous bone grafts in implant treatment is carried out through the oral cavity particularly from the mandibular symphysis, mandibular ramus, and maxillary tuberosity. Harvesting grafts from areas other than the oral cavity involves the iliac bone. However, this approach is used less frequently than the oral-cavity approach because it requires high costs, changes in ambulation status, outpatient care, and general anesthesia. In performing bone grafting from the mandibular symphysis or mandibular ramus, large bone blocks are mostly harvested; maxillary tuberosity is used in most cases when harvesting crushed autogenous cartilage grafts. Harvesting bone blocks from the mandibular ramus causes fewer post-surgical complications than harvesting from the mandibular symphysis. In addition, patients tend not to be stressed out with bone harvesting carried out from the ramus, and they complain less frequently of abnormal sensory experiences occurring in the posterior buccal cartilages compared to the sensory abnormalities felt in the labium and jaw

following bone harvesting from the symphysis.

Incision made along the external oblique ridge could damage the buccal nerve, but it results in almost no sensory loss in the buccal mucosa following surgery; moreover, patients hardly ever feel the loss, if any. Contrary to the sensory abnormalities in the teeth of the mandibular symphysis donor area, no reports have been made regarding such abnormalities in the molars. The molar area requires no reconstruction as well.

In terms of bone shape, the mandibular ramus is a good candidate for the veneer bone graft procedure in horizontal bone loss cases⁹⁾. In a study by Misch, et al¹⁰⁾, viable bone harvesting areas in the mandibular ramus include roughly two areas: the ascending ramus of the mandible and the posterior mandibular body. When performing in the oral cavity under local anesthesia, the posterior mandibular body offers easier access to surgeons, causes fewer complications such as swelling and bleeding, and allows the harvesting of adequately sized bone grafts to restore a damaged area involving 1 or 2 teeth (Fig. 1). Thus, the strengths of using bone grafts harvested from the posterior mandibular body have made this type of bone grafting a favored technique among dental surgeons, with a growing number of cases reported. Although many studies have been conducted on the thickness of cortical bone in the posterior mandibular body and related complications, little research has been done on the direct association between said cortical bone and the inferior alveolar nerve canal.

This study aimed at examining the thickness of lateral cortical bone in the posterior mandibular body and the location of inferior alveolar nerve canal in the area spanning the lower first molar to the mandibular ramus in the plane of occlusion via CBCT tests conducted at the Department of Oral and Maxillofacial Surgery at Kyung Hee University Dental Hospital. It also sought to investigate bone grafting locations and proper thickness of bone grafts that are clinically viable.

II. Subjects and Methods

A. Subjects

This study used the CT scan data of 49 patients who were treated at the Department of Oral and Maxillofacial Surgery at Kyung Hee University Dental Hospital where they

underwent the extraction of their lower third molar and received cone beam computed tomography (CBCT) tests. The subjects' ages ranged from 17 to 54 years, with 26.71 ± 8.46 years as the mean age. Among the 49 patients, 20 were male and 29 were female. The subjects included the cohort with their lower third molar impacted and the cohort with their lower third molar erupted. Exclusion criteria included individuals with extended lesions found in the lateral cortical bone due to inflammation or cyst in the crown or root of their lower third molar, those showing displacement of their inferior alveolar nerve (IAN) canal, or those with missing lower third molar.

B. Methods

1) CBCT examination and analysis

For the CBCT examination, an Alphard Vega (Asahi Co., Japan) CT scanner was used to photograph the anterior and posterior areas of the patients' lower left or right third molar. The CT scans were converted into a series of files in digital imaging communication in medicine (DICOM) format and were then stored. Afterward, the files were reconstructed using the Ondemand3D (Cybermed Co., Korea) program to allow the measurement and analysis of the scan data.

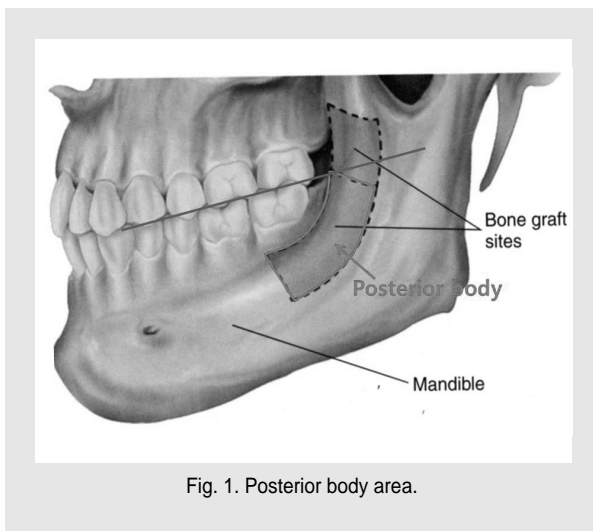


Fig. 1. Posterior body area.

Nam-Hoon Lee et al : Consideration of Lateral Cortical Bone Thickness and IAN Canal Location During Mandibular Ramus Bone Grafting for Implant Placement. J Kor Dent Sci 2010.

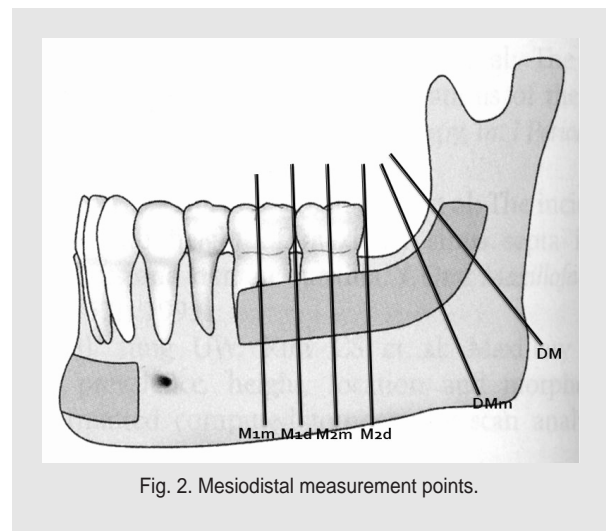


Fig. 2. Mesiodistal measurement points.

Nam-Hoon Lee et al : Consideration of Lateral Cortical Bone Thickness and IAN Canal Location During Mandibular Ramus Bone Grafting for Implant Placement. J Kor Dent Sci 2010.

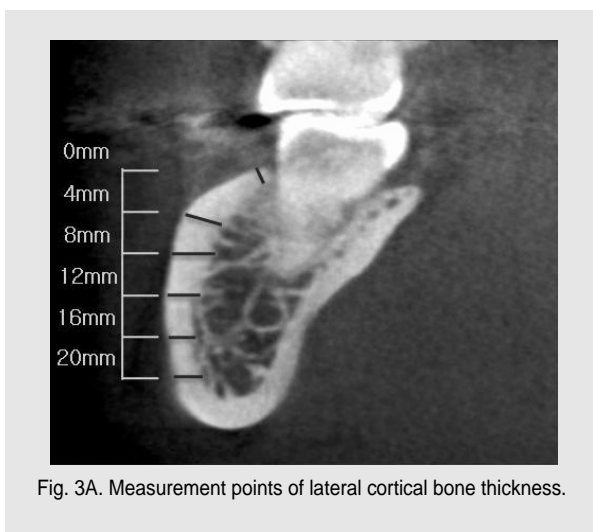


Fig. 3A. Measurement points of lateral cortical bone thickness.

Nam-Hoon Lee et al : Consideration of Lateral Cortical Bone Thickness and IAN Canal Location During Mandibular Ramus Bone Grafting for Implant Placement. J Kor Dent Sci 2010.

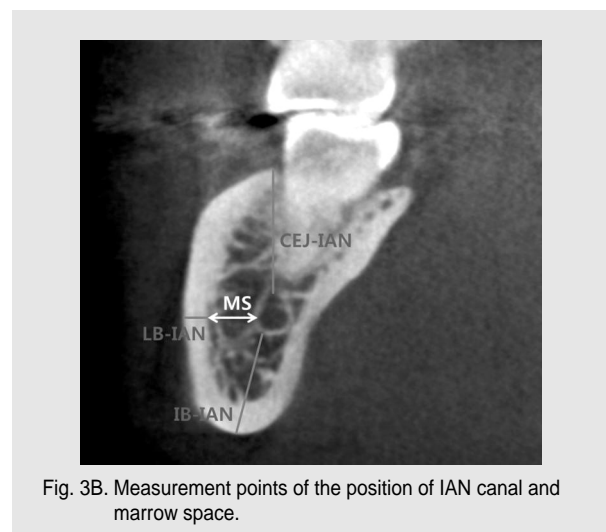


Fig. 3B. Measurement points of the position of IAN canal and marrow space.

Nam-Hoon Lee et al : Consideration of Lateral Cortical Bone Thickness and IAN Canal Location During Mandibular Ramus Bone Grafting for Implant Placement. J Kor Dent Sci 2010.

2) Measurement items

Mesiodistally, six measurement points were decided as follows (Fig. 2):

- ① M1m: mid-buccal point of Mn. 1st molar
- ② M1d: disto-buccal point of Mn. 1st and 2nd molars
- ③ M2m: mid-buccal point of Mn. 2nd molar
- ④ M2d: disto-buccal point of Mn. 2nd molar
- ⑤ DM: lateral oblique ridge of molar occlusal level
- ⑥ DMm: mid-buccal point between M2d and DM

From each of the aforesaid points, a cross section forming perpendicularity to the alveolar ridge or the external oblique ridge was obtained. Then, on the cross section, and with the alveolar ridge serving as the reference structure, a total of 6 points were marked every 4 mm up to the 20 mm point under the alveolar ridge; the thickness of the lateral cortical bone was then measured (Fig. 3A).

In addition, the researchers measured the following on the cross section: (a) CEJ-IAN, which is the distance between the superior border of IAN to the cementoenamel junction (CEJ); (b) LB-IAN, the distance between IAN's lateral border to the lateral rim of the mandible; (c) IB-IAN as the distance between IAN's inferior border to the mandible's inferior rim, and; (d) marrow space (MS), which is the distance between IAN's lateral border to the inner rim of the lateral cortical bone in the mandible (Fig. 3B).

3) Statistical analysis

For each of the aforesaid measurement items, oneway ANOVA test was performed using the PASW program

(SPSS ver. 18.0 KO for windows) to conduct statistical analyses of the changes occurring in the thickness of lateral cortical bone and in the location of the IAN canal at each measurement point. The Scheffe test was also conducted for post-hoc analysis.

III. Results

A. Changes in lateral cortical bone thickness at each measurement point (Fig. 4 and Table 1)

- ① At the 0 mm site in the inferior area of the alveolar ridge, DM showed the greatest thickness with $5.68 \text{ mm} \pm 1.40 \text{ mm}$, whereas M1m exhibited the smallest thickness with $1.36 \text{ mm} \pm 0.31 \text{ mm}$.
- ② At the 4 mm site in the inferior area of the alveolar ridge, DM was found to have the greatest thickness with $3.31 \text{ mm} \pm 0.70 \text{ mm}$; M1m had the smallest thickness with $2.12 \text{ mm} \pm 0.59 \text{ mm}$.
- ③ At the 8 mm site in the inferior area of the alveolar ridge, M2d was thickest with $3.15 \text{ mm} \pm 0.43 \text{ mm}$; M1m was thinnest with $2.69 \text{ mm} \pm 0.52 \text{ mm}$.
- ④ At the 12 mm site in the inferior area of the alveolar ridge, M1d had the thickest cortical bone with $2.90 \text{ mm} \pm 0.46 \text{ mm}$, with DM having the thinnest cortical bone with $2.63 \text{ mm} \pm 0.45 \text{ mm}$.
- ⑤ At the 16 mm site in the inferior area of the alveolar ridge, M1d exhibited the greatest thickness with $2.55 \text{ mm} \pm 0.40 \text{ mm}$, whereas DM showed the smallest thickness with $2.37 \text{ mm} \pm 0.45 \text{ mm}$.

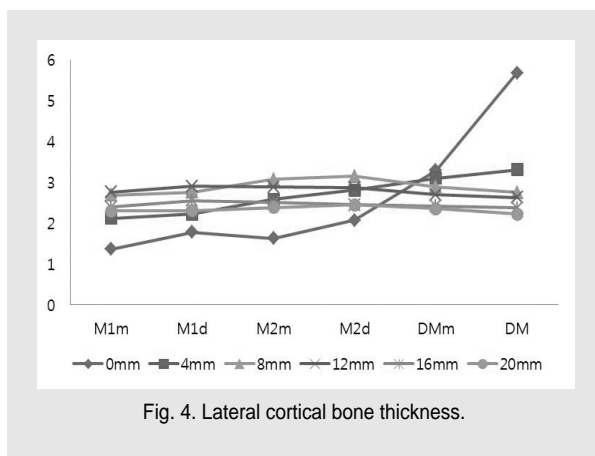


Fig. 4. Lateral cortical bone thickness.

Nam-Hoon Lee et al : Consideration of Lateral Cortical Bone Thickness and IAN Canal Location During Mandibular Ramus Bone Grafting for Implant Placement. J Kor Dent Sci 2010.

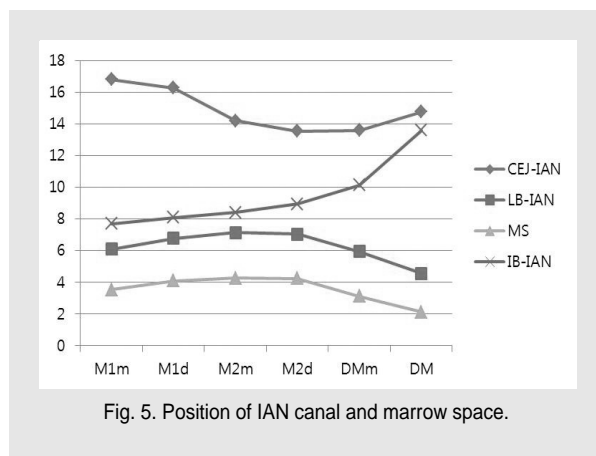


Fig. 5. Position of IAN canal and marrow space.

Nam-Hoon Lee et al : Consideration of Lateral Cortical Bone Thickness and IAN Canal Location During Mandibular Ramus Bone Grafting for Implant Placement. J Kor Dent Sci 2010.

- ⑥ At the 20 mm site in the inferior area of the alveolar ridge, M2d was found to be thickest with 2.45 mm ± 0.44 mm; DM was found to thinnest with 2.22 mm ± 0.42 mm.
- ⑦ At the 0 mm, 4 mm, 8 mm, and 12 mm sites in the inferior area of the alveolar ridge, statistically significant differences in bone thickness were found according to the mesiodistal area (p value < 0.05). At the 16 mm and 20 mm sites in the inferior area of the alveolar ridge, however, no statistically significant differences in bone thickness were found mesiodistally (p value > 0.05).

B. Changes in IAN canal location at each measurement point (Fig. 5 and Table 2)

- ① CEJ-IAN was found to be longest at M1m (16.80 mm ± 2.10 mm) and shortest at M2d (13.54 mm ± 1.82 mm).
- ② LB-IAN was longest at M2m^v (7.13 mm ± 1.51 mm) and shortest at DM (4.54 mm ± 1.31 mm).
- ③ MS was found to be 4.27 mm ± 1.51 mm at M2m -- which was the longest -- and 2.11 mm ± 1.23 mm at DM, which was the shortest.
- ④ IB-IAN was longest at DM (13.59 mm ± 2.90 mm) and shortest at M1m (7.69 mm ± 1.79 mm).

- ⑤ CEJ-IAN, LB-IAN, MS, and IB-IAN all showed statistically significant differences in the changes of IAN canal location mesiodistally (p value < 0.05).

IV. Discussion

Autogenous bone graft remains the only bone grafting material capable of bone formation¹⁾. The trabecular bone in autogenous bone grafts in particular has various growth factors such as osteocytes and bone morphogenetic proteins (BMPs) in large quantities, leading to the formation of new bone tissues in the grafting site. On the other hand, cortical bone exhibits little or no bone resorption following bone grafting; it is excellent in maintaining a space for new bone tissues to grow and settle²⁾. In sum, autogenous bone grafting is safe against osteoclast-induced resorption and immune responses and is excellent in helping new bone tissues form.

The procedure involving autogenous grafting using the mandibular ramus followed by titanium mesh plate-based procurement and maintenance of bone-grafted space is known to help minimize the resorption that could occur

Table 1. Lateral cortical bone thickness (Oneway ANOVA; *p<0.05)

	Thickness (mm)					
	0mm	4mm	8mm	12mm	16mm	20mm
M1m	1.36 ± 0.31	2.12 ± 0.59	2.69 ± 0.52	2.76 ± 0.44	2.39 ± 0.36	2.30 ± 0.35
M1d	1.78 ± 0.61	2.22 ± 0.55	2.76 ± 0.50	2.90 ± 0.46	2.55 ± 0.40	2.31 ± 0.39
M2m	1.63 ± 0.56	2.58 ± 0.44	3.07 ± 0.42	2.88 ± 0.43	2.51 ± 0.38	2.38 ± 0.43
M2d	2.07 ± 0.69	2.81 ± 0.46	3.15 ± 0.43	2.87 ± 0.45	2.45 ± 0.40	2.45 ± 0.44
DMm	3.29 ± 1.00	3.10 ± 0.59	2.89 ± 0.51	2.70 ± 0.45	2.42 ± 0.40	2.36 ± 0.41
DM	5.68 ± 1.40	3.31 ± 0.70	2.75 ± 0.46	2.63 ± 0.45	2.37 ± 0.45	2.22 ± 0.42
total	2.64 ± 1.71	2.69 ± 0.71	2.88 ± 0.50	2.79 ± 0.45	2.45 ± 0.40	2.34 ± 0.41
p-value	0.000*	0.000*	0.000*	0.011*	0.177	0.108

Nam-Hoon Lee et al : Consideration of Lateral Cortical Bone Thickness and IAN Canal Location During Mandibular Ramus Bone Grafting for Implant Placement. J Kor Dent Sci 2010.

Table 2. Position of IAN canal and marrow space (Oneway ANOVA; *p<0.05)

	Distance (mm)			
	CEJ-IAN	LB-IAN	MS	IB-IAN
M1m	16.80 ± 2.10	6.08 ± 1.17	3.53 ± 1.23	7.69 ± 1.79
M1d	16.26 ± 2.18	6.78 ± 1.46	4.08 ± 1.50	8.08 ± 2.01
M2m	14.20 ± 1.87	7.13 ± 1.51	4.27 ± 1.51	8.39 ± 2.20
M2d	13.54 ± 1.82	7.04 ± 1.72	4.24 ± 1.69	8.94 ± 2.19
DMm	13.58 ± 2.13	5.93 ± 1.75	3.12 ± 1.64	10.13 ± 2.28
DM	14.75 ± 2.16	4.54 ± 1.31	2.11 ± 1.23	13.59 ± 2.90
total	14.86 ± 2.39	6.25 ± 1.73	3.56 ± 1.65	9.47 ± 3.00
p-value	0.000*	0.000*	0.000*	0.000*

Nam-Hoon Lee et al : Consideration of Lateral Cortical Bone Thickness and IAN Canal Location During Mandibular Ramus Bone Grafting for Implant Placement. J Kor Dent Sci 2010.

after autogenous bone grafting^{3,5,6}. When the recipient site and grafting site are adjoined, this procedure can shorten the time required for performing the procedure and anesthesia. Despite its benefits, autogenous bone grafting using the mandibular ramus poses risks of pain, swelling, post-surgical bleeding, IAN damages, and other complications¹¹. However, pain, swelling, and post-surgical bleeding are an unavoidable part of dental surgical complications, and IAN damages following bone grafting occur very rarely. In their study of the complications that could occur after bone grafting using the retromolar area in the mandible, Nkenke, et al¹² reported that damages in IAN showed no statistically significant differences, and that the ability of patients to open their mouth before and after surgery showed no statistically significant correlation. The researchers also reported that their examination and comparison of bone density in the recipient site showed no statistically significant differences before the surgery vs. 6 months after the surgery. In addition, the results of the visual analogue scale (VAS) tests they conducted revealed that the patients experienced greater discomfort during the implant placement treatment (4.1 ± 2.0) than in the bone grafting procedure (2.8 ± 1.0).

In general, cortical bone graft harvested in the posterior molar area of the mandible is measured to be 3.0 ~ 3.5 mm thick¹³. In their cadaveric study, Rajchel, et al¹⁴ reported that the thickness of cortical bone graft in the lateral mandibular canal in the lower second molar area was $2.3 \text{ mm} \pm 0.7 \text{ mm}$, and that the lower first molar area had the greatest thickness with 2.9 mm. Their findings show only minor differences with the findings of previous studies, i.e., the greatest thickness was measured in the lower second molar's lateral cortical bone. Rajchel and his colleagues also reported the average thickness of lateral cortical bone grafts to be 1.92 mm, 2.8 mm in the dentulous mandible, and 2.5 mm in the edentulous mandible. According to Katranji, et al¹⁵ who conducted a cadaveric study to examine the thickness of lateral cortical bone in the lower molar area, the mean thickness of the bone in the dentulous mandible was found to be $1.98 \text{ mm} \pm 0.81 \text{ mm}$, and $2.06 \text{ mm} \pm 0.69 \text{ mm}$ in the edentulous mandible. Jack-min, et al¹⁶ also performed a

cadaveric study wherein they measured the thickness of the lower molar area's lateral cortical bone to be $2.76 \text{ mm} \pm 0.13 \text{ mm}$ in the dentulous mandible and $2.52 \text{ mm} \pm 0.32 \text{ mm}$ in the edentulous mandible.

As summarized above, there have been a number of studies that examined the thickness of lateral cortical bone in the lower molar area. In contrast, relatively few studies have been conducted on the location of the IAN canal and on the trabecular bone in the lateral side of the canal. Considering how commonly cortical bone grafts are used in bone grafting in the lower molar area, it would be equally imperative for researchers to evaluate the location of the IAN canal and the thickness of trabecular bone on the lateral side of the IAN canal to protect the canal against direct damages.

In this study, lateral cortical bone thickness was measured to be greatest at the DM point in the alveolar ridge and at the 4 mm site under the alveolar ridge. Likewise, bone thickness tended to increase from the first molar area toward the posterior area. Such tendency is judged to be attributable to the fact that the external oblique ridge in the retromolar area is thicker than the alveolar ridge in the molar area. In addition, the thickness was found to be greatest at the M2d point at the 8 mm and 20 mm sites under the alveolar ridge and at M1d at the 12 mm and 16 mm sites in the same area. In addition, DM at the 12 mm, 16 mm, and 20 mm sites under the alveolar ridge was observed to be the point where bone thickness was smallest. Except for areas adjacent to the external oblique and alveolar ridges, the 8 mm, 12 mm, 16 mm, and 20 mm sites under the alveolar ridge near the lower second molar area showed the lateral cortical bone thickness to be greatest.

In this study, the researchers' examination of the distance between CEJ and IAN canal revealed statistically significant differences at each point but no clinically significant results. Nevertheless, there were significantly interesting findings regarding the distance between the IAN canal and the lateral rim of the mandible as well as the thickness of trabecular bone in the IAN canal's lateral side. First, said distance at the M2m point was measured to be greatest with $7.13 \text{ mm} \pm 1.51 \text{ mm}$, whereas the distance at the DM point was measured to be smallest

with $4.54 \text{ mm} \pm 1.31 \text{ mm}$. Across the measurement points, the distance was found to be greatest at M2m, which was in the mid-section of the second molar. From M2m, the farther toward the anterior or posterior area, the smaller the distance became. In fact, the figure for the DM point in the retromolar area was significantly small.

Second, the examination of thickness of trabecular bone on the lateral side of the IAN canal revealed the thickness to be greatest at M2m ($4.27 \text{ mm} \pm 1.51 \text{ mm}$) and smallest at DM ($2.11 \text{ mm} \pm 1.23 \text{ mm}$). The thickness results showed the same pattern as that found in the distance between the IAN canal and the lateral rim of the mandible. This indicates that the nerve canal is found in the innermost location in the lower second molar area, and that the trabecular bone on the lateral side of the IAN canal in the same area is thickest compared to other areas. The findings also suggest that when harvesting bone grafts in the posterior mandibular body, surgeons would minimize damage to the IAN canal by making the osteotomy line on the lateral side of the lower second molar. Surgeons would also obtain the thickest cortical bone on the lateral side of the lower second molar.

The retromolar area including the lower third molar has thinner lateral cortical bone and IAN canal located laterally. Thus, making the osteotomy line in said area will likely damage the IAN canal. Surgeons should accordingly avoid making the osteotomy line in the lower third molar's posterior area during bone-harvesting from the posterior mandibular body. Instead, they should use the lateral cortical bone in the lower second molar area.

As for the distance between the IAN canal and the inferior rim of the mandible, the distance was found to be greatest at DM ($13.59 \text{ mm} \pm 2.90 \text{ mm}$) and shortest at M1m ($7.69 \text{ mm} \pm 1.79 \text{ mm}$). The distance showed a tendency to grow smaller when traveling from DM toward the anterior area. The tendency indicates that the nerve canal gradually descends toward the inferior area as it goes from the ascending ramus toward the anterior area. In addition, the decreasing size of the mandible itself is at work, affecting said tendency.

V. Conclusions

For this study, a total of 49 patients were enrolled at the Department of Oral and Maxillofacial Surgery at Kyung Hee University Dental Hospital to have their lower third molar extracted. Using the patients' CBCT test data, analysis was performed on the thickness of lateral cortical bone in the mandible as measured in the posterior mandibular body and the location of the inferior alveolar nerve (IAN) canal. The results of the analysis are summarized below.

1. In the alveolar ridge and the external oblique ridge, the thickness of the cortical bone increased from the molar area toward the retromolar area.
2. In the area spanning the 8 mm site under the alveolar ridge to the 20 mm site under the alveolar ridge, the lateral cortical bone near the second molar was found to be thickest. The thickness was found to be smallest in the retromolar area.
3. The IAN canal was found in the innermost site near the second molar area where the width of the trabecular bone in the IAN canal's lateral area was found to be greatest. In contrast, the nerve canal was found in the outermost site in the retromolar area where the width of the trabecular bone in the IAN canal's lateral area was found to be smallest.
4. In actual clinical situations involving bone harvesting in the posterior mandibular body, surgeons should avoid making an osteotomy line in the retromolar area to prevent damages to the IAN canal. Surgeons could secure the thickest cortical bone by harvesting bone grafts near the lower second molar area.
5. The thickness of lateral cortical bone was found to be greatest with $3.15 \text{ mm} \pm 0.43 \text{ mm}$ and $3.07 \text{ mm} \pm 0.42 \text{ mm}$ in the disto-buccal site of the second molar area and at the 8 mm site under the alveolar ridge in the central buccal area, respectively. Bone thickness in all the other measurement points was less than 3.0 mm, indicating that securing cortical bone grafts at least 3 mm thick during bone harvesting in the posterior mandibular body could be challenging.

References

1. Parikh SN. Bone graft substitutes: past, present, future. *J Postgrad. Med.* 2002;48(2):142-8.
2. Cordaro L, Amade DS, Cordaro M. Clinical results of alveolar ridge augmentation with mandibular block bone grafts in partially edentulous patients prior to implant placement. *Clin Oral Implants Res.* 2002;13(1):103-11.
3. Rocuzzo M, Ramieri G, Spada MC, Bianchi SD, Berrone S. Vertical alveolar ridge augmentation by means of a titanium mesh and autogenous bone grafts. *Clin Oral Implants Res.* 2004;15(1):73-81.
4. D'Addona A, Nowzari H. Intramembranous autogenous osseous transplants in aesthetic treatment of alveolar atrophy. *Periodontol* 2000;27:148-61.
5. von Arx T, Wallkamm B, Hardt N. Localized ridge augmentation using a micro titanium mesh: a report on 27 implants followed from 1 to 3 years after functional loading. *Clin Oral Implants Res.* 1998;9(2):123-30.
6. Rocuzzo M, Ramieri G, Bunino M, Berrone S. Autogenous bone graft alone or associated with titanium mesh for vertical alveolar ridge augmentation: a controlled clinical trial. *Clin Oral Implants Res.* 2007;18(3):286-94.
7. Triplett RG, Schow SR. Autologous bone grafts and endosseous implants: complementary techniques. *J Oral Maxillofac Surg.* 1996;54(4):486-94.
8. Jensen J, Sindet-Pedersen S, Oliver AJ. Varying treatment strategies for reconstruction of maxillary atrophy with implants: results in 98 patients. *J Oral Maxillofac Surg.* 1994;52(3):210-6.
9. Gungormus M, Yavuz MS. Ascending ramus of the mandible as a donor site in maxillofacial bone grafting. *J Oral Maxillofac Surg.* 2002;60(11):1316-8.
10. Misch CM. Ridge augmentation using mandibular ramus bone grafts for the placement of dental implants: presentation of technique *Pract Periodontics Aesthet Dent.* 1996;8(2):127-35.
11. Clavero J, Lundgren S. Ramus or chin grafts for maxillary sinus inlay and local onlay augmentation: comparison of donor site morbidity and complications. *Clin Implant Dent Relat Res.* 2003;5(3):154-60.
12. Nkenke E, Radespiel-Troger M, Wiltfang J, Schultze-Mosgau S, Winkler G, Neukam FW. Morbidity of harvesting of retromolar bone grafts: a prospective study. *Clin Oral Implants Res.* 2002;13(5):514-21.
13. Smith BR, Rajchel JL, Waite DE, Read L. Mandibular anatomy as it relates to rigid fixation of the sagittal ramus split osteotomy. *J Oral Maxillofac Surg.* 1991;49(3):222-6.
14. Rajchel J, Ellis E, Fonseca RJ. The anatomical location of the mandibular canal: its relationship to the sagittal ramus osteotomy. *Int J Adult Orthodon Orthognath Surg* 1986;1(1):37-47.
15. Katranji A, Misch K, Wang HL. Cortical bone thickness in dentate and edentulous human cadavers. *J Periodontol.* 2007;78(5):874-8.
16. Jack-Min Leong D, Li J, Moreno I, Wang HL. Distance between external cortical bone and mandibular canal for harvesting ramus graft: a human cadaver study. *J Periodontol.* 2010;81(2):239-43.