

Conventional Anchorage Reinforcement vs. Orthodontic Mini-implant: Comparison of Posterior Anchorage Loss During the En Masse Retraction of the Upper Anterior Teeth

Seung-Hak Baek, DDS, MSD, PhD¹, Young-Ho Kim, DDS, MS, PhD²

1. Chairman and Associate Professor, Department of Orthodontics, School of Dentistry, Dental Research Institute, Seoul National University, Seoul, Korea
2. Chairman and Associate Professor, Department of Orthodontics, Institute of Oral Health Science, Samsung Medical Center, Sungkyunkwan University School of Medicine, Seoul, Korea

Corresponding Author

Young-Ho Kim

Chairman and Associate Professor

Department of Orthodontics, Institute of Oral Health Science

Samsung Medical Center, Sungkyunkwan University School of Medicine

#50 Irwon-dong, Gangnam-Gu, Seoul 135-710, Korea

TEL : +82 2 3410 2425 FAX : +82 2 3410 0038 E-mail : huyyoung@skku.edu

Received for publication Sep 29, 2009; returned after revision Mar 5, 2010;
Accepted for publication Mar 16, 2010

• Abstract

This study sought to compare the amounts of posterior anchorage loss during the en masse retraction of the upper anterior teeth between orthodontic mini-implant (OMI) and conventional anchorage reinforcement (CAR) such as headgear and/or transpalatal arch. The subjects were 52 adult female patients treated with sliding mechanics (MBT brackets, .022" slot, .019X.025" stainless steel wire, 3M-Unitek, Monrovia, CA, USA). They were allocated into Group 1 (N=24, Class I malocclusion (CI), upper and lower first premolar (UP1LP1) extraction, and CAR), Group 2 (N=15, CI, UP1LP1 extraction and OMI), and Group 3 (N=13, Class II division 1 malocclusion, upper first and lower second premolar extraction, and OMI). Lateral cephalograms were taken before (T0) and after treatment (T1). A total of 11 anchorage variables were measured. Analysis of variance was used for statistical analysis. There was no significant difference in treatment duration and anchorage variables at T0 among the three groups. Groups 2 and 3 showed significantly larger retraction of the upper incisor edge (U1E-sag, 9.3mm:7.3mm, P<.05) and less posterior anchorage loss (U6M-sag, 0.7~0.9mm:2mm, P<.05; U6A-sag, 0.5mm:2mm, P<.01) than Group 1. The ratio of retraction amount of the upper incisor edge per 1 mm of anchorage loss in the upper molar made for the significant difference between Groups 1 and 2 (4.6mm:7.0mm, P<.05). Group 3 showed a relatively distal inclination of the upper molar (P<.05) and the intrusion of the upper incisor and first molar (U1E-ver, P<.05; U6F-ver, P<.05) compared to Groups 1 and 2. Although OMI could not shorten the treatment duration, it could provide better maximum posterior anchorage than CAR.

• Key word : conventional anchorage reinforcement, orthodontic mini-implant, posterior anchorage loss

• J Kor Dent Sci. 2010; 3(1) : 5 - 10

Introduction

The most common way of reducing lip protrusion and straightening the patient's profile is orthodontic treatment with the extraction of the upper and lower first premolars and retraction of the anterior segments under maximum anchorage^{1,2,3}. Traditionally, conventional anchorage reinforcement (CAR) such as headgear (HG) and/or transpalatal arch (TPA) has been used for this purpose.

Maximum anchorage means less than 25 per cent of space closure in the extraction space via posterior anchorage loss⁴. Therefore, an accurate prediction of the amount of anchorage loss during the retraction of the anterior teeth is critical in determining both treatment planning and selection of the appropriate mechanics.

Recently, there has been a dramatic increase in the use of orthodontic mini-implant (OMI; also known as temporary anchorage device) to allow maximum anchorage, to decrease the need for patient compliance, and to simplify the treatment procedure further⁵⁻¹².

There have been several reports on the success rate of OMI^{9,10,12}. Although the superiority of OMI to CAR in terms of posterior anchorage preservation during canine retraction has been reported^{13,14}, there are few reports on the degree of posterior anchorage loss with OMI during the en masse retraction of the anterior teeth. Therefore, this study sought to compare the anchorage loss of the posterior teeth and amount of retraction of the anterior teeth in Class I and Class II division 1 malocclusion patients with lip protrusion and minimal crowding between CAR and OMI.

Materials and methods

The initial subjects were 125 adult female patients (mean age= 23.32 years, range: 18~35 years) with Class I or Class II division 1 malocclusion with lip protrusion and minimal crowding and who needed maximum posterior anchorage. Based on the following criteria, the final samples were selected:

- Gender and age: Women older than 17 years to eliminate the potential influence of gender and age
- Skeletal and dental condition: Class I or Class II molar relationship, normal overbite (>0mm, <4 mm), labioversed upper incisor (U1 to palatal plane>105°), and less than 4 mm crowding in each arch

- Soft tissue profile: lip protrusion (lower lip to Ricketts' aesthetic line>2mm)
- Treatment method
 - Fixed appliance and archwire: MBT brackets (.022" slot, 3M-Unitek, Monrovia, CA, USA) with .019X.025 inch stainless steel wire for the en masse retraction of the upper anterior teeth
 - In Class I malocclusion cases, extraction of the upper and lower first premolars, CAR such as HG and/or TPA, and sliding mechanics described in the MBT technique¹⁵⁻¹⁷ were used.
 - In Class II division 1 malocclusion cases, extraction of the upper first and lower second premolars, OMI (Dual-Top Anchor system, Jeil Medical Co., Seoul, Korea; diameter of 1.6 mm, length of 8 mm, self-drilling type), and sliding mechanics were used. OMI was placed in the buccal-attached gingiva areas between the upper second premolar and first molar just adjacent to the

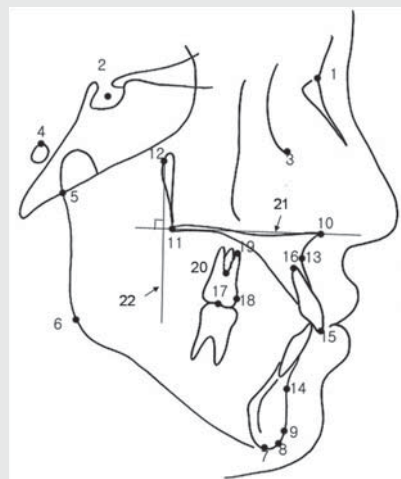


Fig. 1. Landmarks and reference lines. 1. N, nasion; 2. S, sella; 3. Or, orbitale; 4. Po, porion; 5. Ar, articulare; 6. Go, gonion; 7. Me, menton; 8. Gn, gnathion; 9. Pog, pogonion; 10. ANS, anterior nasal spine; 11. PNS, posterior nasal spine; 12. Pt, pterygoid point; 13. A, subspinale; 14. B, supramentale; 15. UIE, incisor edge of the upper central incisor; 16. UIA, root apex of the upper central incisor; 17. U6C, midpoint between the mesiobuccal and distobuccal cusps of the upper first molar; 18. U6M, most mesial point of the mesial surface of the upper first molar crown; 19. U6A, mesiobuccal root apex of the upper first molar; 20. U6F, furcation point of the upper first molar; 21. horizontal reference line, palatal plane (ANS-PNS); 22. vertical reference line, tangent plane to the horizontal reference line through Pt point.

Seung-Hak Baek et al : Conventional Anchorage Reinforcement vs. Orthodontic Mini-implant: Comparison of Posterior Anchorage Loss During the En Masse Retraction of the Upper Anterior Teeth. J Kor Dent Sci 2010.

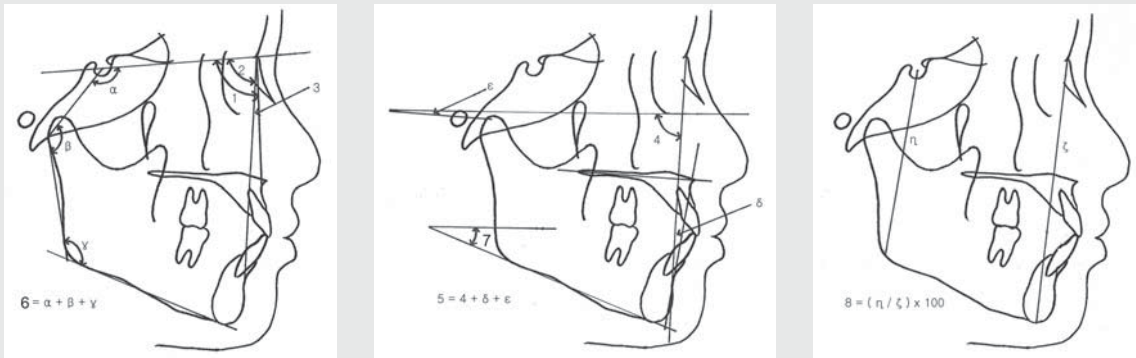


Fig. 2. Skeletal variables. (A) 1, SNA; 2, SNB; 3, ANB; 4, Björk sum ($\alpha + \beta + \gamma$); (B) 5, Facial angle (N-Pog to Frankfort horizontal plane); 6, Anteroposterior dysplasia indicator (APDI, $5 + \delta + \epsilon$); 7, Frankfort mandibular plane angle (FMA); (C) 8, Facial height ratio ($\eta / \zeta \times 100$). α means saddle angle, β , articular angle, γ , gonial angle, δ , AB-facial plane angle, ϵ , palatal plane angle, η , posterior facial height, and ζ , anterior facial height.

Seung-Hak Baek et al : Conventional Anchorage Reinforcement vs. Orthodontic Mini-implant: Comparison of Posterior Anchorage Loss During the En Masse Retraction of the Upper Anterior Teeth. J Kor Dent Sci 2010.

mucogingival junction of the upper arch after leveling and alignment. Ni-Ti closed coil springs (medium, 9 mm, Ormco, Orange, CA, USA) stretched from the OMI head to the hook on the archwire between the upper lateral incisor and canine were used beginning two weeks after OMI installation. In case of unstable or failed OMI, a new one was placed on the buccal attached gingiva

between the upper first and second molars.

- Treatment results
 - Finished with Class I canine and molar relationship
 - Normal overbite and overjet (>2 mm and <4 mm, respectively)

A total of 52 patients were selected as final samples and allocated into Group 1 (N=24, Class I malocclusion and

Table 1. Comparison of age and treatment duration between Groups 1, 2, and 3

	Group 1 (N=24)		Group 2 (N=15)		Group 3 (N=13)		Sig.
	Mean	SD	Mean	SD	Mean	SD	
Age (year)	22.65	3.97	26.32	8.40	21.53	5.50	0.0797
Treatment duration (month)	27.29	8.09	27.33	6.39	25.08	3.84	0.5933

Analysis of Variance (ANOVA) and Duncan's multiple comparison test were done. Group 1 means Class I malocclusion with conventional anchorage reinforcement, Group 2, Class I malocclusion with orthodontic mini-implant, Group 3, Class II division 1 malocclusion with orthodontic mini-implant, SD, standard deviation, and Sig., significance.

Seung-Hak Baek et al : Conventional Anchorage Reinforcement vs. Orthodontic Mini-implant: Comparison of Posterior Anchorage Loss During the En Masse Retraction of the Upper Anterior Teeth. J Kor Dent Sci 2010.

Table 2. Comparison of the skeletal variables between Groups 1, 2, and 3 before treatment (T0)

T0	Group 1 (N=24)		Group 2 (N=15)		Group 3 (N=13)		Sig.	Multiple comparison
	Mean	SD	Mean	SD	Mean	SD		
SNA	83.44	3.69	82.62	3.88	82.84	2.43	0.7493	-
SNB	80.37	3.34	78.88	4.10	76.07	2.71	0.0029**	3 < [2,1]
ANB	3.07	1.52	3.74	1.30	6.77	1.34	0.0000***	[1,2] < 3
Facial angle	88.05	3.10	87.18	3.45	85.20	2.79	0.0382*	[3,2] < [2,1]
APDI	84.82	2.98	84.71	4.50	77.33	3.39	0.0000***	3 < [2,1]
FMA	26.48	3.46	29.47	7.08	30.92	6.03	0.0475*	[1,2] < [2,3]
Björk sum	394.35	3.75	398.20	7.51	400.09	5.25	0.0081**	1 < [2,3]
Facial height ratio	0.66	0.03	0.63	0.05	0.61	0.04	0.0046**	[3,2] < 1

Analysis of Variance (ANOVA) and Duncan's multiple comparison test were done. Facial angle means N-Pog to Frankfort horizontal plane, and APDI, anteroposterior dysplasia indicator; facial height ratio was (posterior facial height/ anterior facial height) $\times 100$, and sig., was significance. *: P < .05; **: P < .01; ***: P < .001.

Seung-Hak Baek et al : Conventional Anchorage Reinforcement vs. Orthodontic Mini-implant: Comparison of Posterior Anchorage Loss During the En Masse Retraction of the Upper Anterior Teeth. J Kor Dent Sci 2010.

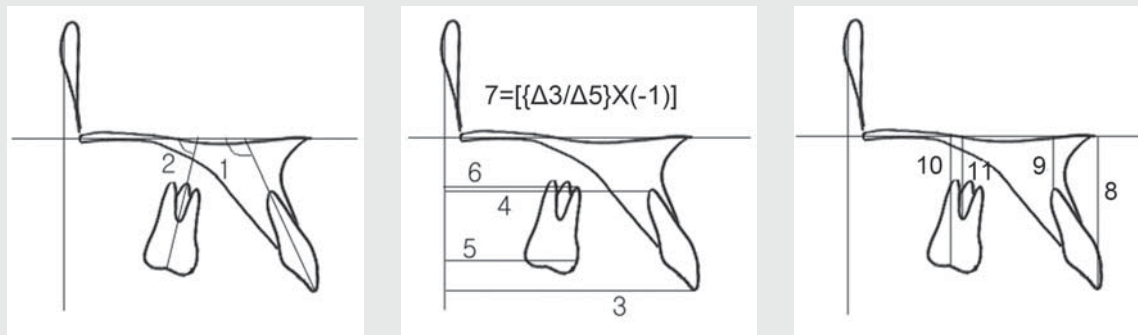


Fig. 3. Anchorage variables. (A) 1, U1 to PP (°); 2, U6 to PP (°), (B) 3, U1E-sag: shortest distance from U1E to the vertical reference line (mm); 4, U1A-sag: shortest distance from U1A to the vertical reference line (mm); 5, U6M-sag: shortest distance from U6M to the vertical reference line (mm); 6, U6A-sag: shortest distance from U6A to the vertical reference line (mm); 7, U1 to U6 ratio, $[(\Delta U1E-sag)/(\Delta U6M-sag) \times (-1)]$, amount of retraction of the upper incisal edges according to every 1 mm anchorage loss of the upper molars, (C) 8, U1E-ver: shortest distance from U1E to the horizontal reference line (mm); 9, U1A-ver: shortest distance from U1A to the horizontal reference line (mm); 10, U6C-ver: shortest distance from U6C to the horizontal reference line (mm); 11, U6F-ver: shortest distance from U6F to the horizontal reference line (mm). U1 means the long axis of the upper incisor through the upper incisor edge (U1E) and root apex of the upper incisor (U1A), PP, palatal plane, horizontal reference line, U6, long axis of the upper first molar through the center of the upper first molar crown on the occlusal surface (U6C) and furcation of the upper first molar (U6F), PTV, vertical reference line through Pt point (tangent to the horizontal reference line, palatal plane), U6M, most mesial point of the mesial surface of the upper first molar crown, and U6A, mesiobuccal root apex of the upper first molar.

Seung-Hak Baek et al : Conventional Anchorage Reinforcement vs. Orthodontic Mini-implant: Comparison of Posterior Anchorage Loss During the En Masse Retraction of the Upper Anterior Teeth. J Kor Dent Sci 2010.

CAR), Group 2 (N=15, Class I malocclusion and OMI), and Group 3 (N=13, Class II division 1 malocclusion and OMI) (Table 1).

Lateral cephalometric radiograms taken before (T0) and after treatment (T1) were traced and digitized using a graphic tablet (Wacom Co., Ltd., Vancouver, BC, Canada) and V-Ceph program (Cybermed, Seoul, Korea) by one investigator (BSH). The landmarks and reference lines are illustrated in Fig. 1. The horizontal reference line is palatal plane (ANS-PNS), and the vertical reference line is a tangent plane to the horizontal reference plane through Pt point. A total of 8 skeletal (Fig. 2) and 11 anchorage variables (Fig. 3) were measured to the nearest 0.01 mm and 0.01 degree.

Six randomly selected sets of cephalograms were retraced and redigitized after two weeks to check for measurement errors. Since there was no significant difference between the two measurements ($p > .05$; error of linear measurement < 0.98 mm; error of angular measurement $< 1.01^\circ$), the first measurement was used for this study.

One-way analysis of variance (ANOVA) was performed to compare the differences at the T0 and T1 stages and change during T0 and T1 among the three groups, with the results verified using Duncan's multiple comparison test.

Results

There was no significant difference in age at the T0 stage and treatment duration among the three groups (Table 1).

At the T0 stage, Groups 1 and 2 did not show significant difference in SNA, SNB, ANB, APDI, and Downs' facial plane angle. Note, however, that Group 3 revealed a skeletal Class II malocclusion pattern due to mandibular retrusion (facial angle, $P < .05$; SNB, $P < .01$; ANB, $P < .001$; APDI, $P < .001$; Table 2). Groups 2 and 3 exhibited a more hyperdivergent pattern than Group 1 (FMA, $P < .05$; Björk sum, $P < .01$; facial height ratio, $P < .01$; Table 2).

At the T0 stage, the anchorage variables describing the shortest distance from the upper central incisor or the upper first molar to the vertical reference line (U1E-sag, U1A-sag, U6M-sag, and U6A-sag) and angulation of the upper first molar to the horizontal reference line (U6 to PP) did not reveal any significant difference among the three groups (Table 3). Note, however, that Group 3 exhibited more upright and extruded upper incisor than Groups 1 and 2 (U1 to PP, $P < .001$; U1E-ver, $P < .05$; Table 3). These findings suggest that Class II malocclusion with mandibular retrusion had more upright and extruded upper incisors than Class I malocclusion.

Table 3. Comparison of anchorage variables between Groups 1, 2 and 3 before (T0) and after treatment (T1) and changes in anchorage variables during treatment (T1-T0)

Anchorage variables	T0 stage						T0 stage						T0 stage											
	Group 1		Group 2		Group 3.		Sig	MC	Group 1		Group 2		Group 3.		Sig	MC	Group 1		Group 2		Group 3.		Sig	MC
	Mean	SD	Mean	SD	Mean	SD			Mean	SD	Mean	SD	Mean	SD			Mean	SD	Mean	SD	Mean	SD		
U1 to PP	124.29	5.25	124.96	4.35	116.47	7.70	0.0003***	3 (1,2)	108.19	6.38	105.39	5.28	101.87	4.80	0.0089**	3 (2,1)	16.09	5.39	19.57	6.19	14.60	7.35	0.0915	
U6 to PP	86.17	5.03	83.81	4.89	83.51	10.07	0.3990		85.98	5.25	85.54	6.08	81.12	4.19	0.0269*	3 (2,1)	0.19	3.55	-1.73	2.91	2.39	9.52	0.1553	
U1E-sag	62.48	3.24	64.95	3.29	62.48	4.38	0.0877		55.22	4.12	55.68	3.85	52.92	4.70	0.1844		7.26	2.34	9.27	2.87	9.28	2.45	0.0222*	1 (2,3)
U1A-sag	48.81	2.82	50.55	2.75	51.04	4.18	0.0889		47.56	3.63	49.41	3.08	48.33	4.56	0.3298		1.25	1.93	1.13	2.33	2.65	2.16	0.1085	
U6M-sag	31.09	3.37	31.91	2.76	30.95	4.43	0.7195		33.05	3.59	32.56	3.58	31.52	3.82	0.4829		-1.96	1.48	-0.65	1.72	-0.86	1.03	0.0159*	1 (3,2)
U6A-sag	28.78	2.89	30.83	2.22	30.32	4.45	0.1253		30.80	3.23	31.28	2.90	30.50	4.19	0.8272		-2.02	1.57	-0.45	1.88	-0.46	1.67	0.0068**	1 (3,2)
U1 to U6 ratio	-	-	-	-	-	-	-	-	-	-	-	-	-	-	-	-	4.61	3.02	6.99	3.54	25.47	37.42	0.031 †	-
U1E-ver	31.74	2.23	31.84	2.78	34.23	2.48	0.0118*	1 (2) †	32.34	2.23	32.30	3.15	33.16	2.92	0.6254		-0.60	1.20	-0.46	2.03	1.07	2.27	0.0221*	1 (2) †
U1A-ver	11.31	1.95	10.85	2.60	11.37	3.03	0.8124		9.50	2.62	8.11	2.79	8.35	2.33	0.2169		1.82	1.24	2.74	2.64	3.02	2.38	0.1742	
U6C-ver	26.18	2.01	26.69	1.70	26.62	1.62	0.6496		26.57	1.79	26.61	1.77	26.28	2.23	0.8861		-0.39	1.59	0.08	1.91	0.33	1.21	0.3992	
U6F-ver	14.43	1.93	15.59	2.12	15.74	2.02	0.0979		14.94	1.97	16.07	1.97	14.62	2.54	0.1589		-0.51	0.76	-0.48	1.85	1.12	1.69	0.003**	1 (2) †

Analysis of Variance (ANOVA) and Duncan's multiple comparison test were done. U1 means a long axis of the upper central incisor from incisor tip (UIE) to apex (U1A) of the upper central incisor; U6, a long axis of the upper first molar from center of the upper first molar crown on occlusal surface (U6C) to furcation of the upper first molar (U6F); PP, palatal plane; Sag, the shortest distance to the vertical reference plane; Ver, the shortest distance to the horizontal reference plane; U6M, the most mesial point of the mesial surface of the upper first molar crown; U6A, the mesiobuccal root apex of the upper first molar; U1 to U6 ratio, $[(\Delta U1E-sag)/(\Delta U6M-sag)] \times (-1)$, the amount of retraction of the upper incisor edges according to every 1 mm anchorage loss of the upper molars.; Sig., significance; *, P<.05; **, P<.01; ***, P<.001; MC, multiple comparison; †, P<.05 for independent test between Groups 1 and 2.

Seung-Hak Baek et al : Conventional Anchorage Reinforcement vs. Orthodontic Mini-implant: Comparison of Posterior Anchorage Loss During the En Masse Retraction of the Upper Anterior Teeth. J Kor Dent Sci 2010.

At the T1 stage, Group 3 demonstrated a relatively distal inclination of the upper first molar compared to Groups 1 and 2 (U6 to PP, P<.05, Table 3) and upright upper central incisor compared to Group 1 (U1 to PP, P<.01, Table 3).

The amounts of upper incisor edge retraction in Groups 2 and 3 were significantly larger compared to Group 1 (approximately 9.3 mm: 7.3 mm, P<.05, Table 3). Note, however, that the upper incisor in all groups moved in a manner of relatively controlled tipping because the amounts of sagittal change in the upper incisor root apex showed 1.1~ 2.7 mm of lingual movement (Table 3).

In terms of posterior anchorage loss, Groups 2 and 3 exhibited significantly less posterior anchorage loss than Group 1 (U6M-sag, 0.7~0.9 mm: 2 mm, P<.05; U6A-sag, 0.5 mm: 2 mm, P<.01; Table 3).

In the vertical aspect, Group 3 showed an intrusion of the upper central incisor and first molar, although Groups 1 and 2 revealed an extrusion of such (approximately 1.1 mm intrusion: 0.5~0.6 mm extrusion U1E-ver, P<.05; U6F-ver, P<.05, respectively; Table 3).

Discussion

This study was performed to determine how much could OMI provide better posterior anchorage preservation than CAR during the en masse retraction of the upper anterior

teeth in case of Class I malocclusion with minimal crowding. To estimate the effectiveness of OMI in Class II division 1 malocclusion patients, Group 3 was included in this study.

The fact that there was no significant difference in treatment duration between Groups 1 and 2 (Table 1) implies that OMI may not significantly shorten the treatment period among patients who need maximum posterior anchorage.

A Class II malocclusion pattern in Group 3 and a more hyperdivergent pattern in Groups 2 and 3 (Table 2) suggest that OMI is used to get stabler posterior anchorage in these types.

Patients with hyperdivergent facial type are known to have weaker natural posterior anchorage than those with a hypodivergent one^{18,19)}. In this study, however, there was significantly less posterior anchorage loss in Groups 2 and 3 than Group 1 (U6M-sag, P<.05; Table 3). This implies that OMI could provide superior anchorage preservation in spite of a hyperdivergent pattern.

The fact that the upper incisor showed significantly greater amounts of retraction in Groups 2 and 3 than Group 1 (approximately 9.3 mm: 7.3 mm, P<.05, Table 3) and intrusion in Group 3 in spite of the extrusion of Groups 1 and 2 (approximately 1.1 mm intrusion: 0.5~0.6 mm extrusion, U1E-ver, P<.05; Table 3) suggests that OMI could sustain the intrusion and retraction of the upper anterior teeth.

Considering the upper premolar extraction space to be 8.3 ~

8.4 mm, the values of posterior anchorage loss in Groups 2 and 3 (0.7~0.9 mm; Table 3) were significantly less than 25 per cent of the extraction space; posterior anchorage loss in Group 1 (around 2 mm; Table 3) was the same at 25 per cent of extraction space. These results indicate that OMI could provide better maximum posterior anchorage than CAR. Moreover, the U1 to U6 ratios - meaning the ratio of retraction amount of the upper incisal edges per 1 mm of anchorage loss in the upper molars - showed significant difference between Groups 1 and 2 (approximately 4.6 mm: 7.0 mm, $P < .05$, independent t-test; Table 3). This finding implies that OMI provides stabler posterior anchorage than CAR. In Group 3, although the value of U1 to U6 ratio was highest (25.5, Table 3) among the three groups, standard deviation was also the biggest (34.7, Table 3). This was because 5 out of 13 cases showed a wide range of U1 to U6 ratio from 16 to 115, suggesting that the upper molars did not move to the mesial side at all for the correction of Class II molar relation. Therefore, comparing the mean values of three groups using the ANOVA test was meaningless. Still,

Group 3 obviously had good posterior anchorage preservation as well.

The fact that Group 3 showed a relatively distal inclination of the upper molar (U6 to PP, $P < .05$, Table 2) and the intrusion of the upper incisor and first molar (U1E-ver, $P < .05$; U6F-ver, $P < .05$, Table 3) compared to Groups 1 and 2 implies that OMI may apply the distal and intrusive vector to the entire upper arch during the en masse retraction of the upper anterior teeth. This seems to be due to the direction of pull by the Ni-Ti closed coil spring from the OMI head to the hooks on the upper archwire. Eventually, it can facilitate the correction of the anterior deep overbite and Class II molar relationships.

CONCLUSIONS

Although OMI could not shorten the treatment duration, it could provide better maximum posterior anchorage than CAR in spite of Class II malocclusion and hyperdivergent pattern.

References

1. Bills DA, Handelman CS, BeGole EA. Bimaxillary dentoalveolar protrusion: traits and orthodontic correction. *Angle Orthod* 2005;75:333-9.
2. Baek SH, Kim BH. Determinants of successful treatment of bimaxillary protrusion: orthodontic treatment versus anterior segmental osteotomy. *J Craniofac Surg* 2005;16:234-46.
3. Lee JK, Chung KR, Baek SH. Treatment outcomes of orthodontic treatment, corticotomy-assisted orthodontic treatment, and anterior segmental osteotomy for bimaxillary dentoalveolar protrusion. *Plast Reconstr Surg* 2007;120:1027-36.
4. Nanda R. *Biomechanics in Clinical Orthodontics*. Philadelphia, PA: WB Saunders; 1997. p. 156-61.
5. Kanomi R. Mini-implant for orthodontic anchorage. *J Clin Orthod* 1997;31:763-7.
6. Park HS, Bae SM, Kyung HM, Sung HM. Microimplant anchorage for treatment of skeletal Class I bialveolar protrusion. *J Clin Orthod* 2001;35:417-22.
7. Bae SM, Park HS, Kyung HM, Kwon OW, Sung JH. Clinical application of micro-implant anchorage. *J Clin Orthod* 2002;36:298-302.
8. Baek SH, Moon CH, Sung SJ, et al. Orthodontic mini-implant: Various treatment strategy and clinical application. Seoul, Korea: Jeessung Pub. Co.; 2007. p. 216-28.
9. Moon CH, Lee DG, Lee HS, Im JS, Baek SH. Factors associated with the success rate of orthodontic miniscrews placed in the upper and lower posterior buccal region. *Angle Orthod* 2008;78:101-6.
10. Baek SH, Kim BM, Kyung SH, Lim JK, Kim YH. Success rate and risk factors associated with mini-implants reinstalled in the maxilla. *Angle Orthod* 2008;78:895-901.
11. Cha BK, Lee YH, Lee NK, Choi DS, Baek SH. Soft tissue thickness for placement of an orthodontic miniscrew using an ultrasonic device. *Angle Orthod* 2008;78:403-8.
12. Kim JW, Baek SH, Kim TW, Chang YI. Comparison of stability between cylindrical and conical type mini-implants: mechanical and histological properties. *Angle Orthod* 2008;78:692-8.
13. Herman RJ, Currier GF, Miyake A. Mini-implant anchorage for maxillary canine retraction: a pilot study. *Am J Orthod Dentofacial Orthop* 2006;130:228-35.
14. Thiruvengkatachari B, Pavithranand A, Rajasigamani K, Kyung HM. Comparison and measurement of the amount of anchorage loss of the molars with and without the use of implant anchorage during canine retraction. *Am J Orthod Dentofacial Orthop* 2006;129:551-4.
15. McLaughlin RP, Bennett JC. The transition from standard edgewise to preadjusted appliance systems. *J Clin Orthod* 1989;23:142-53.
16. Bennett JC, McLaughlin RP. Controlled space closure with a preadjusted appliance system. *J Clin Orthod* 1990;24:251-60.
17. McLaughlin RP, Bennett JC. Anchorage control during leveling and aligning with a preadjusted appliance system. *J Clin Orthod* 1991;25:687-96.
18. Woods MG. The mechanics of lower incisor intrusion: experiments in nongrowing baboons. *Am J Orthod Dentofacial Orthop* 1988;93:186-95.
19. Runge ME, Sadowsky C. Class II, division 1 vertical pattern. *Am J Orthod Dentofacial Orthop* 1988;94:271-7.