

A hybrid technique for sinus floor elevation in the severely resorbed posterior maxilla

Ui-Won Jung, Ji-Youn Hong, Jung-Seok Lee, Chang-Sung Kim, Kyoo-Sung Cho, Seong-Ho Choi*

Department of Periodontology, Research Institute for Periodontal Regeneration, College of Dentistry, Yonsei University, Seoul, Korea

Purpose: This study aimed to evaluate the effectiveness of the modified sinus floor elevation technique described hereafter as a “hybrid technique,” in 11 patients with severely resorbed posterior maxillae.

Methods: Eleven patients who received 22 implants in the maxillary premolar and molar areas by the hybrid technique were enrolled in this study. A slot-shaped osteotomy for access was prepared on the lateral wall along the lower border of the sinus floor. The Schneiderian membrane was fully reflected through the lateral slot. Following drilling with the membrane protected by a periosteal elevator, the bone was grafted. All implants were placed simultaneously with sinus augmentation. The cumulative success rate was calculated and clinical parameters were recorded. Radiographic measurements were performed.

Results: All implants were well maintained at last follow up (cumulative success rate=100%). The mean residual bone height, augmented bone height, crown-to-implant ratio, and marginal bone loss were 4.1 ± 1.64 mm, 8.76 ± 1.77 mm, 1.21 ± 0.33 mm, and 0.34 ± 0.72 mm, respectively.

Conclusions: Simultaneous implant placement with sinus augmentation by hybrid technique showed successful clinical results over a 2-year observation period and may be a reliable modality for reconstruction of a severely resorbed posterior maxilla.

Keywords: Bone substitutes, Dental implants, Maxillary sinus.

INTRODUCTION

It can be challenging to place implants in the posterior maxilla because various anatomical limitations can jeopardize the long-term success of implant rehabilitation [1]. In particular, reduced vertical alveolar bone height resulting from pneumatization of the maxillary sinus [2,3] and resorption of the ridge following tooth extraction [4] often hamper placement of the implant with a proper length.

Since it was first introduced by Boyne in 1969, maxillary sinus floor elevation utilizing the Caldwell-Luc technique has been associated with clinical success [5-11]. This technique provides an easier approach to the sinus membrane with

good visibility through the lateral opening. However, disadvantages, like invasiveness of the surgical procedure, bleeding, postoperative swelling, and pain, do exist. This technique is also associated with high risks for various biological complications including membrane perforation, exposure of the opening site, infection, and fistula formation.

In order to simplify the lateral window technique, Summers introduced the crestal approach, called bone-added osteotome sinus floor elevation (BAOSFE) [12]. This procedure is relatively more conservative and less invasive; however, some problems for common use remain, the most prominent of which are limited accessibility and visibility for elevating the sinus membrane. The Schneiderian membrane is elevat-

Received: Feb. 10, 2010; Accepted: Mar. 25, 2010

*Correspondence: Seong-Ho Choi

Department of Periodontology, Research Institute for Periodontal Regeneration, Yonsei University College of Dentistry, 134 Shinchon-dong, Seodaemun-gu, Seoul 120-752, Korea

E-mail: shchoi726@yuhs.ac, Tel: +82-2-2228-3189, Fax: +82-2-392-0398

ed only by hydraulic pressure from the plug of bone graft materials with fluid reserved inside and using a set of osteotomes (Implant Innovations, Palm Beach Gardens, USA) for compaction rather than direct surgical undermining. Thus, the extent of reflection varies according to the elasticity of the membrane and the attachment to the underlying bone [13]. Excessive distension can lead to perforation of the membrane, the frequency of which is approximately 3.8% (range, 0-21.4%).

Opinions about the effect of membrane perforation during BAOSFE on the success rate of implantation are controversial. Some reports suggest that the influence is insignificant [14-17], while others have reported associated reductions in survival rates [18,19]. Still, the integrity of the sinus membrane is important for containing graft materials, and for BAOSFE, the augmentation is generally limited to 3-5 mm in height.

The height of the remaining bone can be correlated with the success rate of the implant placed using the BAOSFE technique. The general recommendation is to use this technique when there is 5-7 mm of remaining bone [20]. When 4 mm or less of the bone is available, the success rate is 85.7%, as compared to 96% when the minimum height is 5 mm [21]. It can be assumed that 6 mm or more of preexisting bone would be required to accommodate an implant at least 10 mm in length since the achievable bone gain with the BAOSFE technique is limited to 3-5 mm [12,22]. Furthermore, a sufficient amount of bone is needed to provide appropriate initial stability for the implant.

In brief, the lateral window approach allows substantial elevation of the sinus floor and provides a good visual approach to the Schneiderian membrane. On the other hand, the crestal approach is less invasive, shows reduced postoperative complications, and improves initial stability with osteotome condensation. Therefore, if greater bone augmentation and sufficient initial stability are achieved without perforation of the sinus membrane when using the BAOSFE technique, the 5-mm limitation could be overcome.

This study aimed to evaluate the effectiveness of the modified sinus floor elevation technique described here as a "hybrid technique," which is a BAOSFE-based technique combined with a minimal-sized lateral access slot for direct surgical undermining of the Schneiderian membrane, in 11 patients with severely resorbed posterior maxillae.

MATERIALS AND METHODS

Patient and site description

This study was carried out at the Department of Periodontology of the Dental Hospital of Yonsei University, Seoul, South Korea and included 11 patients who visited between

December 2006 and August 2007 for fixed type implant rehabilitation in maxillary posterior areas with limited bone height. Systemic health and extraoral and intraoral conditions were evaluated. Medically compromised patients were referred to a physician. Prior to sinus augmentation, internal disease of the maxillary sinus, the remaining depth of the alveolar ridge, and the position of septum were determined precisely using panoramic radiographs and computerized tomography (CT). Three-dimensional reconstructions of the pre-operative CT scans (OnDemand 3D[®] program, CyberMed, Seoul, Korea) were prepared for treatment planning, determining the insertion path, and simulation of the surgery. Patients were selected according to the following inclusion criteria: 1) A remaining posterior maxillary edentulous ridge with insufficient vertical bone height, 2-7 mm, 2) Healing time since tooth extraction longer than 3 months.

Exclusion criteria included: 1) an uncontrolled medical condition: a psychological disorder, diabetes mellitus, immune suppression, bisphosphonate medication, chemotherapy, or radiotherapy, 2) a pathologic lesion in the sinus: benign/malignant tumor, mucocele, or active sinusitis, 3) parafunctional habits like bruxism or clenching, 4) untreated active periodontitis in neighboring teeth.

The general procedures for implantation and the possible complications were thoroughly explained to the patients. The treatment option was chosen after discussing the benefits and risks of the surgery with each patient. Written informed consent, which was in accordance with the institutional review board (IRB) at Yonsei Dental Hospital (2-2008-0011), was obtained from each patient.

Eleven patients were included: eight men and three women, with an average age of 49.4 years (range, 35-69 years). All patients were determined to have intact and healthy maxillary sinuses. None of the patients smoked and patients with active periodontal lesions were treated before implant surgery.

All of the patients, except one with severe dental caries, had undergone tooth extraction due to periodontal problems, and one patient (patient no. 6) was diagnosed with generalized aggressive periodontitis (GAP). Twenty-two dental implants (Straumann SLA[®], Institute Straumann AG, Waldenburg, Switzerland) were placed in the maxillary premolar and molar areas using the hybrid technique: 10 on the right and 13 on the left. All of the implants were placed with the length of at least 10 mm and 95.5% were wider than 4.8 mm in diameter. Detailed information about the patients and implants placed are listed in Table 1.

Surgical procedures

Pre-surgical CT (GE Medical System, Milwaukee, USA)

scans were performed to evaluate the pathologic lesion and identify the size and shape of the maxillary sinus (Fig. 1). Surgical procedures were performed using antibiotic prophylax-

Table 1. Details of the individual implants placed.

Patient number	Missing tooth	Implant diameter/length (mm)	Amount of bone graft material (g)	Follow-up period (months)
1	#26	S 4.1RN / 10	MBCP 0.5 + Auto	33
	#27	TE 4.1RN / 10		33
2	#27	TE 4.8WN / 12	MBCP 0.5 + Auto	32
3	#17	S 4.8WN / 10	MBCP 1.5 + Auto	28
	#16	TE 4.1RN / 10		28
	#26	TE 4.1RN / 10		28
	#27	S 4.8WN / 10		28
4	#16	S 4.8WN / 10	MBCP 0.5 + Auto	29
5	#15	TE 4.1RN / 10	MBCP 0.25 + Auto	26
6	#17	TE 4.8WN / 10	MBCP 3 + Auto	25
	#16	TE 4.8WN / 10		25
	#25	TE 4.1RN / 10		25
	#26	S 4.8WN / 10		25
	#27	S 4.8WN / 10		25
7	#16	TE 4.1RN / 10	MBCP 0.5	28
8	#26	TE 4.8WN / 10	MBCP 1.0 + Auto	27
	#27	TE 4.8WN / 10		27
9	#17	S 4.8WN / 10	MBCP 0.5 + Oragraft	27
	#16	S 4.8WN / 10		27
10	#26	S 4.8RN / 10	Osteon 0.5 + Oragraft	25
	#27	S 4.8RN / 10		25
11	#27	S 4.8RN / 10	Osteon 0.5 + Auto	25

Diameter—S: standard, TE: tapered effect, RN: regular neck, WN: wide neck.
Bone graft material—MBCP[®]: macroporous biphasic calcium phosphate, Osteon[®], Oragraft[®], Auto: autogenous bone.

is (Augmentin[®], Il-Sung Drug Company, Seoul, Korea). Local anesthesia was achieved with lidocaine 2% with 1:100,000 epinephrine (Yuhan, Seoul, Korea). Horizontal midcrestal and vertical releasing incisions were made and a full thickness flap was reflected. A slot-shaped osteotomy was prepared on the lateral bony wall using a piezoelectric device (Piezosurgery, Mectron, Carasco, Italy) (Fig. 2). The position of the slot opening was just above the sinus floor, running along the lower border. The mesiodistal width of the slot was extended just enough to include the placement sites. The apicocoronal height was about 3-5 mm to allow proper access of the elevation instruments to the sinus floor. Schneiderian membrane reflection was fully extended mesiodistally and medially over the future drilling site using a sinus membrane elevator inserted through the access slot. Drilling was performed in serial sequence while the membrane was protected by a periosteal elevator (Fig. 3). Bone graft material (MBCP[®], Biomat-lante, Vigneux de Bretagne, France; Osteon[®], Dentium, Seoul, Korea) was added from both directions through the lateral slot and drilled sites. Final site preparation was performed not with drills but with osteotomes (Institut Straumann AG, Waldenburg, Switzerland), using the final diameter or one step smaller to condense the bone available (Fig. 4). Implants were placed simultaneously with sinus augmentation (Fig. 5), and insertion torque was recorded.

Simple interrupted and mattress sutures were made using 4-0 Monosyn[®] (gluconate monofilament, B. Braun, Melsungen, Germany). The sutures were removed after 10-14 days and the patients were prescribed 2% chlorhexidine 3 times per day over 2 weeks. Temporary dentures were not allowed until overall swelling had subsided, at which time the denture could be relined.

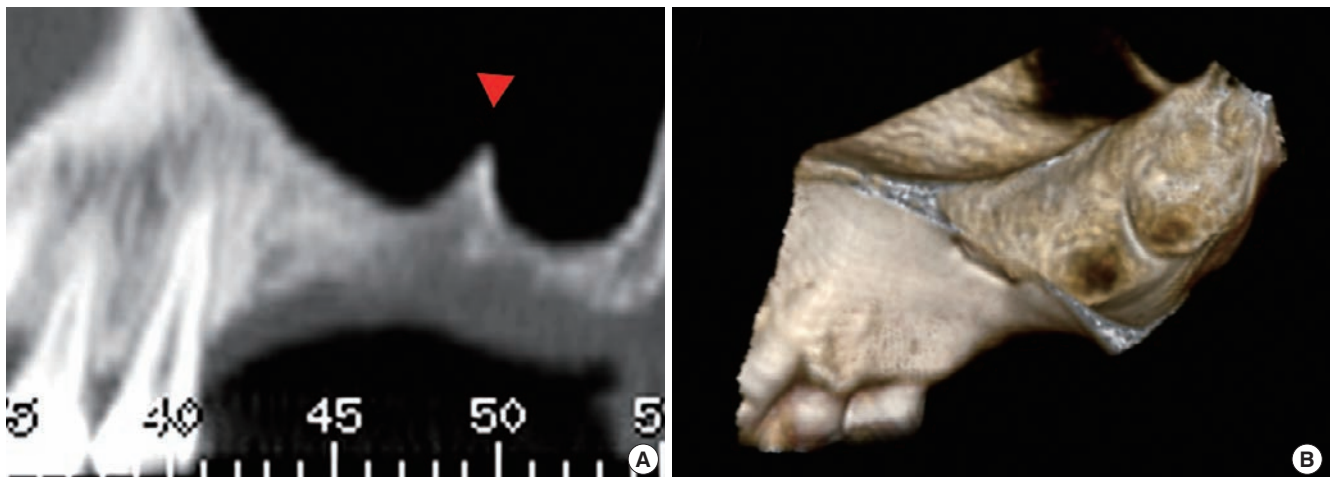


Figure 1. Pre-operative computed tomography. (A) Panoramic view. (B) Three-dimensional reconstructed image. Note that there was a septum at the second molar area in the left maxillary sinus.

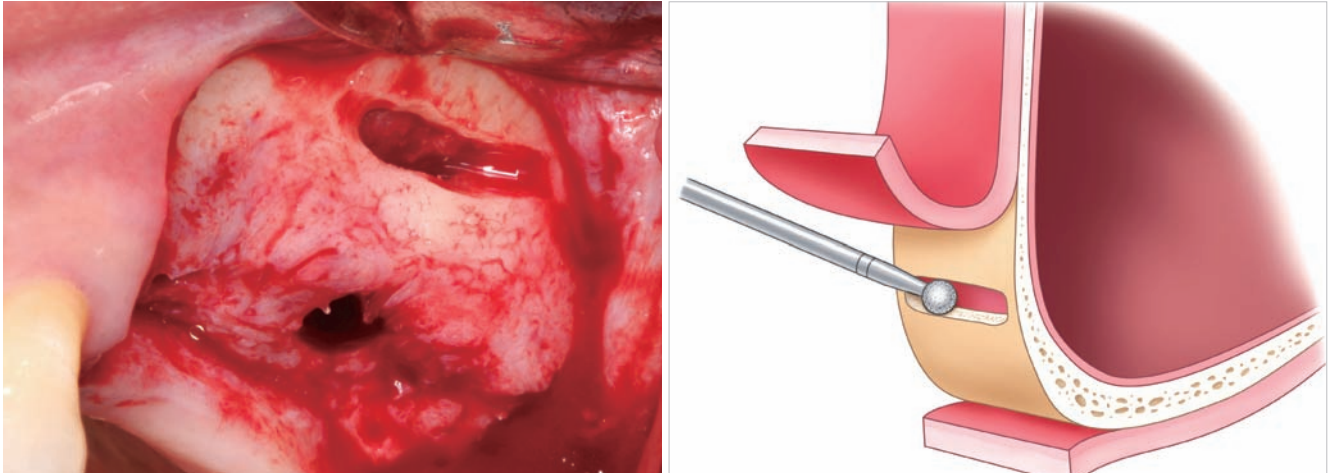


Figure 2. Preparation of the access slot and drilling of the implant site.

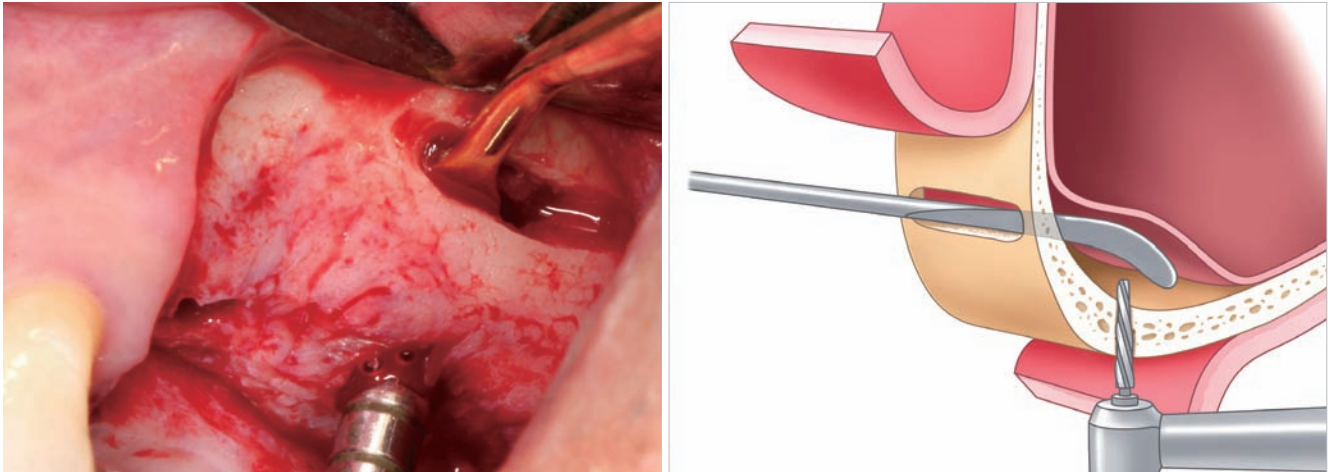


Figure 3. After reflection of the flap, the access slot was prepared along the lower borderline of the sinus with the piezoelectric device. Drilling was performed while the Schneiderian membrane was protected by the periosteal elevator.

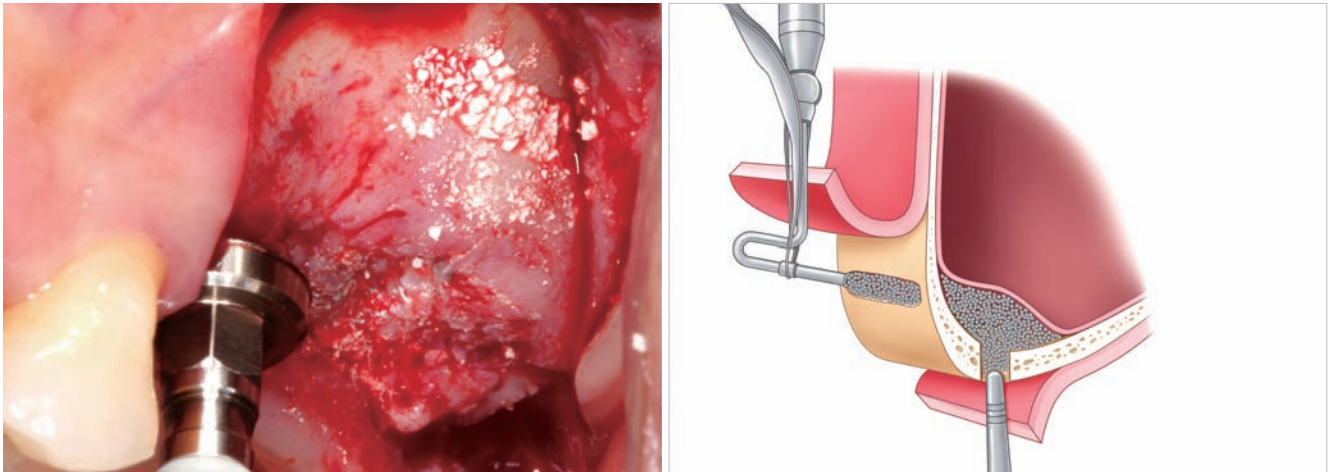


Figure 4. Bone grafting through lateral slot and drilled sites.

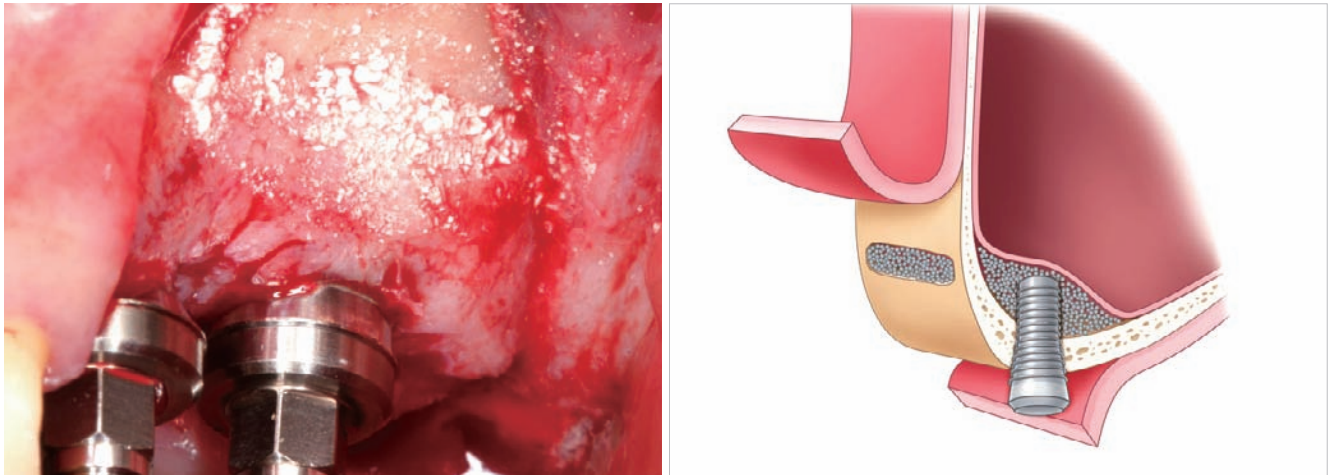


Figure 5. Simultaneously placed implants at the second molar area.

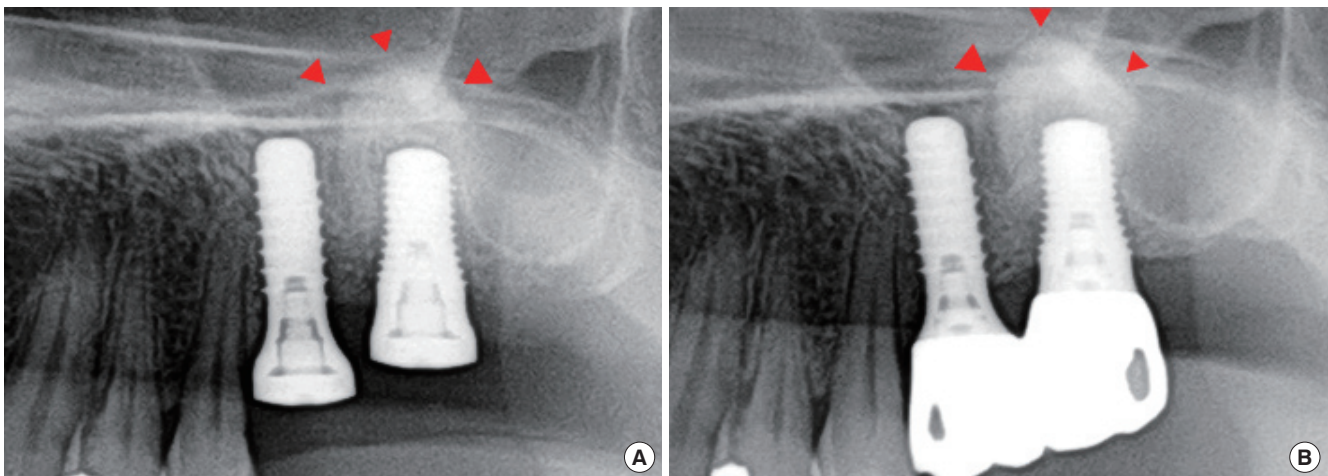


Figure 6. Radiographs on the day of surgery (A) and 27 months after surgery (B). Arrowheads: augmented bone area.

Prosthetic treatment and maintenance

The prosthetic treatments and functional loadings were incorporated after a healing period of 5-10 months (average, 7.5 months). All patients had been provided with screw-retained type prosthetics using a SynOcta® abutment (Institute Straumann AG, Waldenburg, Switzerland). After the final setting of the crown, patients received follow-up care every 3 months. Examination included evaluation of soft tissue and oral hygiene states, particularly around the implants.

Evaluation and analysis

All patients were followed until August 2009. Clinical parameters including the plaque index (Löe & Silness), gingival index (Silness & Löe), probing depth, and peri-implant keratinized tissue were evaluated at the final follow-up appointment. Radiographic parameters including preoperative remaining bone height, postoperative augmented bone height,

crown-to-implant ratio, and marginal bone loss were evaluated just after implant surgery, one year after placement, and at the final follow-up visits, and were compared to the baseline measurements (Figs. 6-8). All measurements were performed twice by different investigators.

At the final visit, cone beam volumetric tomography was performed for radiographic evaluation of the grafted sinus in 6 patients (Fig. 9). Panoramic and peri-apical standard radiographs were taken for the remainder. The presence of any complications was recorded. The categories were: 1) operative complications: excessive bleeding, perforation of membrane, and benign paroxysmal vertigo, 2) postoperative complications: swelling, ecchymosis, pain, loss of graft materials, and nasal bleeding, 3) prosthetic complication: decementation, screw loosening, fracture of porcelain, and fracture of fixture.

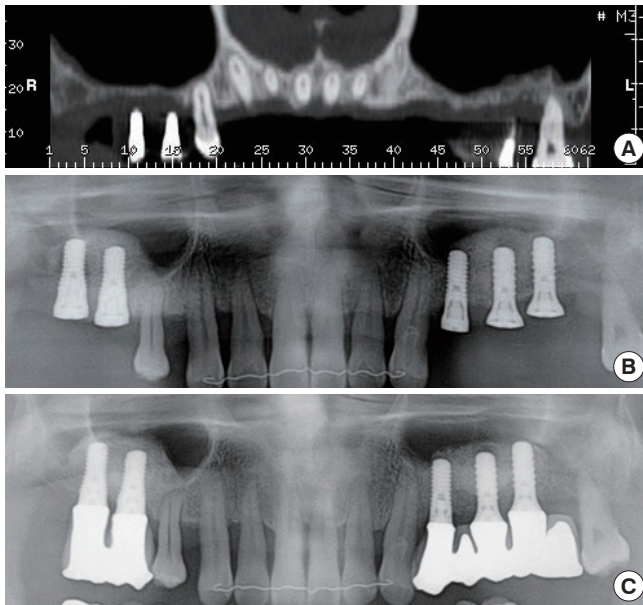


Figure 7. (A) Following extraction of the maxillary premolars and molars due to generalized aggressive periodontitis, a thin alveolar ridge remained. (B) Simultaneous implant placement with sinus floor elevation using a hybrid technique. (C) Radiograph 25 months after surgery.

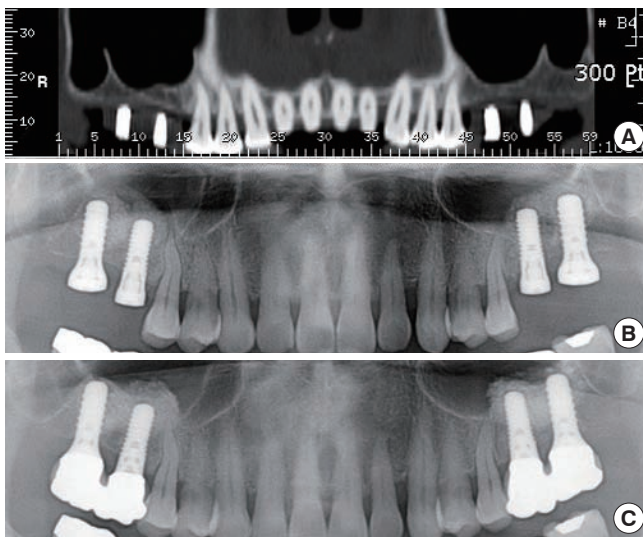


Figure 8. (A) Bilateral edentulous alveolar ridge in the posterior maxilla. (B) Simultaneous implant placement with sinus floor elevation using a hybrid technique. (C) Radiograph 27 months after surgery.

Statistical analysis

The cumulative success rate (CSR) of the implants placed using the hybrid technique was calculated by life-table analysis [23]. The criteria for success were those proposed by Cochran et al. [24] 1) absence of clinically detectable implant mobility, 2) absence of pain or subjective sensation, 3) absence of recurrent peri-implant infection, and 4) absence of continu-

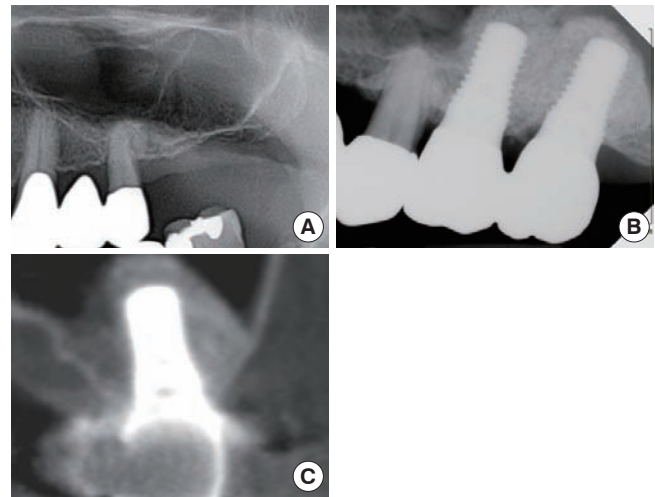


Figure 9. (A) Extremely resorbed and pneumatized posterior maxilla. Note that 1-2 mm of alveolar bone height remained. (B) Simultaneous implant placement with sinus floor elevation using a hybrid technique. (C) Dome-shaped augmented bone can be observed on cross-sectional view.

ous radiolucency around the implant. For the radiographic measurements, the correlation between the evaluations of the two examiners was determined.

RESULTS

All patients were followed for an average of 27.3 months (range, 25-33 months). There were no failures or removal of the fixtures, and 22 implants were maintained until the final recall.

Details about implant placements and clinical observations

Using the hybrid technique by slot access, an average of 0.45 g of bone substitute was used for each implant. In some cases, a minimal amount of autogenous bone was added. Insertion torque after implant installation was 29.57 Ncm (range, 0-50 Ncm).

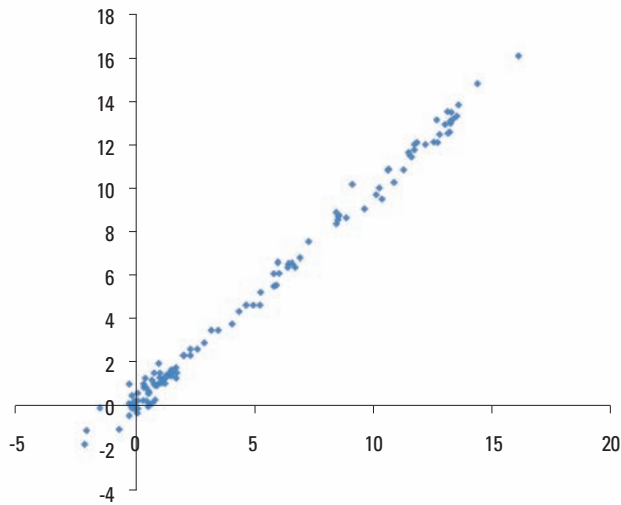
Table 2 shows the plaque and gingival index values measured at last follow-up examination. All patients except one maintained good or acceptable oral hygiene. The normal range of probing depth was present in all patients (Table 3). The width of keratinized tissue around the implant was 4.64 ± 1.56 mm. The patient who was diagnosed with GAP received five implants in the severely resorbed posterior maxilla; all implants were well maintained (Fig. 7).

Radiographic analysis

The measurements of the two different examiners were well correlated (correlation coefficient=0.99, $P < 0.0001$) (Fig. 10).

Table 2. Clinical parameters: plaque index and gingival index (n=22).

Index	Plaque index		Gingival index	
	Number of implants	%	Number of implants	%
0	4	18.18	4	18.18
1	17	77.27	17	77.27
2	1	4.55	1	4.55

**Figure 10.** Inter-examiner agreement (correlation coefficient=0.99, $P < 0.0001$).

Radiographic analysis showed that the augmented bone graft formed a dome with a clear round margin under the elevated Schneiderian membrane. This grafted area surrounded the fixture, and the implant apex was not exposed out of the dome or the membrane. The means and standard deviations of radiographic parameters are shown in Table 4.

Cumulative success rate

No patients withdrew from the study; the CSR was 100%.

Complications

There were no perforations of the sinus membranes, even for patients who had an irregularly shaped floor or specific septum involved. Benign paroxysmal vertigo, which can sometimes occur after severe osteotome preparation, did not occur in any patient. Bleeding and/or facial swelling that occurred after the surgery was relatively mild as compared to that following the conventional lateral window approach. Postoperative complications like ecchymosis, loss of graft materials, or nasal bleeding did not occur. After functional loading, no specific prosthetic complications were observed.

Table 3. Probing depth of implants (n=22).

mm	Probing depth	
	Number of implants	%
1-2	8	36.36
2-3	13	59.09
3-4	1	4.55

Table 4. Radiographic analysis.

		Number of implants	Mean \pm SD
Remaining bone height	2-4 mm	11	4.1 \pm 1.64
	4-6 mm	8	
	6-8 mm	3	
Augmented bone height	5-7 mm	6	8.76 \pm 1.77
	7-9 mm	6	
	\geq 9 mm	10	
Crown to implant ratio	0.5-1.0	6	1.21 \pm 0.33
	1.0-1.5	12	
	1.5-2.0	4	
Marginal bone loss	<0 mm	3	0.34 \pm 0.72
	0-0.5 mm	11	
	0.5-1.0 mm	5	
	1.0-1.5 mm	3	

DISCUSSION

Many treatment modalities have been proposed to overcome an inadequate volume of bone in atrophic ridges and pneumatized maxillary sinuses. Tooth-implant connected bridges, zygoma implants, and short or tilted implants are the alternatives for graftless reconstruction, whether or not the distraction osteogenesis, sinus floor, or inlay/onlay grafts compensated for the vertical loss of bone with hard tissue augmentation [25]. Despite evidence of clinical utility, few of these techniques are appropriate for routine use by practitioners. In this study, we proposed a hybrid technique as a simpler and safer alternative for placing dental implants simultaneously with sinus elevation in severely resorbed posterior maxilla and evaluated the clinical outcomes in 11 patients over 2 years of follow up.

The hybrid technique used in this study was based on BAOSFE and was modified to have a lateral access slot, which was derived in part from the lateral window concept. BAOSFE is a less traumatic technique that decreases patient morbidity. Specially designed osteotomes with concave tips are inserted just short of the membrane so as not to penetrate the floor, and the membrane is elevated by a hydraulic plug composed of bone particles and fluids trapped in the tips of instruments [12]. This blood cushion helps to avoid direct

contact between the sinus membrane and the hard objects like bone substitutes, particles, and instruments [26]. However, in several studies, in which favorable clinical results and no specific signs of perforations were detected during BAOSFE, disrupted membrane integrity around the augmented area was found upon endoscopic evaluation [16,17]. In most of the cases, microlaceration and small-sized perforation were involved with vertically excessive, but laterally limited, distension of the elevated membrane, which could cause displacement and loss of the graft materials. Transient or chronic sinusitis, local inflammation, and resorption of the bone graft by extravasation of the graft materials have been reported, stressing the importance of maintaining membrane integrity to guide bone regeneration underneath [27,28].

The primary purpose for modifying BAOSFE with lateral slot osteotomy was to provide good visual access for reflecting the Schneiderian membrane at the inferior border of the sinus floor. The apico-coronal dimension of the slot is 3-4 mm, and the mesiodistal extension included the implantation site (ideally to within 2 mm above the lower border of the sinus floor). Limiting these dimensions provided a passageway for instrumentation without causing any difficulties to the membrane at the inferior sinus border. The slot may decrease the risk of tearing and perforation during surgery and overcome the limitations associated with the blind technique or the conventional lateral window technique.

In the blind technique, the Schneiderian membrane might be at high risk for perforation due to the restricted reflection pattern [13,16]. In the hybrid technique, drilling was performed and osteotomes were used under the protection of the membrane with the periosteal elevator inserted through the slot. Drilling with direct vision and the protection of the membrane reduced the number of tappings on the sinus floor, which also decreased the chance of perforation related to the tapping sequence [17,21]. In addition, minimizing tapping might reduce patient discomfort and the chance of paroxysmal positional vertigo that can be induced by head trauma with vibratory and percussive pressures on the upper maxilla [29-31].

A thin sinus membrane, an irregularly sloped inferior border, and specific anatomic structures like the sinus septa are also involved with membrane perforation [7,32,33]. The prevalence of sinus septa is about 25% and sinus septa are significantly more common in the atrophic edentulous maxillary segments than in the non-atrophic dentate areas [34,35]. In the lateral window technique, membrane perforation rates during bone grafting have been reported at 10-40% [7,36-38]. Hinge-type openings might make tearing more likely when associated with septa [33] or an anatomically narrow-shaped sinus (in the sagittal section), which preclude window dis-

placement inward and upward [33,39]. In our study, some patients showed septa or moderately inclined slopes that could have experienced perforations if the elevations were performed by conventional crestal or lateral approaches. However, with the help of visual access and minimal reflection of the Schneiderian membrane, there was no excessive tension to cause rupture when the graft materials were pushed upwards and no specific complications were observed.

In the conventional lateral window approach, too much bone substitute tends to be used. Direct application of the graft materials through the drilling site ensured the even distribution in all directions and created a dome-shaped elevation around the implant apex. The average volume of the grafted material was approximately 0.45 mg per implant. Most of the grafted material surrounded the implant closely.

The survival rate of sinus augmentations is significantly higher when the barrier membrane is placed on the lateral window than when no barrier is placed [8,40]. Sealing by barrier membrane can isolate the grafted material from connective tissue invasion and results in a better quality of bone. Despite the fact that no barrier membrane coverage was used in this study, there were no signs of graft material loss, and dimensional changes of the augmented bone were minimal.

In the hybrid technique, the sizes of the incision and reflection of the periosteal flap are minimized with respect to the conventional lateral window technique, which might reduce postoperative complications like swelling and pain. Because of the limited-sized preparations, the chance of intruding into several intraosseous anastomoses in the lateral sinus wall is reduced.

If sufficient primary stability is provided, a one-stage approach is preferred, even in minimal residual alveolar bone. Primary stability, which protects the implants from micromovement, is an important factor for successful implantation. In this study, better initial stability was achieved because the soft bone was compressed by the osteotome during the final preparation of the implant bed. In addition, the coronal tapered design of the fixture improved initial stability. Hence, if the initial stability can be controlled despite a lack of residual bone height, successful osseointegration of implants can be expected. In this study, the mean insertion torque representing primary stability of the implant was approximately 30 Ncm, and there was no spinning of the implants when tightened manually.

Within the limitations of the small number of patients and the relatively short follow-up period, our results indicate that simultaneous implant placement with sinus augmentation by hybrid technique resulted in clinically successful outcomes over a 2-year observation period and suggest that this technique is a predictable treatment modality in severely re-

sorbed posterior maxillae with a low prevalence of complications.

CONFLICT OF INTEREST

No potential conflict of interest relevant to this article was reported.

ACKNOWLEDGMENTS

This study was supported by a faculty research grant from Yonsei University College of Dentistry for 2009 (6-2009-0041).

REFERENCES

- Jaffin RA, Berman CL. The excessive loss of Branemark fixtures in type IV bone: a 5-year analysis. *J Periodontol* 1991;62:2-4.
- Chanavaz M. Anatomy and histophysiology of the periosteum: quantification of the periosteal blood supply to the adjacent bone with ^{85}Sr and gamma spectrometry. *J Oral Implantol* 1995;21:214-9.
- Sharan A, Madjar D. Maxillary sinus pneumatization following extractions: a radiographic study. *Int J Oral Maxillofac Implants* 2008;23:48-56.
- Pietrokovski J, Massler M. Alveolar ridge resorption following tooth extraction. *J Prosthet Dent* 1967;17:21-7.
- Boyne PJ, James RA. Grafting of the maxillary sinus floor with autogenous marrow and bone. *J Oral Surg* 1980;38:613-6.
- Geurs NC, Wang IC, Shulman LB, Jeffcoat MK. Retrospective radiographic analysis of sinus graft and implant placement procedures from the Academy of Osseointegration Consensus Conference on Sinus Grafts. *Int J Periodontics Restorative Dent* 2001;21:517-23.
- Jensen OT, Shulman LB, Block MS, Iacono VJ. Report of the Sinus Consensus Conference of 1996. *Int J Oral Maxillofac Implants* 1998;13 Suppl:11-45.
- Pjetursson BE, Tan WC, Zwahlen M, Lang NP. A systematic review of the success of sinus floor elevation and survival of implants inserted in combination with sinus floor elevation. *J Clin Periodontol* 2008;35:216-40.
- Tatum H, Jr. Maxillary and sinus implant reconstructions. *Dent Clin North Am* 1986;30:207-29.
- Wallace SS, Froum SJ. Effect of maxillary sinus augmentation on the survival of endosseous dental implants. A systematic review. *Ann Periodontol* 2003;8:328-43.
- Wood RM, Moore DL. Grafting of the maxillary sinus with intraorally harvested autogenous bone prior to implant placement. *Int J Oral Maxillofac Implants* 1988;3:209-14.
- Summers RB. A new concept in maxillary implant surgery: the osteotome technique. *Compendium* 1994;15:152-8.
- Pommer B, Unger E, Suto D, Hack N, Watzek G. Mechanical properties of the Schneiderian membrane in vitro. *Clin Oral Implants Res* 2009;20:633-7.
- Aimetti M, Romagnoli R, Ricci G, Massei G. Maxillary sinus elevation: the effect of macrolacerations and micro-lacerations of the sinus membrane as determined by endoscopy. *Int J Periodontics Restorative Dent* 2001;21:581-9.
- Becker ST, Terheyden H, Steinriede A, Behrens E, Springer I, Wiltfang J. Prospective observation of 41 perforations of the Schneiderian membrane during sinus floor elevation. *Clin Oral Implants Res* 2008;19:1285-9.
- Berengo M, Sivolella S, Majzoub Z, Cordioli G. Endoscopic evaluation of the bone-added osteotome sinus floor elevation procedure. *Int J Oral Maxillofac Surg* 2004;33:189-94.
- Nkenke E, Schlegel A, Schultze-Mosgau S, Neukam FW, Wiltfang J. The endoscopically controlled osteotome sinus floor elevation: a preliminary prospective study. *Int J Oral Maxillofac Implants* 2002;17:557-66.
- Hernandez-Alfaro F, Torradeflot MM, Marti C. Prevalence and management of Schneiderian membrane perforations during sinus-lift procedures. *Clin Oral Implants Res* 2008;19:91-8.
- Proussaefs P, Lozada J, Kim J, Rohrer MD. Repair of the perforated sinus membrane with a resorbable collagen membrane: a human study. *Int J Oral Maxillofac Implants* 2004;19:413-20.
- Bruschi GB, Scipioni A, Calesini G, Bruschi E. Localized management of sinus floor with simultaneous implant placement: a clinical report. *Int J Oral Maxillofac Implants* 1998;13:219-26.
- Rosen PS, Summers R, Mellado JR, Salkin LM, Shanaman RH, Marks MH, et al. The bone-added osteotome sinus floor elevation technique: multicenter retrospective report of consecutively treated patients. *Int J Oral Maxillofac Implants* 1999;14:853-8.
- Zitzmann NU, Scharer P. Sinus elevation procedures in the resorbed posterior maxilla. Comparison of the crestal and lateral approaches. *Oral Surg Oral Med Oral Pathol Oral Radiol Endod* 1998;85:8-17.
- Cutler SJ, Ederer F. Maximum utilization of the life table method in analyzing survival. *J Chronic Dis* 1958;8:699-712.
- Cochran DL, Buser D, ten Bruggenkate CM, Weingart D, Taylor TM, Bernard JP. The use of reduced healing times on ITI implants with a sandblasted and acid-etched (SLA) surface: early results from clinical trials on ITI SLA implants. *Clin Oral Implants Res* 2002;13:144-53

25. Friberg B. The posterior maxilla: clinical considerations and current concepts using Branemark System implants. *Periodontol 2000* 2008;47:67-78.
26. Vitkov L, Gellrich NC, Hannig M. Sinus floor elevation via hydraulic detachment and elevation of the Schneiderian membrane. *Clin Oral Implants Res* 2005;16:615-21.
27. Doud Galli SK, Lebowitz RA, Giacchi RJ, Glickman R, Jacobs JB. Chronic sinusitis complicating sinus lift surgery. *Am J Rhinol* 2001;15:181-6.
28. Tidwell JK, Blijdorp PA, Stoeltinga PJ, Brouns JB, Hinderks F. Composite grafting of the maxillary sinus for placement of endosteal implants. A preliminary report of 48 patients. *Int J Oral Maxillofac Surg* 1992;21:204-9.
29. Di Girolamo M, Napolitano B, Arullani CA, Bruno E, Di Girolamo S. Paroxysmal positional vertigo as a complication of osteotome sinus floor elevation. *Eur Arch Otorhinolaryngol* 2005;262:631-3.
30. Penarrocha-Diago M, Rambla-Ferrer J, Perez V, Perez-Garrigues H. Benign paroxysmal vertigo secondary to placement of maxillary implants using the alveolar expansion technique with osteotomes: a study of 4 cases. *Int J Oral Maxillofac Implants* 2008;23:129-32.
31. Saker M, Ogle O. Benign paroxysmal positional vertigo subsequent to sinus lift via closed technique. *J Oral Maxillofac Surg* 2005;63:1385-7.
32. Betts NJ, Miloro M. Modification of the sinus lift procedure for septa in the maxillary antrum. *J Oral Maxillofac Surg* 1994;52:332-3.
33. Van den Bergh JP, ten Bruggenkate CM, Disch FJ, Tuinzing DB. Anatomical aspects of sinus floor elevations. *Clin Oral Implants Res* 2000;11:256-65.
34. Kim MJ, Jung UW, Kim CS, Kim KD, Choi SH, Kim CK, et al. Maxillary sinus septa: prevalence, height, location, and morphology. A reformatted computed tomography scan analysis. *J Periodontol* 2006;77:903-8.
35. Velasquez-Plata D, Hovey LR, Peach CC, Alder ME. Maxillary sinus septa: a 3-dimensional computerized tomographic scan analysis. *Int J Oral Maxillofac Implants* 2002;17:854-60.
36. Pikos MA. Maxillary sinus membrane repair: report of a technique for large perforations. *Implant Dent* 1999;8:29-34.
37. Small SA, Zinner ID, Panno FV, Shapiro HJ, Stein JI. Augmenting the maxillary sinus for implants: report of 27 patients. *Int J Oral Maxillofac Implants* 1993;8:523-8.
38. Timmenga NM, Raghoebar GM, Boering G, van Weissenbruch R. Maxillary sinus function after sinus lifts for the insertion of dental implants. *J Oral Maxillofac Surg* 1997;55:936-9.
39. Cho SC, Wallace SS, Froum SJ, Tarnow DP. Influence of anatomy on Schneiderian membrane perforations during sinus elevation surgery: three-dimensional analysis. *Pract Proced Aesthet Dent* 2001;13:160-3.
40. Tarnow DP, Wallace SS, Froum SJ, Rohrer MD, Cho SC. Histologic and clinical comparison of bilateral sinus floor elevations with and without barrier membrane placement in 12 patients: Part 3 of an ongoing prospective study. *Int J Periodontics Restorative Dent* 2000;20:117-25.