

## Case Report

# Intra-Root Cavernous Angioma of the Cauda Equina : A Case Report and Review of the Literature

Sang Woo Chun, M.D.,<sup>1</sup> Sang Jin Kim, M.D.,<sup>1</sup> Tae Hoon Lee, M.D.,<sup>1</sup> Hye Soo Koo, M.D.<sup>2</sup>

Departments of Neurosurgery,<sup>1</sup> Pathology,<sup>2</sup> Ewha Womans University School of Medicine, Seoul, Korea

Authors experienced intra-root cavernous angioma which is very rare case among cavernous angiomas of cauda equina. Our intra-root cavernous angioma was confirmed by findings from operating field and microscopic examination. We report this case with review of the literature.

**KEY WORDS :** Cavernous angioma · Cauda equina · Intra-root cavernous angioma.

## INTRODUCTION

Of the total cases of intervertebral tumors, only 6.2-7.5% correspond to vascular tumor<sup>4,5</sup>. Of them, cavernous angioma has been reported to have an incidence of 5-12%<sup>9,12</sup>. Cavernous angioma which is present in the vertebra and spinal cord is a very rare lesion. It is a well-demarcated lesion from the adjacent tissue, and is a mass of dilated blood vessels with no nervous tissue within the lesion. Most of the cases are developed from the vertebral body, and they invade the extradural tissue. In some cases, however, cavernous angioma can be developed with no involvement of vertebral body within the dura mater. These cases are very rare, approximately 3% of which are the intradural cavernous angiomas<sup>8</sup>. Most of the intradural cavernous angioma are intramedullary lesions.

According to a review of literatures, the extramedullary cavernous angioma which was surgically treated is a very rare entity. Of them, 14 cases were developed in cauda equina. Most of these cases have been reported to occur between L1 and L3<sup>11</sup>.

We experienced a symptomatic case of cavernous angioma which was present in the nerve root of cauda equina. To

our knowledge, this is a very rare case. Here, we report our case with a review of literatures.

## CASE REPORT

A 74-year-old woman who presented with pain radiating into both lower extremities 3-4 years before, with a greater severity on the left side, visited us. The pain was developed four years before and it assumed a chronic feature. It was worse at night. The patient complained of neurogenic intermittent claudication where the radiating pain started to develop in both extremities following a 500-m ambulation. She did not complain of symptoms of cauda equina syndrome including urinary symptom. At the time of admission, there was tenderness in the lumbar area on physical examination. On neurological assessment, there were no muscle weaknesses or sensory abnormalities.

On lumbar MRI scan, which was taken at admission, there was a mass of 14 × 10 mm in size compressing the spinal canal at a spinal level of L3. This mass had heterogeneous signal intensity and a non-enhanced high signal, which was surrounded by a black hemosiderin ring (Fig. 1). There was also severe central degenerative spondylotic stenosis at L4/5.

Under the general anesthesia, right L3 hemilaminectomy was performed. Using a surgical microscope, an incision was made on the dura mater, and this identified the area where the dura was swollen and stained with a dark brownish color (Fig. 2). A dark-brownish, well-defined angioma

• Received : May 29, 2009 • Revised : November 1, 2009  
• Accepted : March 22, 2010  
• Address for reprints : Sang Jin Kim, M.D.  
Department of Neurosurgery, Ewha Womans University School of  
Medicine, Mok 6-dong, Yangcheon-gu, Seoul 158-710, Korea  
Tel : +82-2-2650-2658, Fax : +82-2-2655-0948  
E-mail : sjkimmd@unitel.co.kr

was observed in the cauda equina with its nerve bundles. This mass was noted to be present in the area where the cauda equine was branched into nerve root. The nerve root was densely attached to the surface of a mass. Within the mass, there was a dark-brownish hematoma. Attempts were made to dissect the adhesion site, but in vain. The mass seemed to arise from the nerve root originating from below L4. Therefore, the adjacent area to nerve root was dissected and the nerve root was resected.

Postoperatively, the patient had symptoms disappeared promptly. The patient did not show such neurological symp-

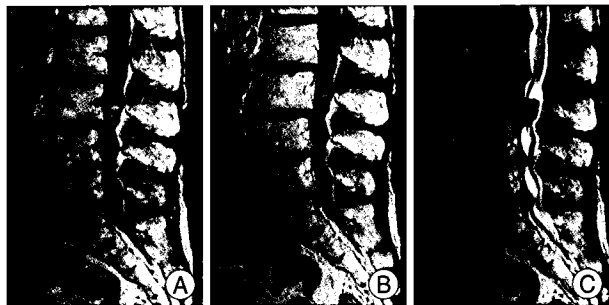


Fig. 1. A mass of 14 × 10 mm in size compressing the spinal canal at a spinal level of L3. This mass shows heterogenous signal intensity on T2 (C)-, T1 (A)-weight image and T1-weighted with contrast enhancement images (B). A non-enhanced high signal, which is surrounded by a black hemosiderin ring (A).



Fig. 2. Intraoperative image showing the 14 × 10 mm berry-like tumor. A rootlet remains adherent to the tumor disappearing inside its capsule.

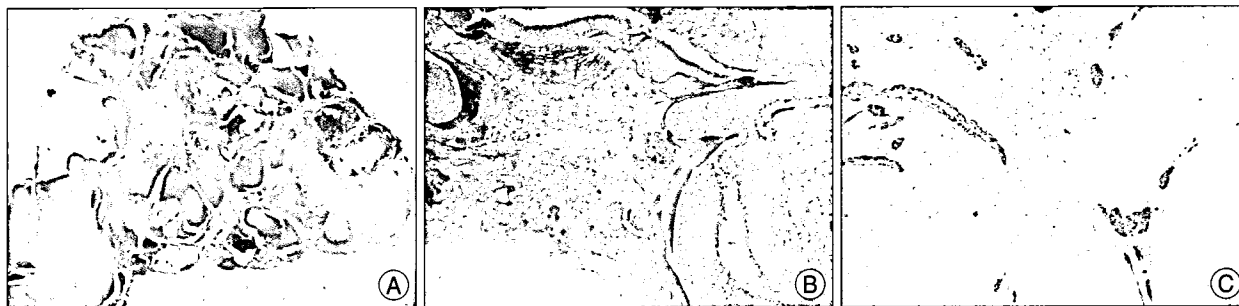

Fig. 3. Lower magnification shows variable sized dilated vascular channels with thin or hyalinized wall, which are lined by flattened endothelial cells and contained blood clots or organizing thrombi. Focal fibrotic areas are mixed with blood vessels (A). Fibrotic areas show dilated vessels and peripheral nerve fibers (B). The peripheral nerve fibers are well documented by S-100 immunostain (C).

toms as urinary symptom, muscle weakness or paresthesia.

On histopathological sectioning, the cut surface showed dark reddish hemorrhagic soft tissue and blood clot-like appearance. Gross examination of the removed specimen showed an ovoid dark brownish well demarcated mass, measuring 1.4 × 1 × 0.7 cm in size. On sectioning, the cut surface showed dark reddish hemorrhagic soft tissue and blood clot-like appearance (Fig. 3). Microscopic examination showed the mass consisting of variable sized dilated vascular channels with thin or hyalinized wall, which were lined by flattened endothelial cells and contained blood clots. Organizing thrombi and hemosiderin laden macrophages were noted. Admixed were scattered multifocal areas of fibrosis including dilated blood vessels and fragments of peripheral nerve fibers, which was well documented by Masson trichrome stain and S-100 immunostain (Fig. 3). The microscopic findings were consistent with intra-root cavernous hemangioma (Fig. 3).

## DISCUSSION

Cavernous angioma is also termed as cavernous hemangioma, cavernous malformation or cavernoma. Grossly, it has a mulberry shape and is characterized by hemosiderin deposition. Histologically, it consists of thin walled sinusoidal vascular channels. On angiography, there are rare findings such as import arteries or export veins. Cavernous angioma is mainly developed in the tentorium cerebellum or subcortical white matter. Cavernous angioma which is developed in the spine and spinal cord are very rare. It is known that cavernous angioma which occurs in the spine and spinal cord accounts for approximately 5% of total cases occurring in the central nervous system<sup>2,3,15</sup>. Most of the cases which develop in the spine are commonly found in the vertebral body. Only about 3% of these cases are found within the dura mater, most of which are intramedullary cases. Cavernous angioma which occur in cauda equina is very rare. It is considered that cavernous angioma

**Table 1.** Reported surgical cases of intra-root cavernous angiomas

	Study	Age/Sex	Levels	Presenting symptoms	Surgery extent	Outcome
1	Pagni et al. <sup>14</sup>	46/M	T12-L1	Back pain	Total	Excellent
2	Nozaki et al. <sup>13</sup>	51/M	C5-6	Sensorimotor deficit	Total	Excellent
3	Er et al. <sup>6</sup>	67/M	T11-L1	Back pain, sphincter dysfunction	Total	Excellent
4	Caroli et al. <sup>1</sup>	71/M	L4	Sciatic and back pain, sensory deficit	Total	Excellent
5	Author	74/F	Below L4	Sciatic pain	Total	Excellent

occurs in the nerve root, the interior side of dura mater and pial surface of the spinal cord within the dura mater outside of the spinal cord. The lesions which are attached to the nerve root or spinal cord can be frequently identified during the surgery. This well illustrates that cavernous angioma arises from the blood vessels which originates from the nerve root of spinal cord. Of 14 cases of cavernous angioma occurring in cauda equina, which have been reported until now, six needed a surgical dissection of the nerve root<sup>11</sup> (Table 1). Of these six cases, four developed such neurological symptoms as paresthesia or muscle weakness<sup>7,10,14</sup>. The remaining two did not develop neurological deficits even following the dissection of nerve root<sup>10,11</sup>. In our case, cavernous angioma originating from the interior side of nerve root was identified under the fine microscopic guidance during the surgery. According to a review of literatures, a total of four cases of cavernous angioma which occurred in the interior side of nerve root have been reported until now.

To intraoperatively remove cavernous angioma, the dissection of nerve root which was assumed to be the origin was unavoidable. Postoperatively, however, no neurological deficits were developed. Furthermore, it is also noteworthy that cavernous angioma which was extracted from the patient was noted to have nervous tissue in the vascular structure. As mentioned herein, the histopathological findings that the nervous tissue is mingled with vascular sinusoidal channels are very rare even among the cases of cavernous angioma in cauda equina.

Cavernous angioma which was present in the spinal cord is a very rare entity, but its incidence has recently been increasing because it can easily be identified on MRI scans. Cavernous angioma shows a variety of signal intensity due to the presence of hemosiderin and calcification on T2- and T1-weighted images. Of the 14 cases which have been reported until now, seven could be seen on MRI scans. Of these seven cases, four had a high-signal intensity, two did an iso-signal intensity and the remaining one did a low-signal intensity on T1-weighted image. These results indicate that cavernous angioma occurring in cauda equina has a broad spectrum of intensity. Besides, on contrast-enhanced MRI scans, three showed a contrast-enhancement, two had

a slight contrast-enhancement and the remaining did not.

In our case, on MRI scans of the lumbar spine on admission, there were a heterogeneous signal intensity and a non-enhanced high-signal intensity at the level of L3. The lesions were surrounded by a black hemosiderin ring.

## CONCLUSION

Cavernous angioma which occurs in cauda equina is very rare, but its incidence has been gradually increasing compared to the past with the increased frequency of MRI use in recent years. Authors experienced a rare intra-root cavernous hemangioma, arising from cauda equine recently and report with the review of literatures.

## References

- Caroli E, Acqui M, Trasimeni G, Di Stefano D, Ferrante L. A case of intraroot cauda equina cavernous angioma : clinical considerations. *Spinal cord* 45 : 318-321, 2007
- Cecchi PC, Rizzo P, Faccioli F, Bontempini L, Schwarz A, Bricolo A. Intraneural cavernous malformation of the cauda equina, *J Clin Neurosci* 14 : 984-986, 2007
- Cho YJ, Kim SB, Chin DK, Yoon YS, Cho YE, Kim YS. Surgical treatment of intramedullary spinal cord cavernous malformation. *J Korean Neurosurg Soc* 33 : 466-471, 2003
- Da Costa LB Jr, de Andrade A, Braga BP, Ribeiro CA. Cauda equina hemangioblastoma : case report. *Arq Neuropsiquiatr* 61 : 456-458, 2003
- Duke BJ, Levy AS, Lillehei KO. Cavernous angiomas of the cauda equina : case report and review of the literature. *Surg Neurol* 50 : 442-445, 1998
- Er U, Yigikanli K, Simsek S, Adabag A, Bavbek M. Spinal intradural extramedullary cavernous angioma : case report and review of the literature. *Spinal Cord* 45 : 632-636, 2007
- Falavigna A, Righesso Neto O, dos Santos JA, Ferraz FA. Cavernous angioma of the cauda equina : case report. *Arq Neuropsiquiatr* 62 : 531-534, 2004
- Harrison MJ, Eisenberg MB, Ullman JS, Oppenheim JS, Camins MB, Post KD. Symptomatic cavernous malformations affecting the spine and spinal cord. *Neurosurgery* 37 : 195-204; discussion 1995
- Hatiboglu MA, Iplikcioglu AC, Ozcan D. Epidural spinal cavernous hemangioma. *Neurol Med Chir (Tokyo)* 46 : 455-458, 2006
- Makino K, Takamura H, Gotoh S, Andoh M. [Cauda equina cavernous hemangioma associated with hydrocephalus--case report.] *No To Shinkei* 47 : 783-787, 1995
- Miyake S, Uchihashi Y, Takaishi Y, Sakagami Y, Kohmura E. Multiple cavernous angiomas of the cauda equina. Case report. *Neurol Med Chir (Tokyo)* 47 : 178-181, 2007
- Moreno Rojas AJ, Romero J, Serrano V, Madrid A, Jarrin S, Casado

- JL. [Intradural extramedullary cavernoma of cauda equina.] *Rev Neurol* 23 : 1228-1230, 1995
13. Nozaki K, Inomoto T, Takagi Y, Hashimoto N. Spinal intradural extramedullary cavernous angioma. Case report. *J Neurosurg* 99 : 316-319, 2003
14. Pagni CA, Canavero S, Forni M. Report of cavernoma of the cauda equina and review of the literature. *Surg Neurol* 33 : 124-131, 1990
15. Spetzger U, Gilsbach JM, Bertalanffy H. Cavernous angiomas of the spinal cord clinical presentation, surgical strategy, and postoperative results. *Acta Neurochir (Wien)* 134 : 200-206, 1995