

## Case Report

# Stent-Assisted Coil Embolization for the Proximal Middle Cerebral Artery Fusiform Aneurysm

Seong-Man Jeong, M.D.,<sup>1</sup> Shin-Hyuk Kang, M.D., Ph.D.,<sup>1</sup> Nam-Joon Lee, M.D., Ph.D.,<sup>2</sup> Dong-Jun Lim, M.D., Ph.D.<sup>1</sup>

Departments of Neurosurgery,<sup>1</sup> Radiology,<sup>2</sup> College of Medicine, Korea University, Seoul, Korea

Middle cerebral artery (MCA) fusiform aneurysms often have an unfavorable geometry that may limit surgical or endovascular treatment. Herein, we present a case of a fusiform aneurysm of the proximal MCA, which was successfully treated using stent-assisted coil embolization. A 42-year-old man presented with repeated headache and syncope. Five years earlier, a right MCA aneurysm had been treated by aneurismal wrapping. Magnetic resonance images (MRI) revealed a partially-thrombosed proximal MCA aneurysm at the right perisylvian region. Digital subtraction angiography (DSA) revealed a multilobulated fusiform-shaped aneurysm. The patient underwent stent-assisted coil embolization under general anesthesia and symptoms resolved postoperatively. A three-month follow-up angiography revealed no recanalization of the aneurysm and indicated tolerable blood flow through the right MCA, as compared to the preoperative angiography. We suggest that in selected patients, stent-assisted coil embolization of proximal MCA fusiform aneurysms can be an effective treatment modality.

**KEY WORDS :** Middle cerebral artery · Fusiform aneurysm · Therapeutic embolization · Stent.

## INTRODUCTION

The introduction of the Guglielmi detachable coil (GDC) in 1991 radically changed the management of intracranial aneurysms and greatly increased the use of endovascular treatment<sup>2,3</sup>. Recently, new techniques and materials have widened the range of intracranial aneurysms which are amenable to endovascular treatment. However, fusiform-shaped aneurysm still remains the most challenging to manage. In the current study, we have presented a case of a 42-year-old man with a fusiform aneurysm of the proximal middle cerebral artery (MCA), who was successfully treated using stent-assisted coil embolization. To our knowledge, this is the first case report demonstrating the use of endovascular method in the treatment of fusiform proximal MCA aneurysm.

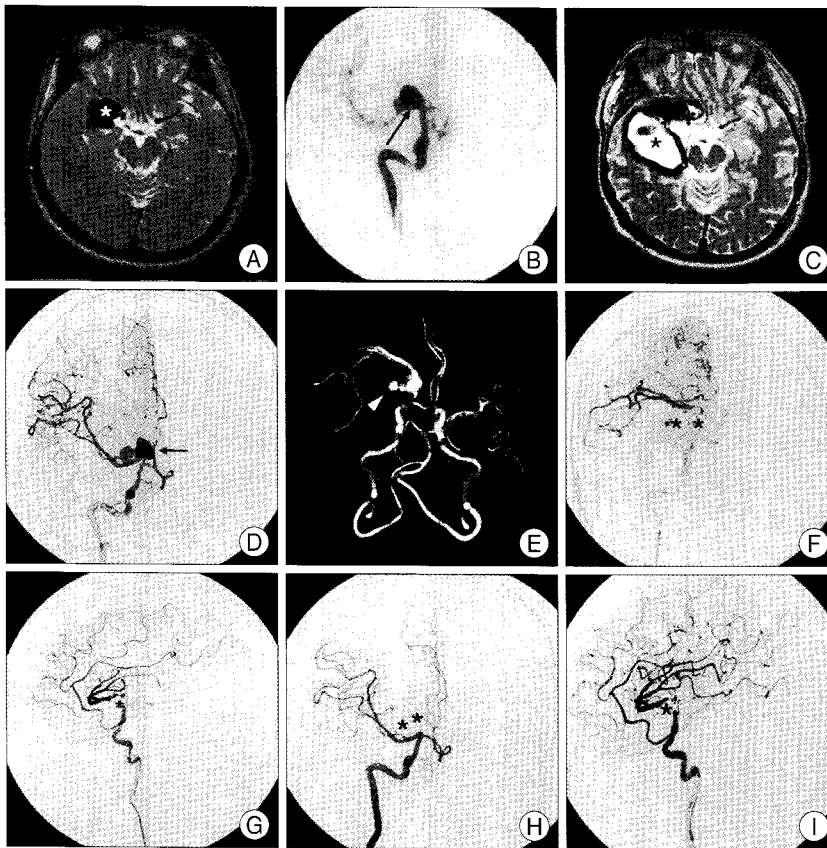
## CASE REPORT

In 2004, a 42-year-old man presented with progressive

headache that had been associated with several episodes of nausea. The patient was well cooperative and the neurologic examination didn't reveal any abnormal findings. Further, he had no family history of cerebrovascular or other systemic diseases. Magnetic resonance (MR) images showed a partially-thrombosed aneurysm at the right proximal MCA (Fig. 1A). Digital subtraction angiography (DSA) revealed a large fusiform-shaped aneurysmal dilatation (1.7 × 1.5 × 1.4 cm) extending over the M1 segment of the right MCA (Fig. 1B)<sup>7</sup>. Aneurismal neck clipping was failed due to the complex geometry of the aneurysm and therefore, at that time, he was treated only with a muscle wrapping around the aneurysm.

Five years later, he visited our department with repeated attacks of syncope and headaches. Subsequent MR imaging revealed a growing right M1 segment fusiform aneurysm which had been treated previously (Fig. 1C). DSA and brain computed tomography (CT) angiography indicated a multilobulated fusiform-shaped aneurismal dilatation accompanied by an enlargement of the temporal region at the M1 segment of the right MCA (Fig. 1D, E). Considering the persistent risk of thromboembolism and aneurysm rupture, we decided to perform an endovascular treatment because the dissection during the operation might be very difficult due to the adhesion caused by the previous operation.

• Received : March 8, 2010 • Revised : April 19, 2010  
• Accepted : May 17, 2010  
• Address for reprints : Dong-Jun Lim, M.D., Ph.D.  
Department of Neurosurgery, College of Medicine, Korea University,  
516 Gojan-dong, Danwon-gu, Ansan 425-020, Korea  
Tel : +82-31-412-5053, Fax : +82-31-412-5054  
E-mail : djlim@korea.ac.kr



**Fig. 1.** A : Axial T2-weighted magnetic resonance imaging (MRI) scans demonstrating mass like lesion, suggesting a partially-thrombosed large aneurysm which has mass effect at the perisylvian area (asterisks). B : Right internal carotid artery (ICA) angiography revealing a fusiform aneurysm in proximal middle cerebral artery (arrow). C : Axial T2-weighted MRI scan revealing an increased right proximal MCA fusiform aneurysm with hemosiderin deposit, mixed hematoma suggesting multiple hemorrhagic events (asterisk). D and E : Cerebral (D) and reconstructed CT (E) angiography demonstrating a multilobulated fusiform aneurysm of the proximal MCA region (arrow in D, arrowhead in E). F and G : Cerebral angiography showing that a stent-assisted coil has been well positioned at the right proximal MCA fusiform aneurysm (asterisks). H and I : Follow-up right ICA angiography demonstrating complete occlusion of the fusiform aneurysm (asterisks) with blood flow preservation in the distal MCA (arrowhead in H).

The patient was pretreated for 3 days with aspirin at 325 mg/day and clopidogrel at 75 mg/day. After induction of general anesthesia, a 6F Envoy guiding catheter (Cordis, USA) was advanced via the right femoral approach into the right internal carotid artery. The patient was administered intravenous heparin; an activated clotting time of 2.5 times the basal level was maintained. To protect the parent vessel during coiling without compromising blood flow, a Prowler Select Plus microcatheter (Cordis, USA) was navigated across a portion of the aneurysmal dilatation. Subsequently, an Enterprise stent (4.5 × 28 mm : Cordis, USA) was deployed easily over the dilated portion of the aneurysm. Then, the SL-10 microcatheter and Synchro 14 wire (Boston Scientific, USA) were carefully navigated to the aneurysm, passing through the struts of the stent. At first, coils were delivered to the enlarged portion of the aneurysm at the temporal region using the stent as a scaffold. Following this, the remnant portion of the fusiform aneurysm was embolized

with more coils. In total, 15 coils (279 cm of total length), including GDC (Boston Scientific, USA), MicroPlex coil (Microvention, USA), and Orbit coil (Cordis, USA), were used in the procedure. Aneurysm was completely obliterated, and there was no evidence of GDC-related thrombosis and occlusion (Fig. 1F, G). Following the procedure, the blood flow remained intact at the MCA territory and there were no procedural complications. The patient fully recovered after the procedure and was maintained on daily aspirin (100 mg) and clopidogrel (75 mg). A 3-month follow-up cerebral angiography confirmed complete thrombosis of the fusiform aneurysm with preservation of parent vessel patency (Fig. 1H, I).

## DISCUSSION

Aneurysms located on the MCA account for 18% to 22% of all intracranial aneurysms and are the third most common site of aneurysmal hemorrhage<sup>8,9</sup>. The International Subarachnoid Aneurysm Trial (ISAT) has proven the superiority of endovascular treatment for ruptured cerebral aneurysms as compared to surgical clipping<sup>13</sup>.

However, surgical clipping remains the first choice in the treatment of intracranial aneurysms, particularly in cases of unfavorable dome/neck ratios, incorporation of adjacent branches, or those involving multilobulated or distal cerebral aneurysms.

As in our case, various treatment modalities may be considered in the management of fusiform-shaped MCA aneurysms including coil embolization alone, trapping of the involved segment with EC-IC bypass, and stent-assisted coiling. Endovascular coiling alone may not be an appropriate treatment given that the coil material can protrude into the vessel lumen, resulting in occlusion of the parent vessel or adjacent perforating arteries<sup>16</sup>. With respect to surgical trapping or proximal balloon occlusion using EC-IC bypass, reoperation for residual aneurysms after previous operation may be associated with higher risks of morbidity and mortality than the initial operation<sup>6</sup>. Adhesions from the previous operation can obscure the anatomy of the

aneurysm and therefore, induce damage to tiny perforating branches during dissection, making reoperation technically more difficult. In addition, the major hurdle of the EC-IC bypass surgery may increase the risk of cerebral infarction due to temporary occlusion or graft thrombosis in the perioperative period<sup>12</sup>.

Stent-assisted coil embolization or stent alone in vertebrobasilar fusiform aneurysms has been reported as a valuable alternative not only to surgery but also to endovascular parent vessel occlusion. Stents primarily act as a coil retainer and are able to alter blood flow patterns<sup>5,11</sup>. The hemodynamic effects of stents have been thoroughly evaluated by flow models *in vivo* and it has been shown that intraluminal stents can influence intraaneurysmal flow patterns in side wall models and, to a lesser degree, in fusiform aneurysms<sup>15</sup>. In our case, a growing thrombosed aneurysm had been previously treated with muscle wrapping, so the adhesion may hinder the dissection during operation. In addition, cerebral angiography had shown no perforating branches adjacent to the fusiform aneurysm. Those findings led to the selection of stent-assisted coil embolization instead of surgical management. However, it would still be limited with regard to the perioperative risk of perforation, the potential occurrence of thromboembolic events, the failure of the delivery of the stent into the intended lesion, stenosis, and occlusion of the parent vessel<sup>4,10,14</sup>. A review of previous literature on the outcomes of stent-assisted coil embolization revealed that immediate angiography demonstrated complete occlusion in 35% of cases, neck remnant in 45%, and incomplete occlusion in 20%<sup>1</sup>. Careful evaluation of angioarchitecture using rotational 3D angiography, available on most new generation neurointerventional angiographies, or 3D helical CT angiography may be helpful for precise visualization of aneurysmal neck, shape, and size. Such findings will be useful in patient selection and further treatment planning.

## CONCLUSION

Stent-assisted coil embolization can be an effective treatment modality in cases of proximal MCA fusiform aneurysms where surgical management or coil embolization alone may not be appropriate for effective treatment. Further, patient selection and long-term follow-up is necessary to define the role of stent-assisted coil embolization in the management of proximal MCA fusiform aneurysm.

## References

1. Biondi A, Janardhan V, Katz JM, Salvaggio K, Riina HA, Gobin YP :

- Neuroform stent-assisted coil embolization of wide-neck intracranial aneurysms : strategies in stent deployment and midterm follow-up. *Neurosurgery* 61 : 460-468; discussion 468-469, 2007
2. Guglielmi G, Viñuela F, Briganti F, Duckwiler G : Carotid-cavernous fistula caused by a ruptured intracavernous aneurysm : endovascular treatment by electrothrombosis with detachable coils. *Neurosurgery* 31 : 591-596; discussion 596-597, 1992
3. Guglielmi G, Viñuela F, Dion J, Duckwiler G : Electrothrombosis of saccular aneurysms via endovascular approach. Part 2 : Preliminary clinical experience. *J Neurosurg* 75 : 8-14, 1991
4. Henkes H, Fischer S, Liebig T, Weber W, Reinartz J, Miloslavski E, et al. : Repeated endovascular coil occlusion in 350 of 2759 intracranial aneurysms : safety and effectiveness aspects. *Neurosurgery* 62 : 1532-1537, 2008
5. Higashida RT, Smith W, Gress D, Urwin R, Dowd CF, Balousek PA, et al. : Intravascular stent and endovascular coil placement for a ruptured fusiform aneurysm of the basilar artery. Case report and review of the literature. *J Neurosurg* 87 : 944-949, 1997
6. Hoh BL, Carter BS, Putman CM, Ogilvy CS : Important factors for a combined neurovascular team to consider in selecting a treatment modality for patients with previously clipped residual and recurrent intracranial aneurysms. *Neurosurgery* 52 : 732-738; discussion 738-739, 2003
7. Iwama T, Yoshimura S, Kaku Y, Sakai N : Considerations in the surgical treatment of superior-wall type aneurysm at the proximal (M1) segment of the middle cerebral artery. *Acta Neurochir (Wien)* 146 : 967-972; discussion 972, 2004
8. Kassell NF, Torner JC, Haley EC Jr, Jane JA, Adams HP, Kongable GL : The International Cooperative Study on the Timing of Aneurysm Surgery. Part 1 : Overall management results. *J Neurosurg* 73 : 18-36, 1990
9. Kassell NF, Torner JC, Jane JA, Haley EC Jr, Adams HP : The International Cooperative Study on the Timing of Aneurysm Surgery. Part 2 : Surgical results. *J Neurosurg* 73 : 37-47, 1990
10. Lee TH, Choi CH, Park KP, Sung SM, Lee SW, Lee BH, et al. : Techniques for intracranial stent navigation in patients with tortuous vessels. *AJNR Am J Neuroradiol* 26 : 1375-1380, 2005
11. Lylyk P, Cohen JE, Ceratto R, Ferrario A, Miranda C : Endovascular reconstruction of intracranial arteries by stent placement and combined techniques. *J Neurosurg* 97 : 1306-1313, 2002
12. Mohit AA, Sekhar LN, Natarajan SK, Britz GW, Ghodke B : High-flow bypass grafts in the management of complex intracranial aneurysms. *Neurosurgery* 60 : ONS105-ONS122; discussion ONS122-ONS103, 2007
13. Molyneux A, Kerr R, Stratton I, Sandercock P, Clarke M, Shrimpton J, et al. : International Subarachnoid Aneurysm Trial (ISAT) of neurosurgical clipping versus endovascular coiling in 2143 patients with ruptured intracranial aneurysms : a randomised trial. *Lancet* 360 : 1267-1274, 2002
14. Molyneux AJ, Kerr RS, Yu LM, Clarke M, Sneade M, Yarnold JA, et al. : International subarachnoid aneurysm trial (ISAT) of neurosurgical clipping versus endovascular coiling in 2143 patients with ruptured intracranial aneurysms : a randomised comparison of effects on survival, dependency, seizures, rebleeding, subgroups, and aneurysm occlusion. *Lancet* 366 : 809-817, 2005
15. Wakhloo AK, Tio FO, Lieber BB, Schellhammer F, Graf M, Hopkins LN : Self-expanding nitinol stents in canine vertebral arteries : hemodynamics and tissue response. *AJNR Am J Neuroradiol* 16 : 1043-1051, 1995
16. Wells-Roth D, Biondi A, Janardhan V, Chapple K, Gobin YP, Riina HA : Endovascular procedures for treating wide-necked aneurysms. *Neurosurg Focus* 18 : E7, 2005