

Case Report

Idiopathic Hypereosinophilic Syndrome Involving Thoracic Spine

Chi Young Park, M.D.,¹ Seok Won Kim, M.D.²

Departments of Internal,¹ Neurosurgery,² College of Medicine, Chosun University, Gwangju, Korea

Hypereosinophilic syndrome is a rare hematologic disorder with sustained eosinophilia. Peripheral blood eosinophilia without an underlying etiology and with organs dysfunction has been designated hypereosinophilic syndrome. We report a rare case of symptomatic spinal infiltration of eosinophils at osteolytic T5 in patient with idiopathic hypereosinophilic syndrome.

KEY WORDS : Hypereosinophilic syndrome · Idiopathic · Spinal infiltration.

INTRODUCTION

Significant eosinophilia and even eosinophilic tissue infiltration has been associated with a variety of clinical disorders including allergic and immunodeficiency states, drug reaction, infection, parasitic infestation or malignancy¹⁾. Hypereosinophilic syndrome (HES) was first introduced in 1968 by Hardy and Anderson⁷⁾ and it has since been characterized by presence of persistently elevated eosinophilia ($\geq 1.5 \times 10^9/L$) in the peripheral blood, with evidence of damage to the organs involved and a lack of known causes. Virtually, any organ system may be involved, most frequently the heart, the central and peripheral nervous system, the lungs and the skin. There were also reports of patients with the histologic features of what was formerly called chronic active hepatitis and associated peripheral blood eosinophilia¹²⁾. We report a rare case of HES involving thoracic spine. As far as our knowledge, this is the first report of spinal involvement in patient with hypereosinophilic syndrome.

CASE REPORT

A 39-year-old man was transferred to our department

owing to 3 months history of migrating thoracic back pain. Twelve months before his current presentation, he was hospitalized with abdominal pain and was found to have high levels of eosinophils in the peripheral blood. At that time, the eosinophilic count was measured for the first time, showing $3.8 \times 10^9/L$ with a total white cell count of $108.1 \times 10^9/L$ (35% eosinophilic cells). The erythrocyte sedimentation rate (ESR) had raised to 44 mm/h, but C-reactive protein (CRP) was within normal limits. Serum aspartate aminotransferase and alanine aminotransferase was 17 and 18 U/L respectively. Bilirubin and prothrombin time were normal. Test results for hepatitis B surface antigen and anti-hepatitis C virus were normal, as was the platelet count and serum electrolytes. The AMA antimitochondrial antibody titer remained elevation at a 1 : 320 titer, whereas test results for other autoantibodies (antinuclear antibodies, smooth muscle antibodies, and antineutrophil cytoplasmic antibody) were negative. Test results were negative for fecal parasites. There was no history of allergy or heart disease. A physical examination revealed hepatomegaly, but not splenomegaly, and there was no ascites, jaundice, telangiectasias, or palmar erythema. Chest X-ray and electrocardiogram showed normal findings without cardiac involvement. However, an abdominal ultrasound displayed hepatomegaly with an inhomogeneous structure. A liver needle core biopsy was performed and showed a region of confluent necrosis that accounted for 40% of the liver tissue sampled. An eosinophilic infiltration was associated with the necrotic tissue. For this result, he was diagnosed of idiopathic HES and

• Received : September 24, 2009 • Revised : November 2, 2009
• Accepted : May 3, 2010
• Address for reprints : Seok Won Kim, M.D.
Department of Neurosurgery, College of Medicine, Chosun University,
588 Seoseok-dong, Dong-gu, Gwangju 501-717, Korea
Tel : +82-62-220-3127, 3126, Fax : +82-62-227-4575
E-mail : chosunns@chosun.ac.kr

20.0 mg of oral steroid (prednisolone) had been taken for 12 months. For his migrating thoracic pain lasting for about 3 months, he was transferred to neurosurgical department. Despite the continuous steroid therapy, his eosinophil count was still high and rose to $4.5 \times 10^9/L$ by the time of referral. Neurological exam showed normal sensory distribution and normal muscular strength. Neurological deficits were not detected. Radiological studies including technetium bone scan, computed tomographic (CT) scan and magnetic resonance imaging (MRI) of thoracic spine were performed. Technetium bone scan demonstrated a higher uptake at

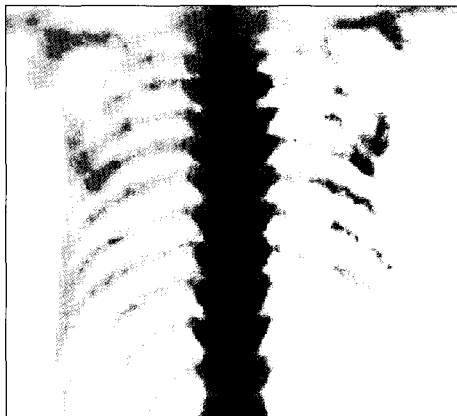


Fig. 1. Bone scan shows high uptake at T5 level.

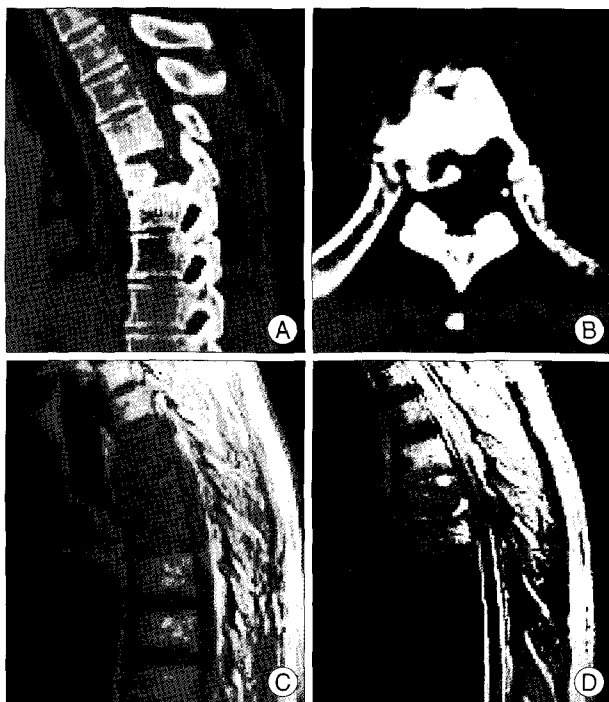


Fig. 2. Radiological studies reveal significant abnormality at T5 level. A and B : Computed tomographic scans show high density at T4, T5 and T6 level and osteolytic lesion at T5 level. C and D : Sagittal magnetic resonance images reveal hypointense T1-weighted image and hyperintense T2-weighted image at T4, T5 and T6 body with the compression of the subarachnoid space.

the fifth thoracic vertebra (Fig. 1). CT scan showed high density at T4, T5 and T6 with mild compression at T5. In addition, osteolytic lesion was observed at T5 level (Fig. 2A, B). Lumbar MRI revealed hypointense T1-weighted images and hyperintense T2-weighted images at T4, T5 and T6 body with the compression of the subarachnoid space (Fig. 2C, D). With the diagnosis of a metastasizing process of unknown origin or infectious condition, we performed transpedicular biopsy. The bone marrow specimen was obtained for bacteriological and pathological examination. The bone marrow specimen showed massive collection of eosinophils with ischemic coagulative necrosis (Fig. 3). But, evidence of pyogenic spondylitis, tuberculous spondylitis or malignancy were not detected. Without any additional treatment, he had gradual improvement of thoracic back pain with continuous oral steroid intake. Six months later transpedicular biopsy, the prednisolone dose was tapered down to 10.0 mg, but, the eosinophil count persisted on the upper limit of normal.

DISCUSSION

The criteria for idiopathic HES are persistent eosinophilia of more than 1.5×10^9 eosinophils/L for at least 6 months, lack of evidence for parasitic, allergic, or other recognized causes of eosinophilia despite careful evaluation, and organ system dysfunction^{3,4,13}. Idiopathic hypereosinophilic syndrome is more common in men and accounts for 85% of the patients with this condition and tends to occur between the ages of 20-80 years. Any organ system may be involved, most frequently the heart, the central and peripheral nervous system, the lungs and the skin. Liver involvement among various organs is reported to be relatively common, 32% of

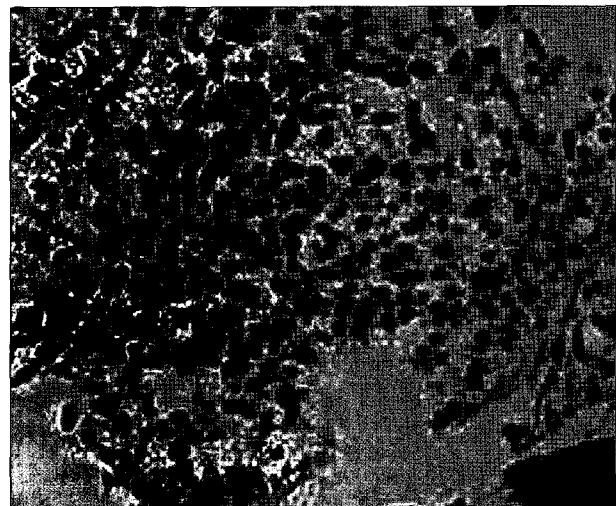


Fig. 3. The bone marrow specimen shows collection of eosinophils with ischemic coagulative necrosis (H&E stain $\times 200$).

the patients showing hepatomegaly and minor abnormalities of liver function tests. The spectrum of pathologic findings included congested sinusoids, chronic hepatitis without cirrhosis, and periportal inflammation. Activated eosinophils have been associated with cell damage in skin, heart and jejunum^{3,6,9,11}. Cytotoxic effects of the so-called major basic protein and other eosinophilic granule proteins have also been described^{5,8}. The spinal infiltration of eosinophils such as present case in HES not been reported so far. It was difficult to diagnose initially in this case. Therefore, we performed transpedicular biopsy to rule out spondylitis and malignancy. Since the clinical course of the disease is thought to be usually benign, a simple, minimally invasive form of treatment with a low rate of complications is desirable. In view of the possibility of spontaneous resolution, biopsy alone to confirm the diagnosis was our strategy.

The treatment of HES differs from one patient to the other. Because HES patients are not uniform, therapies based on current knowledge must be individualized with the goal of controlling virtual organ damage. Patients who lack heart failure and those who respond well to prednisone or similar drug are known to have a good prognosis^{10,11}. Usually, patients need permanent low dose therapy with corticosteroids. Patients with HES have traditionally been treated with prednisone, and this is still the first-line drug of choice. The initial dose of 1 mg/kg daily rapidly achieves excellent clinical and laboratory results in some instances: the symptoms wane and eosinophil count declines to normal values. Corticosteroids have profound effects on eosinophil generation, function and survival. However, overtime, the toxicities of steroid therapy may limit the further treatment. Although 70% of patients are responders, a considerable number may experience relapse while on corticosteroids. Second-line drugs, interferon- α (IFN- α) or hydroxyurea induce remission in the majority of patients^{2,10,12}. Surgical therapy is rarely utilized. External brace and bed

rest may be applied in case of presentation of pain involving spine.

CONCLUSION

We report a rare case of symptomatic spinal infiltration of eosinophils in patient with hypereosinophilic syndrome. Careful examination and continuous steroid therapy may bring the good result to this uncommon condition.

References

1. Bunc M, Remskar Z, Brucan A : The idiopathic hypereosinophilic syndrome. *Eur J Emerg Med* 8 : 325-330, 2001
2. Butterfield JH : Interferon treatment for hypereosinophilic syndromes and systemic mastocytosis. *Acta Haematol* 114 : 26-40, 2005
3. Chusid MJ, Dale DC, West BC, Wolff SM : The hypereosinophilic syndrome : analysis of fourteen cases with review of the literature. *Medicine (Baltimore)* 54 : 1-27, 1975
4. Fauci AS, Harley JB, Roberts WC, Ferrans VJ, Gralnick HR, Bjornson BH : NIH conference. The idiopathic hypereosinophilic syndrome. Clinical, pathophysiologic, and therapeutic considerations. *Ann Intern Med* 97 : 78-92, 1982
5. Gleich GJ, Adolphson CR : The eosinophilic leukocyte : structure and function. *Adv Immunol* 39 : 177-253, 1986
6. Gleich GJ, Schroeter AL, Marcoux JP, Sachs MI, O'Connell EJ, Kohler PF : Episodic angioedema associated with eosinophilia. *N Engl J Med* 310 : 1621-1626, 1984
7. Hardy WR, Anderson RE : The hypereosinophilic syndromes. *Ann Intern Med* 68 : 1220-1229, 1968
8. Jörg A, Henderson WR, Murphy RC, Klebanoff SJ : Leukotriene generation by eosinophils. *J Exp Med* 155 : 390-402, 1982
9. Keshavarzian A, Saverymuttu SH, Tai PC, Thompson M, Barter S, Spry CJ, et al. : Activated eosinophils in familial eosinophilic gastroenteritis. *Gastroenterology* 88 : 1041-1049, 1985
10. Schleimer RP, Bochner BS : The effects of glucocorticoids on human eosinophils. *J Allergy Clin Immunol* 94 : 1202-1213, 1994
11. Tai PC, Ackerman SJ, Spry CJ, Dunnette S, Olsen EG, Gleich GJ : Deposits of eosinophil granule proteins in cardiac tissues of patients with eosinophilic endomyocardial disease. *Lancet* 1 : 643-647, 1987
12. Ung KA, Remotti H, Olsson R : Eosinophilic hepatic necrosis in hypereosinophilic syndrome. *J Clin Gastroenterol* 31 : 323-327, 2000
13. Weller PF, Bubley GJ : The idiopathic hypereosinophilic syndrome. *Blood* 83 : 2759-2779, 1994