

Case Report

Delayed Progressive Extradural Pneumatocele due to Incomplete Sealing of Opened Mastoid Air Cell after Micro-Vascular Decompression

Ki-Sun Hong, M.D., Kwan Park, M.D.

Department of Neurosurgery, Samsung Medical Center, Sungkyunkwan University School of Medicine, Seoul, Korea

A case of delayed progressive extradural pneumatocele after microvascular decompression (MVD) is presented. A 60-year-old male underwent MVD for hemifacial spasm; the mastoid air cell was opened and sealed with bone wax during surgery. One month after surgery, the patient complained of tinnitus, and progressive extradural pneumatoceles without cerebrospinal fluid (CSF) leakage was observed. Revision surgery was performed and the opened mastoid air cell was completely sealed with muscle patch and glue. The patient's symptoms were resolved, with no recurrence of pneumatoceles at 6 month follow up. Progressive extradural pneumatocele without CSF leakage after posterior fossa surgery is a very rare complication. Previous reports and surgical management of this rare complication are discussed.

KEY WORDS : Pneumatocele · Posterior fossa surgery · Hemifacial spasm · Mastoid air cell.

INTRODUCTION

Extradural pneumatoceles are subperiosteal collections of air, usually posttraumatic or infectious, and, on rare occasions, spontaneous^{3,8)}. Pneumatocele following a neurosurgical procedure is extremely rare, and most reported cases are associated with cerebrospinal fluid (CSF) leakage^{10,12)}. Here, we report on a rare case of extradural pneumatocele without CSF leakage that occurred after retrosigmoid suboccipital craniectomy for microvascular decompression (MVD).

CASE REPORT

A 60-year-old male who had undergone MVD two months previously revisited the outpatient department with very distressing tinnitus. MVD was performed via a retrosigmoid suboccipital approach, and partial mastoidectomy

was performed to expose the lateral margin of the sigmoid sinus. During mastoidectomy mastoid air cells were opened to a size of approximately 1 × 1.5 cm, and the defect was sealed with bone wax. Dural closure was performed using a "plugging muscle" method described in our previous reports⁹⁾. Cranioplasty was performed with polymethylmethacrylate (PMMA). One month after surgery, the patient felt tinnitus that presented with the appearance of flowing water. The tinnitus was aggravated when he lay down or turned his head to the left.

Otologic examination revealed nothing remarkable. The tympanic membrane was clear with no fluid collection, and pure-tone audiogram showed high frequency deafness that had been evaluated preoperatively.

Computed tomography (CT) (Fig. 1) revealed an epidural pneumatocele in the left posterior fossa communicating freely with the air cell system of the left mastoid cavity without fluid collection, and bone wax was pushed into the mastoid air cell. A brain CT performed two months later revealed increased epidural pneumatocele and extended subgaleal air collection (Fig. 2), and the patient's symptoms were aggravated.

Following discussion with the patient, surgical intervention was performed under general anesthesia. Adhesion

• Received : September 9, 2009 • Revised : December 16, 2009
• Accepted : May 17, 2010
• Address for reprints : Kwan Park, M.D.
Department of Neurosurgery, Samsung Medical Center,
Sungkyunkwan University School of Medicine, 50 Irwon-dong,
Gangnam-gu, Seoul 135-710, Korea
Tel : +82-2-3410-3496, Fax : +82-2-3410-0048
E-mail : kwanpark@skku.edu

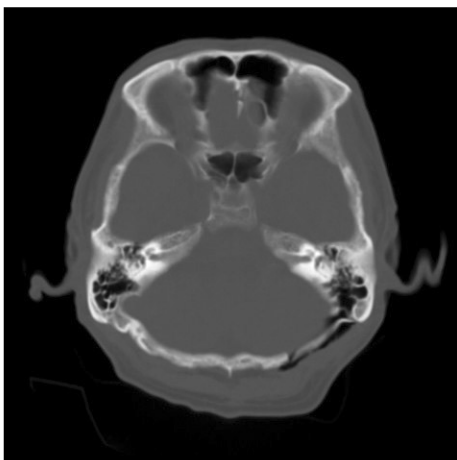


Fig. 1. Axial computed tomography scan performed at 2 months after surgery shows the epidural pneumatocele and subgaleal air collection in the left posterior fossa communicating freely with the air cell system of the mastoid cavity, without fluid collection. Bone wax is pushed into the mastoid air cell.

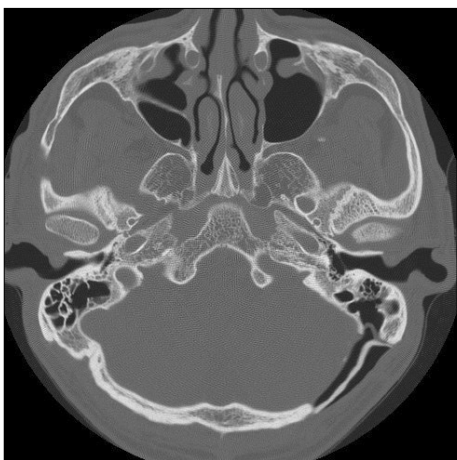


Fig. 2. Axial computed tomography scan performed at 4 months after surgery shows increased pneumatocele and subgaleal air collection.

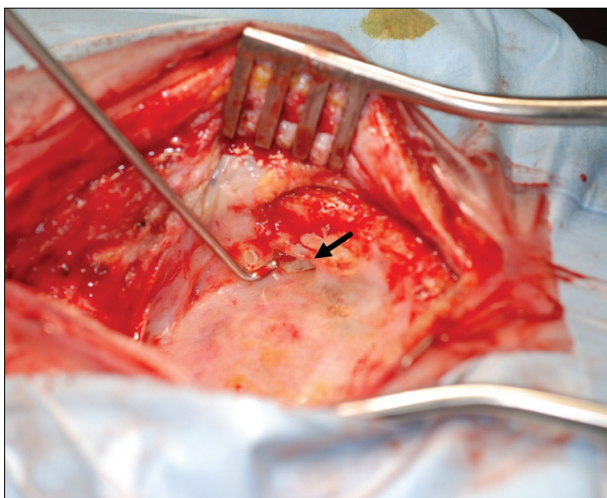


Fig. 3. Intraoperative photography reveals the connection between the epidural space and mastoid air cells (arrow).

between the artificial bone flap and dura was absent, and the bone flap was easily removed. Culture was performed following bone flap removal. A large connection between the epidural space and the mastoid air cell was observed; however, the dura was completely healed without defect (Fig. 3). Pieces of superficial muscle were harvested and packed into the defect. Using glue, muscles were fixed and reinforced. Cranioplasty was performed with PMMA and fixed with a screw and plate system. Following surgery, the tinnitus ceased completely and the pneumatocele disappeared. Culture results were negative. Six months after surgery, the patient was symptom free.

DISCUSSION

Small extradural air collections are often demonstrated after craniotomy, but usually undergo spontaneous absorption with time. However, chronic progressive extradural air collection, that is, pneumatocele following a neurosurgical procedure is extremely rare, and most reported cases are associated with cerebrospinal fluid (CSF) leakage^{10,12}. Only two cases of extradural pneumatocele without CSF leakage following posterior fossa surgery have been reported. One case developed after surgery for posterior fossa meningioma, and the other case occurred after MVD for trigeminal neuralgia. Tinnitus, opened mastoid air cells, and absence of CSF leakage were common symptoms, as in our case^{5,13}.

In our previous report on MVD, among 678 cases, 146 (21.5%) were associated with opened mastoid air cells⁹. Although opened mastoid air cells are common in retrosigmoid suboccipital craniectomy, and incomplete sealing may be common, a pneumatocele is extremely rare. Because watertight dural closure is not always possible during posterior fossa surgery, an incompletely sealed mastoid air cell will be presented by CSF rhinorrhea rather than a pneumatocele.

CSF leakage is one of the most common complications following MVD. According to previous studies, incidence of CSF leakage following MVD has been reported in the range of 0.9-12% of patients undergoing this procedure, and opened air-filled cavities within the cranial bone, such as mastoid air cells, are well-known risk factors for CSF leakage^{2,6,11}. In the case we presented, CSF rhinorrhea would have developed if dural closure had been not watertight. Our previously reported method of watertight dural closure using pieces of muscle in a “plugging” fashion is an effective technique for prevention of CSF leakage after MVD; only 2 (0.29%) of 678 patients had CSF leakage⁹.

Although dural closure was complete, sealing of opened mastoid air cells was not. We have used bone wax for clos-

ure of air cells. However, due to the potential risk of granuloma and chronic otitis, we usually plastered rather than packed with bone wax. In the present case, a thin wall of bone wax was pushed into the air cell cavity, and the air cell was opened. Obliteration of any remaining air cell tracts within the mastoidectomy defect with bone wax, fat, or a muscle patch to help prevent communication of the CSF with the middle ear space has been recommended⁴. Small defects may be obliterated with bone wax alone, but larger defects with a huge cavity, as in our present case, should be packed with a muscle patch or fat graft before bone waxing.

There have been several reports of spontaneous pneumatocele and pneumocephalus associated with mastoid hyperpneumatization or defect in the temporal bone, allowing a communication of air from the mastoid cells to the intracranial compartment^{1,7}. In some reported cases of spontaneous pneumocephalus, a distinct event causing pressure changes in the middle ear, such as the Valsalva maneuver or nose blowing, were described⁷. In the case we presented, the role of pressure changes in the middle ear was not clear. However, in cases of opened mastoid air cells during surgery, instructing patients not to do the Valsalva maneuver or to blow their nose may be important for avoidance of this unique surgical complication, in addition to ensuring correct closing of the mastoid air cells.

CONCLUSION

Complete sealing of the mastoid air cell is an important surgical step in retrosigmoid suboccipital craniectomy for prevention of both CSF rhinorrhea and pneumatocele. In cases of larger air cell openings, muscle or fat packing with bone wax will prevent incomplete sealing of mastoid air cells.

References

1. Añorbe E, Aisa P, Saenz de Ormijana J : Spontaneous pneumatocele and pneumocephalus associated with mastoid hyperpneumatization. *Eur J Radiol* 36 : 158-160, 2000
2. Broggi G, Ferroli P, Franzini A, Servello D, Dones I : Microvascular decompression for trigeminal neuralgia : comments on a series of 250 cases, including 10 patients with multiple sclerosis. *J Neurol Neurosurg Psychiatry* 68 : 59-64, 2000
3. Dowd GC, Molony TB, Voorhies RM : Spontaneous otogenic pneumocephalus. Case report and review of the literature. *J Neurosurg* 89 : 1036-1039, 1998
4. Fishman AJ, Marrinan MS, Golfinos JG, Cohen NL, Roland JT Jr : Prevention and management of cerebrospinal fluid leak following vestibular schwannoma surgery. *Laryngoscope* 114 : 501-505, 2004
5. Hah W, Russell A, Toe C, Hanna E, Farris P : Extradural pneumatocele : an unusual cause of pulsatile tinnitus. *Skull Base Surg* 7 : 43-44, 1997
6. Kalkanis SN, Eskandar EN, Carter BS, Barker FG 2nd : Microvascular decompression surgery in the United States, 1996 to 2000 : mortality rates, morbidity rates, and the effects of hospital and surgeon volumes. *Neurosurgery* 52 : 1251-1261; discussion 1261-1262, 2003
7. Kraysenbühl N, Alkadhi H, Jung HH, Yonekawa Y : Spontaneous otogenic intracerebral pneumocephalus : case report and review of the literature. *Eur Arch Otorhinolaryngol* 262 : 135-138, 2005
8. Levenson MJ, Ahuja G, Bergeron T : Spontaneous extracranial pneumatocele associated with mastoid hyperpneumatization. *Arch Otolaryngol Head Neck Surg* 115 : 107-108, 1989
9. Park JS, Kong DS, Lee JA, Park K : Intraoperative management to prevent cerebrospinal fluid leakage after microvascular decompression : dural closure with a "plugging muscle" method. *Neurosurg Rev* 30 : 139-142; discussion 142, 2007
10. Roberts GA, Foy PM, Bolger C : Idiopathic spontaneous cerebrospinal fluid rhinorrhoea and pneumocephalus : case report and literature review. *Br J Neurosurg* 10 : 513-517, 1996
11. Samii M, Günther T, Iaconetta G, Muehling M, Vorkapic P, Samii A : Microvascular decompression to treat hemifacial spasm : long-term results for a consecutive series of 143 patients. *Neurosurgery* 50 : 712-718; discussion 718-719, 2002
12. Walker FO, Vern BA : The mechanism of pneumocephalus formation in patients with CSF fistulas. *J Neurol Neurosurg Psychiatry* 49 : 203-205, 1986
13. Xenellis J, Nikolopoulos TP, Felekis D, Tzangaroulakis A : Pulsatile tinnitus : a review of the literature and an unusual case of iatrogenic pneumocephalus causing pulsatile tinnitus. *Otol Neurotol* 26 : 1149-1151, 2005